

# Localized Cutaneous Argyria From an Acupuncture Needle Clinically Concerning for Metastatic Melanoma

Elise M.J. Rackoff, MD; Keith M. Benbenisty, MD; John C. Maize, MD; John C. Maize, Jr, MD

*Localized cutaneous argyria presenting as an asymptomatic blue-gray macule has been rarely reported from diverse etiologies including occupational exposures, topical medications, alternative medical therapies, body jewelry, and dental procedures (amalgam tattoos). The lesions often are clinically indistinguishable from blue nevi and malignant melanoma. We present a case of localized cutaneous argyria from an acupuncture needle in a patient with a history of malignant melanoma. Fine granules of nonbleachable dark particles coating collagen and elastin fibers, altered yellow-brown collagen bundles similar to ochronosis, and involvement of eccrine structures were histologically consistent with the pseudo-ochronosis pattern of localized cutaneous argyria, demonstrating that clinicopathologic correlation is of crucial importance.*

*Cutis.* 2007;80:423-426.

## Case Report

A 61-year-old white woman presented to our clinic for a full-body skin examination and evaluation of a new dark lesion on her right anterior proximal thigh. Her past medical history was remarkable for an invasive malignant melanoma (Clark level II; Breslow thickness, 0.3 mm; nonulcerated) on the right upper chest that had been diagnosed and treated 10 months prior to this visit. The patient stated

the new dark lesion had developed approximately 2 months prior and was completely asymptomatic. A biopsy had been performed on a similar dark lesion on her right upper back—temporally coinciding with the biopsy of her malignant melanoma—and diagnosed at that time as a traumatic tattoo. Her only other medical issue was a chronic neurologic condition of unknown etiology whereby intermittent painful paroxysms affected the right side of her body. For this problem, she had received frequent acupuncture and taken cyclobenzaprine as needed.

Physical examination revealed a well-healed surgical scar on the patient's right upper chest, with no signs of local or in-transit melanoma recurrence. On her right anterior thigh, a 2-mm, oval, faint blue-gray macule with uniform borders was noted. Dermoscopic evaluation failed to reveal a distinct pigment network, but results of a punch biopsy revealed a narrow vertical scar extending from the papillary dermis down into the deeper dermis, with notable pigmentation. Within the reticular dermis, numerous collections of finely granular brown-black pigment appeared to coat elastic and collagen fibers (Figure, A). Altered, thickened, yellow-brown collagen fibers were dispersed throughout this zone of pigment deposition. Similar pigment granules were seen within the walls of the eccrine sweat glands (Figure, B) and small blood vessels in the subcutaneous fat (Figure, C). Sections stained with the Fontana-Masson silver method and the Gomori iron stain highlighted the granular pigment due to paler staining of surrounding tissue, not accentuation of melanin or iron. No melanocytic proliferation was identified. Sections treated with melanin pigment bleach failed to demonstrate a decreased pigment density, and polaroscopy failed to show birefringent particles. The presence of fine granules of nonbleachable dark particles coating collagen and elastin fibers, altered yellow-brown collagen bundles similar to

---

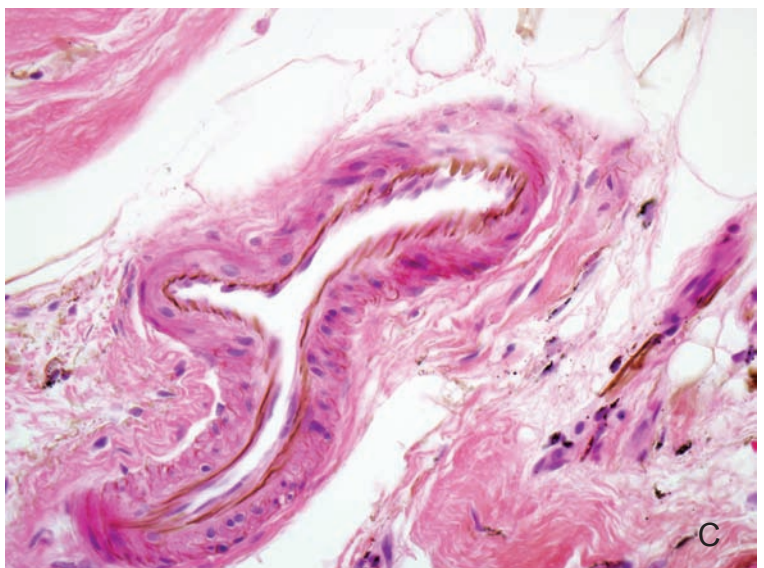
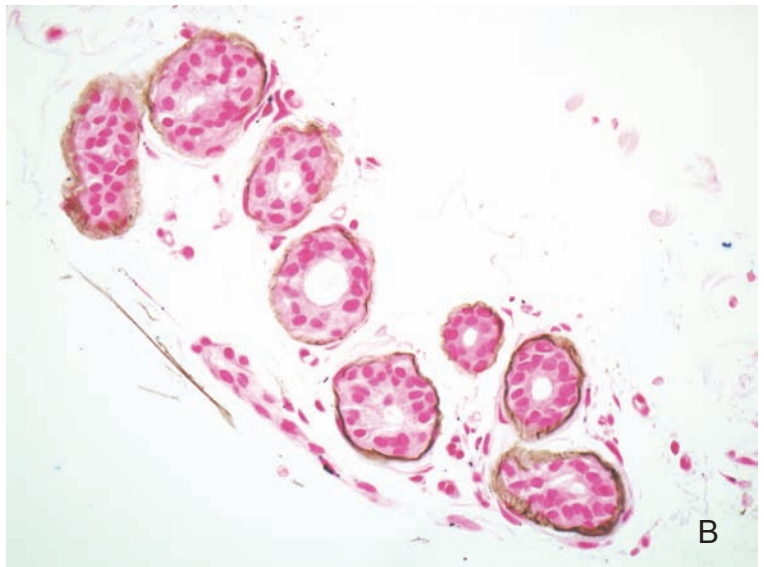
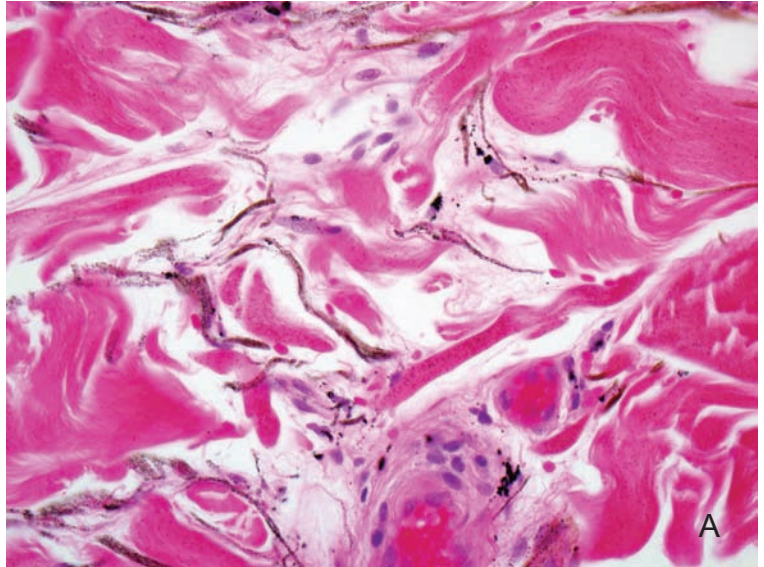
Accepted for publication March 2, 2007.

From the Department of Dermatology, Medical University of South Carolina, Charleston. Dr. J.C. Maize, Jr, also is from the Maize Center for Dermatopathology, Mt. Pleasant, South Carolina.

The authors report no conflict of interest.

Reprints: John C. Maize, Jr, MD, Maize Center for Dermatopathology, 266 W Coleman Blvd, Suite 101, Mt. Pleasant, SC 29464 (e-mail: jmaizejr@ameripath.com).

## Localized Cutaneous Argyria



Brown-black pigment granules coating elastic and collagen fibers within the deep reticular dermis (H&E, original magnification  $\times 400$ )(A). Bandlike deposition of fine granular pigment in eccrine sweat glands (H&E, original magnification  $\times 400$ )(B). Pigment accumulation within the walls of eccrine sweat glands and coating the internal elastic laminae of small blood vessels in the subcutaneous fat (Gomori iron, original magnification  $\times 400$ )(C).

ochronosis, and involvement of eccrine structures was consistent with the pseudo-ochronosis pattern of localized cutaneous argyria.

### Comment

Localized cutaneous argyria is an uncommon condition occurring less frequently than the generalized form.<sup>1</sup> However, the condition is being recognized with increasing regularity from a multitude of causes including occupational exposures,<sup>1-3</sup> topical treatment formulations,<sup>4,6</sup> alternative medical therapies such as acupuncture,<sup>7-10</sup> increased cultural popularity of body jewelry,<sup>11-13</sup> and amalgam metals used for dental procedures.<sup>14,15</sup>

Localized cutaneous argyria usually presents as one to many blue-gray pigmented macules resulting from the impregnation of the skin by silver or other heavy metals,<sup>2</sup> which is secondary to 1 of 2 pathogenic mechanisms. The first mechanism is the percutaneous absorption of metal salts through local sweat gland pores and impregnation of the surrounding skin by small silver or other metal particles from occupational exposure or topical treatment. Secondly, accidental or intentional traumatic insertion of metallic objects in the skin can result in release of metal salts into the surrounding tissues, inducing a tattooing effect (such as following acupuncture or dental procedures).<sup>1</sup> Localized cutaneous argyria secondary to jewelry may result from either mechanism.<sup>11-13</sup>

A patient may seek medical attention regarding localized cutaneous argyria for a variety of reasons, including concern for a malignant process or desire for removal of the lesion for cosmetic purposes. These macules often have been said to resemble blue nevi, and in cases where only one lesion is evident, the diagnosis often cannot be made clinically. However, as in our patient's presentation, a single lesion may be concerning for a primary or metastatic malignant melanoma. Therefore, clinicopathologic correlation is essential in making the correct diagnosis.

Histologic features of localized cutaneous argyria have been reported to resemble ochronosis, coined "pseudo-ochronosis" by Robinson-Bostom et al.<sup>16</sup> Our case exhibited the key features and histologic pattern of argyria, either localized or general. Deposition of silver (or other metal) granules classically takes place in the basement membrane of eccrine sweat glands, within the walls of dermal and subcutaneous blood vessels and around elastic fibers, as observed in our patient. Our case also demonstrated pigment granules deposited along collagen bundles, a feature less common to local argyria but well-described in pseudo-ochronosis. Additional features that may be seen in argyria but were not exhibited in our case include deposition of silver granules

around arrector pili muscles and sebaceous glands, in perineural tissue, and as opaque spheroid black globules within a zone of collagen necrosis.<sup>1-2,7,16</sup> Similar black globules also have been described following the traumatic implantation of mercury.<sup>17</sup> With dark-field microscopy, the pigment particles are brightly refractive against a dark background, so-called stars in the heavens.<sup>16</sup> Other methods available to identify tissue deposits include mass spectrophotometry and energy-dispersive x-ray analysis as reported in the Robinson-Bostom et al<sup>16</sup> case series, and electron probe microanalysis used for silicone identification within reconstruction scars of women with breast implants.<sup>18</sup> An additional method is tissue incubation with a solution of 1% potassium ferricyanide in 20% sodium thiosulfate to demonstrate silver decolorization.<sup>17</sup>

Acupuncture has been an integral part of Eastern medical cultures for centuries and is used to treat numerous diseases and clinical symptoms. There are different techniques for performing acupuncture. One acupuncture technique, called embedding of needles, is a traditional Japanese method originating from Chinese medicine whereby thin needles (called *hari*) of silver or gold are inserted into the skin and the exposed portion is then cut off for patient safety.<sup>9</sup> This process has been reported to result in localized cutaneous argyria.<sup>7-9</sup> An additional 19 cases of localized cutaneous argyria have been reported from 1983-2003 in Japan where this practice of embedding needles is more common; these cases were noted to occur at an average time of 10 years after treatment.<sup>19</sup> Western techniques use surgical stainless steel needles with silver, plastic, copper, or stainless steel handles. The needles are embedded for treatment and then removed. Legat et al<sup>10</sup> were the first to report a case of localized cutaneous argyria following short-contact acupuncture (without needle embedment).

A discussion with our patient's acupuncturist revealed that his treatment technique follows a more Western tradition whereby surgical stainless steel needles with silver handles are placed in the skin and then removed. Our patient's acupuncturist did not keep a record of which needles were used and at which anatomic sites they were placed during treatment, but the patient recalls some treatments were given to the regions in which her lesions appeared. We postulated that the needles, which are distributed in boxes of 100, were coated with fine particles of silver from the handles of neighboring needles during transportation and storage. These fine particles were then introduced into the patient's skin during needle insertion. A variety of acupuncture needles are available to practitioners,

including stainless steel needles with silver spiral handles, steel needles with plastic handles, steel needles with copper handles, steel needles with aluminum handles, and products with both needle body and handle constructed from stainless steel.

With the ever increasing acceptance of alternative medicine techniques by a growing percentage of the population, localized cutaneous argyria secondary to acupuncture needles must be kept in the differential diagnosis of a clinically pigmented lesion. In patients with a history of malignant melanoma, these lesions may be a cause for alarm by patients and their physicians. Our patient underwent 2 prior biopsies of worrisome lesions before the diagnosis of localized cutaneous argyria was made. We believe our patient developed localized cutaneous argyria after acupuncture was performed with surgical stainless steel needles with silver handles. The exact mechanism of silver deposition is not known. Histologically, lesions may demonstrate features consistent with argyria or pseudo-ochronosis. Knowledge of this phenomenon will help establish the correct diagnosis. Also, counseling patients with melanoma on avoidance of acupuncture with needles that incorporate silver in their construction may prevent this worrisome occurrence of localized cutaneous argyria and/or pseudo-ochronosis.

## REFERENCES

1. Espinal ML, Ferrando L, Jimenez Diaz F. Asymptomatic blue nevus-like macule. *Arch Dermatol*. 1996;132:461, 464.
2. Rongioletti F, Robert E, Buffa P, et al. Blue nevi-like dotted occupational argyria. *J Am Acad Dermatol*. 1992;27 (6 pt 1):1015-1016.
3. Bleehen SS, Gould DJ, Harrington CI, et al. Occupational argyria: light and electron microscopic studies and x-ray microanalysis. *Br J Dermatol*. 1981;104:19-26.
4. Dupuis LL, Shear NH, Zucker RM. Hyperpigmentation due to topical application of silver sulfadiazine cream. *J Am Acad Dermatol*. 1985;12:1112-1114.
5. Lamar LM, Bliss BO. Localized pigmentation of the skin due to topical mercury. *Arch Dermatol*. 1966;93:450-453.
6. Connor T, Braunstein B. Hyperpigmentation following the use of bleaching creams. localized exogenous ochronosis. *Arch Dermatol*. 1987;123:105-106, 108.
7. Tanita Y, Kato T, Hanada K, et al. Blue macules of localized argyria caused by implanted acupuncture needles. electron microscopy and roentgenographic microanalysis of deposited metal. *Arch Dermatol*. 1985;121:1550-1552.
8. Suzuki H, Baba S, Uchigasaki S, et al. Localized argyria with chrysiasis caused by implanted acupuncture needles. distribution and chemical forms of silver and gold in cutaneous tissue by electron microscopy and x-ray microanalysis. *J Am Acad Dermatol*. 1993;29 (5 pt 2):833-837.
9. Takeishi E, Hirose R, Hamasaki Y, et al. Localized argyria 20-years after embedding of acupuncture needles. *Eur J Dermatol*. 2002;12:609-611.
10. Legat FJ, Goessler W, Schlagenhaufen C, et al. Argyria after short-contact acupuncture [letter]. *Lancet*. 1998;352:241.
11. Morton CA, Fallowfield M, Kemmett D. Localized argyria caused by silver earrings. *Br J Dermatol*. 1996;135:484-485.
12. Shall L, Stevens A, Millard LG. An unusual case of acquired localized argyria. *Br J Dermatol*. 1990;123:403-407.
13. van den Nieuwenhuijsen IJ, Calame JJ, Bruynzeel DP. Localized argyria caused by silver earrings. *Dermatologica*. 1988;177:189-191.
14. Kirchoff DA. Localized argyria after a surgical endodontic procedure. report of a case. *Oral Surg Oral Med Oral Pathol*. 1971;32:613-617.
15. McGinnis JP Jr, Greer JL, Daniels DS. Amalgam tattoo: report of an unusual clinical presentation and the use of energy dispersive x-ray analysis as an aid to diagnosis. *J Am Dent Assoc*. 1985;110:52-54.
16. Robinson-Bostom L, Pomerantz D, Wilkel C, et al. Localized argyria with pseudo-ochronosis. *J Am Acad Dermatol*. 2002;46:222-227.
17. Horn TD, Hiatt KM. Cutaneous toxicities of drugs. In: Elder DE, Elenitsas R, Johnson BL Jr, et al, eds. *Lever's Histopathology of the Skin*. 9th ed. Philadelphia, Pa: Lippincott Williams & Wilkins; 2005:323-343.
18. Raso DS, Greene WB, Harley RA, et al. Silicone deposition in reconstruction scars of women with silicone breast implants. *J Am Acad Dermatol*. 1996;35:32-36.
19. Yamashita H, Miyamoto T, Umeda T, et al. Japanese literature on the risk and safety of acupuncture and moxibustion (9). dermatological adverse events in acupuncture treatment. *Zen Nihon Shinkyu Gakkai Zasshi*. 2001;51:201-207.