

# Primary Cutaneous Aspergillosis in a Patient With a Solid Organ Transplant: Case Report and Review of the Literature

Lacey M. Thomas, MD; Heidi K. Rand, MD; Jami L. Miller, MD; Alan S. Boyd, MD

## GOAL

To understand primary cutaneous aspergillosis to better manage patients with the condition

## OBJECTIVES

Upon completion of this activity, dermatologists and general practitioners should be able to:

1. Describe risk factors for *Aspergillus* infection.
2. Identify diagnostic methods for primary cutaneous aspergillosis.
3. Discuss treatment options for primary cutaneous aspergillosis.

**CME** Test on page 138.

This article has been peer reviewed and approved by Michael Fisher, MD, Professor of Medicine, Albert Einstein College of Medicine. Review date: January 2008.

This activity has been planned and implemented in accordance with the Essential Areas and Policies of the Accreditation Council for Continuing Medical Education through the joint sponsorship of Albert Einstein College of Medicine and Quadrant HealthCom, Inc. Albert

Einstein College of Medicine is accredited by the ACCME to provide continuing medical education for physicians.

Albert Einstein College of Medicine designates this educational activity for a maximum of 1 AMA PRA Category 1 Credit™. Physicians should only claim credit commensurate with the extent of their participation in the activity.

This activity has been planned and produced in accordance with ACCME Essentials.

Drs. Thomas, Rand, Miller, and Boyd report no conflict of interest. The authors report no discussion of off-label use. Dr. Fisher reports no conflict of interest.

*Primary cutaneous aspergillosis is an uncommon disease in immunocompetent individuals that often affects immunosuppressed hosts. We present the first reported case of primary cutaneous aspergillosis in a solid organ transplant recipient caused by*

*Aspergillus niger. Fruiting bodies were isolated from a necrotic ulcer arising in a surgical wound. Debridement alone failed to resolve the infection, emphasizing the need for early antifungal treatment combined with surgical management of this infection.*

*Cutis.* 2008;81:127-130.

Accepted for publication March 15, 2007.

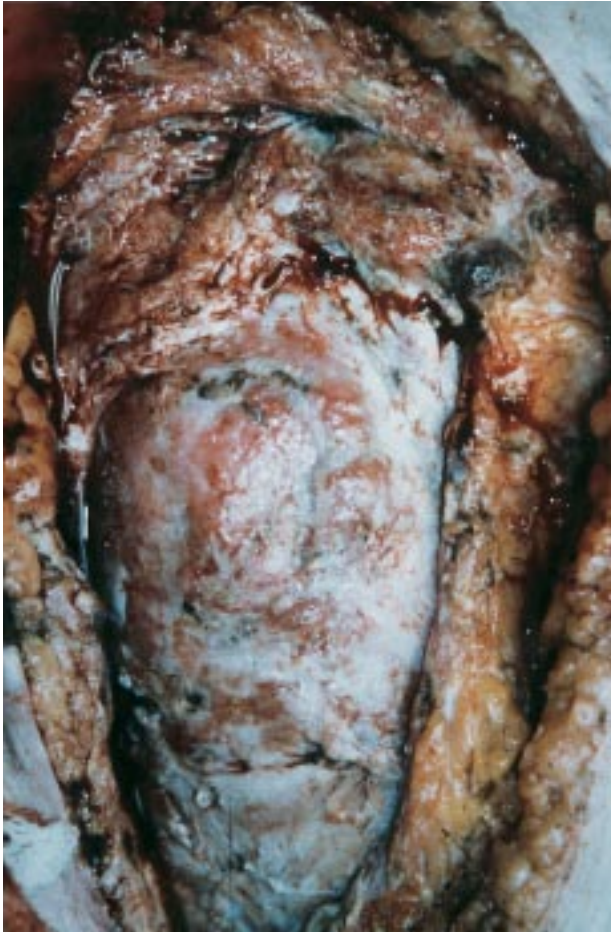Dr. Thomas is a dermatology resident and Drs. Miller and Boyd are Associate Professors, all from the Department of Dermatology, Vanderbilt University Medical Center, Nashville, Tennessee.

Dr. Rand is a dermatologist, private practice, Nashville.

Correspondence: Lacey M. Thomas, MD, Department of Dermatology, Vanderbilt University Medical Center, The Vanderbilt Clinic, 1301 22nd Ave S, Suite 3900, Nashville, TN 37232 (lacey.m.thomas@vanderbilt.edu).

## Case Report

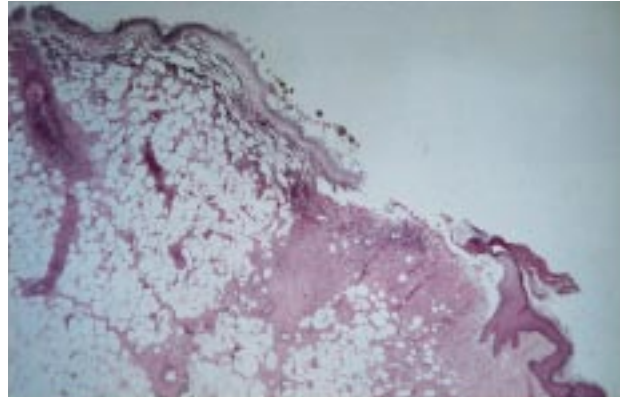
A 64-year-old woman presented to the Vanderbilt University Medical Center, Nashville, Tennessee, with right-sided abdominal pain, nausea, and dysuria of several days' duration 3 months after a cadaveric renal transplant and administration of cyclosporine and



**Figure 1.** Abdominal ulcer with friable necrotic base and scattered black eschar.

methylprednisolone. Pyelonephritis and acute tubular necrosis were diagnosed. Urine and blood cultures grew *Escherichia coli* and ultrasound imaging revealed ureteral obstruction of the transplanted kidney. Piperacillin/tazobactam and vancomycin were administered, and a right-sided nephrostomy tube was placed. One month later, the nephrostomy tube was removed and the ureter was reimplanted. The surgical wound, however, failed to close. Intravenous antibiotic administration was continued and wet-to-dry dressings were applied twice daily. In 3 days, the wound rapidly enlarged, became severely painful, and developed a black eschar. Despite repeated debridement, the black eschar would re-form within 24 hours after the procedure. Blood cultures were negative for fungus or bacteria but positive for cytomegalovirus. Piperacillin/tazobactam and vancomycin were continued, ganciclovir was added to the therapeutic regimen, and the dermatology department was consulted.

A large ulceration measuring 20×17 cm with a depth of 5.2 cm developed in the lower right quadrant of the abdomen (Figure 1). The ulcer base was



**Figure 2.** Full-thickness epidermal and dermal necrosis, hyphae, and *Aspergillus* fruiting bodies on the ulcer tissue (H&E, original magnification ×100).

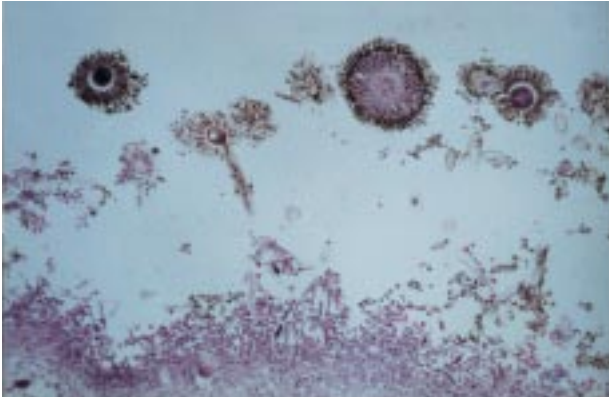
pink, friable, and covered with a fragile black eschar. Histologic evaluation of the ulcer base revealed full-thickness epidermal necrosis, numerous neutrophils, and dermal edema (Figure 2). A superficial layer of hyphae and fungal fruiting bodies was noted (Figures 3 and 4). Tissue culture from the wound grew *Aspergillus niger* and a diagnosis of primary cutaneous aspergillosis was made.

The patient underwent wide debridement of the abdominal wound and administration of maximal doses of liposomal amphotericin B. Despite aggressive treatment, she rapidly deteriorated and died 14 days later.

### Comment

*Aspergillus* is a ubiquitous saprophytic mold that belongs to the class Ascomycetes and is commonly found in soil, water, and decaying vegetation.<sup>1</sup> Although rarely a pathogen in immunocompetent individuals, it commonly affects immunocompromised individuals and is second in incidence in this population (*Candida* infection is most prevalent).<sup>2</sup> The name *Aspergillus* was proposed in 1729 when Pietro Antonio Micheli, an Italian priest and biologist, noted that the organism resembled the aspergillum used to sprinkle holy water.<sup>3</sup> To date, more than 900 species of *Aspergillus* have been defined. The most prevalent human pathogens include *Aspergillus flavus*, *Aspergillus fumigatus*, *A niger*, *Aspergillus terreus*, and *Aspergillus ustus*.<sup>3-5</sup>

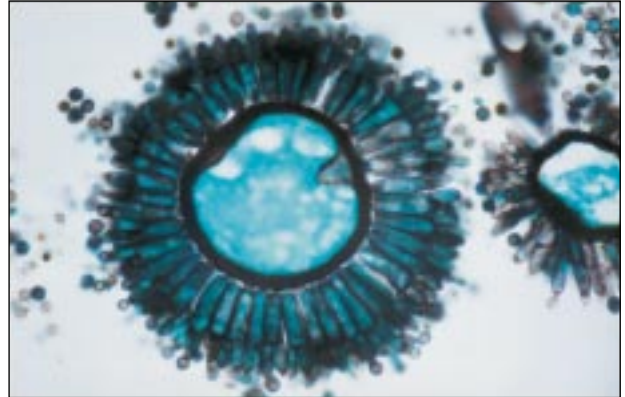
Risk factors for *Aspergillus* infection include inherited immunodeficiency disorders, organ transplantation, chronic corticosteroid and/or broad-spectrum antibiotic administration, cytotoxic chemotherapy, prolonged granulocytopenia, cirrhosis, diabetes mellitus, uremia, local tissue injury (ie, burn, surgical manipulation), underlying malignancy, chronic alcoholism, neonatal status, and cytomegalovirus infection.<sup>6</sup> Risk factors specific to solid organ transplant recipients



**Figure 3.** Superficial layer of hyphae beneath the fruiting bodies on the ulcer base (H&E, original magnification  $\times 200$ ).

include prolonged surgeries; laparotomies, excluding those at transplantation; uremia; neutropenia; cytomegalovirus infection; and administration of high-dose corticosteroids, tacrolimus, or cyclosporine.<sup>7</sup>

Cutaneous aspergillosis is classically described as primary or secondary. Secondary disease occurs via hematogenous dissemination, often from a pulmonary focus, or by extension from a contiguous anatomic site.<sup>2</sup> In primary cutaneous aspergillosis, breaks in the skin are directly inoculated by airborne spores or contaminated materials.<sup>8</sup> The use of adhesive tape is a common risk factor. Intermittent stripping of the stratum corneum with dressing changes presumably induces sufficient mechanical trauma to permit infection following contact with contaminated arm boards, intravenous catheters, tape, or gauze.<sup>8-14</sup> Ongoing construction/renovation or air circulation systems harboring *Aspergillus* species may contribute to aerial dissemination of spores.<sup>3,15</sup> Potted plants in a hematology ward have been reported as a source of *A terreus* infection, and certain foods, especially pepper (ground black pepper) and tea (regular and herbal tea), have high rates of contamination with *Aspergillus* species.<sup>16,17</sup> Primary cutaneous aspergillosis begins as an erythematous fluctuant nodule that undergoes rapid ulceration, which produces a central black eschar.<sup>8</sup> *A flavus* is the most common pathogen in primary cutaneous aspergillosis, but infection with *Aspergillus glaucus*, *A niger*, *A terreus*, and *A ustus* also have been described.<sup>2</sup> Primary cutaneous aspergillosis in solid organ transplant recipients is uncommon, and to our knowledge, this is the first reported case caused by *A niger*. In this population, cutaneous aspergillosis can occur as a primary infection directly in the surgical wound or as nodules near a site of a break in the epidermis that is different than the primary surgical wound.<sup>9</sup> Patients present with fever, changes in the wound surface, swelling, induration, and tenderness. Interestingly, primary cutaneous aspergillosis



**Figure 4.** Fruiting body of *Aspergillus niger* (Gomori methenamine silver, original magnification  $\times 400$ ).

in solid organ transplant recipients generally occurs despite a neutrophil count within reference range.<sup>9</sup> Rapid diagnosis can be made by potassium hydroxide examination of the wound as well as skin biopsy and tissue culture.<sup>15</sup> Because *Aspergillus* tends to invade blood vessels of the dermis and subcutaneous tissues, biopsy specimens should be taken from the center of the lesion and should include subcutaneous fat. Mycelial forms of the organism may be found within the epidermis and dermis. *Aspergillus* is a dichotomous branching fungus with septate hyphae measuring 3  $\mu\text{m}$  in diameter and branching at a 45° angle. The fruiting body rarely is observed in tissue samples unless an overwhelming number of organisms are present.<sup>5,9,18</sup> The fungal elements may be visualized with hematoxylin and eosin stain but are highlighted by Gomori methenamine-silver or periodic acid-Schiff stains. Tissue cultures should be grown in Sabouraud dextrose agar. The diagnosis of primary cutaneous aspergillosis can be made only after excluding other sites of infection.

Successful treatment of primary cutaneous aspergillosis requires a high index of suspicion, with early diagnosis and aggressive management. Primary cutaneous aspergillosis should be considered in the differential diagnosis of necrotizing skin lesions and nonhealing surgical wounds in immunosuppressed patients. Maximized immunosurveillance is critical and immunosuppressive medications should be decreased or discontinued if possible. Necrotic tissue requires debridement. However, as demonstrated in our patient, debridement alone may be insufficient for eradication of the infection, especially in immunocompromised patients. Antifungal antibiotics should be administered as soon as possible. The classic antimicrobial drug of choice is intravenous amphotericin B.<sup>2,3,19,20</sup> This drug is fungicidal both in vitro and in vivo, with a low incidence of resistance.<sup>21,22</sup> However, studies have shown better survival rates

with voriconazole compared with amphotericin B as initial therapy for invasive aspergillosis.<sup>23,24</sup> Caspofungin combined with voriconazole also has been shown to be particularly effective as initial treatment of invasive aspergillosis in solid organ transplant recipients with renal dysfunction or *A fumigatus* infections.<sup>25</sup>

## REFERENCES

1. Weingarten JS, Crockett DM, Lusk RP. Fulminant aspergillosis: early cutaneous manifestations and the disease process in the immunocompromised host. *Otolaryngol Head Neck Surg.* 1987;97:495-499.
2. Stiller MJ, Teperman L, Rosenthal SA, et al. Primary cutaneous infection by *Aspergillus ustus* in a 62-year-old liver transplant recipient. *J Am Acad Dermatol.* 1994;31(2, pt 2):344-347.
3. Isaac M. Cutaneous aspergillosis. *Dermatol Clin.* 1996;14:137-140.
4. Gene J, Azon-Masoliver A, Guarro J, et al. Cutaneous infection caused by *Aspergillus ustus*, and emerging opportunistic fungus in immunosuppressed patients. *J Clin Microbiol.* 2001;39:1134-1136.
5. Harmon CB, Su WP, Peters MS. Cutaneous aspergillosis complicating pyoderma gangrenosum. *J Am Acad Dermatol.* 1993;29:656-658.
6. Conant MA. Fungal infections in immunocompromised individuals. *Dermatol Clin.* 1996;14:155-162.
7. Patel R, Paya CV. Infections in solid-organ transplant recipients. *Clin Microbiol Rev.* 1997;10:86-124.
8. Chakrabarti A, Gupta V, Biswas G, et al. Primary cutaneous aspergillosis: our experience in 10 years. *J Infect.* 1998;37:24-27.
9. van Burik JA, Colven R, Spach DH. Cutaneous aspergillosis. *J Clin Microbiol.* 1998;36:3115-3121.
10. Allo MD, Miller J, Townsend T, et al. Primary cutaneous aspergillosis associated with Hickman intravenous catheters. *N Engl J Med.* 1987;317:1105-1108.
11. Hunt SJ, Nagi C, Gross KG, et al. Primary cutaneous aspergillosis near central venous catheters in patients with the acquired immunodeficiency syndrome. *Arch Dermatol.* 1992;128:1229-1232.
12. Carlile JR, Millet RE, Cho CT, et al. Primary cutaneous aspergillosis in a leukemic child. *Arch Dermatol.* 1978;114:78-80.
13. McCarty JM, Flam MS, Pullen G, et al. Outbreak of primary cutaneous aspergillosis related to intravenous arm boards. *J Pediatr.* 1986;108(5, pt 1):721-724.
14. Emmanouilides C, Glaspy J. Opportunistic infections in oncologic patients. *Hematol Oncol Clin North Am.* 1996;10:841-860.
15. Grossman ME, Fithian EC, Behrens C, et al. Primary cutaneous aspergillosis in six leukemic children. *J Am Acad Dermatol.* 1985;12(2, pt 1):313-318.
16. Lass-Flörl C, Rath P, Niederwieser D, et al. *Aspergillus terreus* infections in haematological malignancies: molecular epidemiology suggests association with in-hospital plants. *J Hosp Infect.* 2000;46:31-35.
17. Bouakline A, Lacroix C, Roux N, et al. Fungal contamination of food in hematology units. *J Clin Microbiol.* 2000;38:4272-4273.
18. Panke TW, McManus AT Jr, McLeod CG Jr. "Fruiting bodies" of *Aspergillus* on the skin of a burned patient. *Am J Clin Pathol.* 1978;69:188-189.
19. Larkin JA, Greene JN, Sandin RL, et al. Primary cutaneous aspergillosis: case report and review of literature. *Infect Control Hosp Epidemiol.* 1996;17:365-366.
20. Ricci RM, Evans JS, Meffert JJ, et al. Primary cutaneous *Aspergillus ustus* infection: second reported case. *J Am Acad Dermatol.* 1998;38(5, pt 2):797-798.
21. Denning DW, Stevens DA. Antifungal and surgical treatment of invasive aspergillosis: review of 2,121 published cases [published correction appears in *Rev Infect Dis.* 1991;13:345]. *Rev Infect Dis.* 1990;12:1147-1201.
22. Manavathu EK, Abraham OC, Chandrasekar PH. Isolation and in vitro susceptibility to amphotericin B, itraconazole and posaconazole of voriconazole-resistant laboratory species of *Aspergillus fumigatus*. *Clin Microbiol Infect.* 2001;7:130-137.
23. Herbrecht R, Denning DW, Patterson TF, et al. Voriconazole versus amphotericin B for primary therapy of invasive aspergillosis. *N Engl J Med.* 2002;347:408-415.
24. Muñoz P, Singh N, Bouza E. Treatment of solid organ transplant patients with invasive fungal infections: should a combination of antifungal drugs be used? *Curr Opin Infect Dis.* 2006;19:365-370.
25. Singh N, Limaye AP, Forrest G, et al. Combination of voriconazole and caspofungin as primary therapy for invasive aspergillosis in solid organ transplant recipients: a prospective, multicenter, observational study. *Transplantation.* 2006;81:320-326.

### DISCLAIMER

The opinions expressed herein are those of the authors and do not necessarily represent the views of the sponsor or its publisher. Please review complete prescribing information of specific drugs or combination of drugs, including indications, contraindications, warnings, and adverse effects before administering pharmacologic therapy to patients.

### CONFLICT OF INTEREST STATEMENT

The Conflict of Interest Disclosure Policy of Albert Einstein College of Medicine requires that authors participating in any CME activity disclose to the audience any relationship(s) with a pharmaceutical or equipment company. Any author whose disclosed relationships prove to create a conflict of interest, with regard to their contribution to the activity, will not be permitted to present.

The Albert Einstein College of Medicine also requires that faculty participating in any CME activity disclose to the audience when discussing any unlabeled or investigational use of any commercial product, or device, not yet approved for use in the United States.