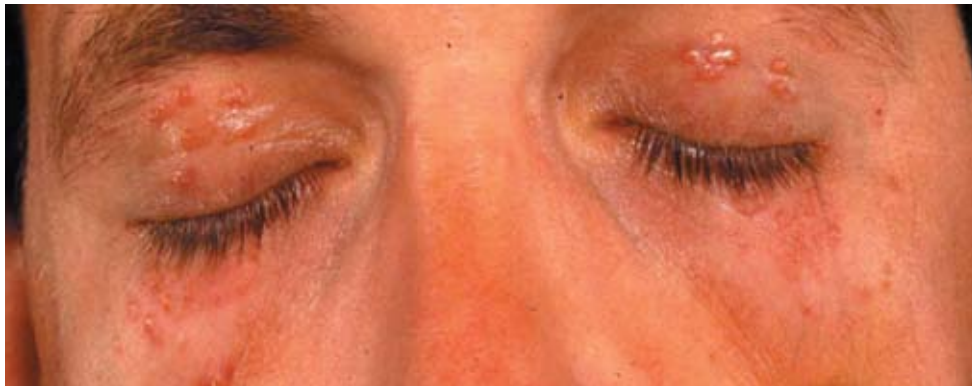

## What Is Your Diagnosis?

---



A 32-year-old man presented with a 6-month history of lesions on his face. Clinically, facial papules were observed. Papules initially appeared on his left lower eyelid and progressed over 3 weeks to involve the upper and lower eyelids, eyebrows, and right cheek. The lesions had been unresponsive to tetracycline hydrochloride therapy (1000 mg daily for 16 days) and intralesional corticosteroid injections and progressed despite repeated electrodesiccation and cryosurgical destruction. The patient's medical history was noncontributory. Except for the facial lesions, the findings of his physical examination were unremarkable. Three-millimeter punch biopsies were performed on his left lateral upper eyelid and right eyebrow.

PLEASE TURN TO PAGE 111 FOR DISCUSSION

---

Alison K. Adams, BS; Jaime L. Davis, MD; Mark D.P. Davis, MD; Roy S. Rogers III, MD; Department of Dermatology, Mayo Clinic, Rochester, Minnesota.

The authors report no conflict of interest.

## The Diagnosis: Granulomatous Rosacea (Lupus Miliaris Disseminatus Faciei, Acne Agminata)

With clinicopathologic correlation, granulomatous rosacea was diagnosed in our patient with facial papules (Figure 1). Histopathologic examination of the skin biopsy specimens showed caseation necrosis with palisading granulomas (Figures 2 and 3). A lymphocytic infiltrate also was present. A prior biopsy conducted at another facility was interpreted as a necrotizing granuloma with inflammation. Results of laboratory tests for angiotensin-converting enzyme, complete blood cell count, complement levels, erythrocyte sedimentation rate, thyrotropin, and thyroxine were within the reference ranges, and a chemistry panel, rapid plasma reagin test, and urinalysis did not reveal any abnormalities. Chest radiography, electrocardiography, serum immunoelectrophoresis, and serum protein electrophoresis were normal. A purified protein derivative (tuberculin) test was negative for tuberculosis.

The differential diagnosis for discrete eyelid papules with caseation necrosis and palisading necrosis includes tuberculosis, sarcoidosis, and granulomatous rosacea (lupus miliaris disseminatus faciei, acne agminata). In our patient, tuberculosis was unlikely because tuberculous organisms were not cultured, and sarcoidosis was less likely because of the observed caseation.

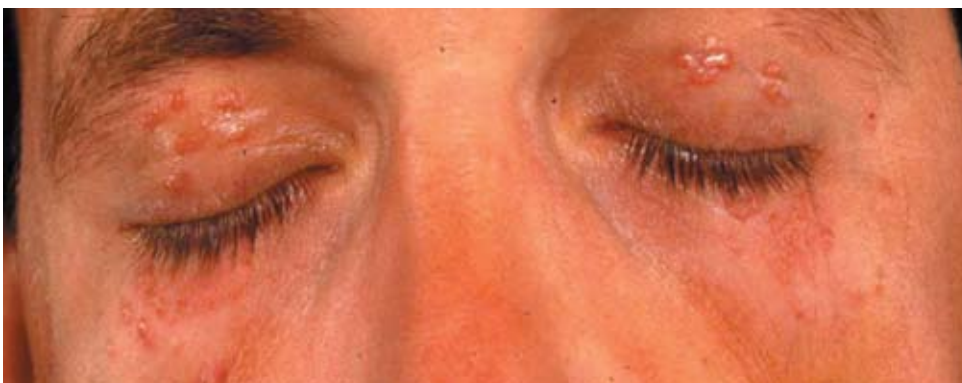Various terms have been used to describe this clinicopathologic entity. In 1878, Fox<sup>1</sup> described granulomatous rosacea using the nomenclature *disseminated follicular lupus*, and in 1903, the term *acne agminata* was used by Radcliffe-Crocker<sup>2</sup> in describing a papular eruption on the face that was morphologically distinct from acne vulgaris. *Granulomatous rosacea*, a subtype of rosacea, is a more recently applied term. In a study of 53 patients

with granulomatous rosacea, epithelioid granulomas were observed in 11% of patients (6/53), and epithelioid granulomas with caseation necrosis were observed in 11% of patients (6/53).<sup>3</sup> Clinically, acne agminata presents as discrete brown papules that are 1 to 3 mm in diameter, often with yellowish centers. The papules are symmetrically distributed in the centrafacial regions, particularly around the eyebrows.

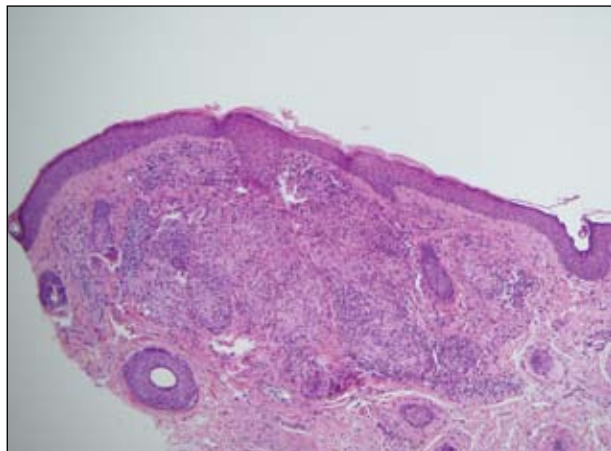
Granulomatous rosacea mainly occurs in adults, though adolescent<sup>4</sup> and elderly<sup>5</sup> patients with the condition also have been reported. Granulomatous rosacea has been reported to involve most areas of the face, including the upper and lower eyelids, eyebrows, upper cheeks, upper lip, and chin. Lesions usually consist of multiple red-brown to yellow papules symmetrically scattered over the face.<sup>6-9</sup>

On diascopy, the papules may resemble apple jelly nodules. The lesions persist for months or years and then spontaneously involute and scar. The histopathology of granulomatous rosacea typically shows dermal granulomatous inflammation characterized by a central necrotic zone surrounded by epithelioid cells, lymphocytes, and multinucleate giant cells.

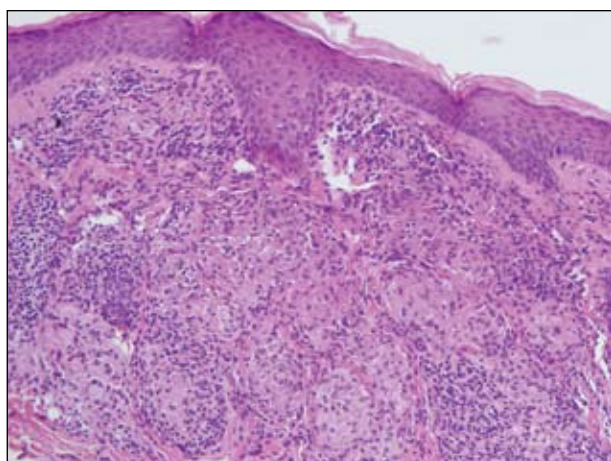
The cause of granulomatous rosacea is unknown. Because of the granulomatous features, the papules were originally considered to be tuberculid, but it is now generally accepted that tuberculosis has no role in granulomatous rosacea. Other proposed causes include a foreign body reaction to disintegrating pilosebaceous units, follicular cysts, or *Demodex folliculorum* mites<sup>10</sup> or a hypersensitivity reaction to zirconium.<sup>11</sup> It is now accepted that granulomatous rosacea is in the spectrum of rosacea or sarcoidosis.<sup>12</sup> It also is possible that this entity is distinct from



**Figure 1.** Papules on the face.



**Figure 2.** Punch biopsy specimen from the left lateral upper eyelid (H&E, original magnification  $\times 10$ ).



**Figure 3.** Punch biopsy specimen from the right eyebrow (H&E, original magnification  $\times 20$ ).

rosacea or sarcoidosis, as it does not have the telangiectases, erythema, and fluctuating intensity usually seen in acne rosacea. The distribution consistently includes the eyelids and upper lip, and the term *acne agminata* is more appropriate.

Tetracyclines,<sup>5</sup> dapsone,<sup>6</sup> clofazimine,<sup>9</sup> and systemic corticosteroids<sup>7</sup> are effective treatments for some patients. In 2005, a 1450-nm diode laser was used to treat granulomatous rosacea lesions, which resolved after 3 treatments.<sup>8</sup> The natural course of granulomatous rosacea includes distribution of lesions on the eyelids and upper lip and chronic

disease that may persist for months or years. Lesions eventually resolve with scarring.<sup>7,8</sup>

**Acknowledgment**—The authors thank Nneka I. Comfere, MD, Mayo Clinic, Rochester, Minnesota, for her assistance with the histopathologic figures and descriptions. Editing, proofreading, and reference verification were provided by the Section of Scientific Publications, Mayo Clinic.

## REFERENCES

1. Fox T. Clinical lecture on disseminated follicular lupus (simulating acne). *Lancet*. 1878;13:35-36.
2. Radcliffe-Crocker H. *Diseases of the Skin*. 3rd ed. London, England: Lewis; 1903.
3. Helm KF, Menz J, Gibson LE, et al. A clinical and histopathologic study of granulomatous rosacea. *J Am Acad Dermatol*. 1991;25(6, pt 1):1038-1043.
4. Edeling CJ, Snorrason K, Medgyesi S. An atypical case of lupus miliaris faciei simulating dermoid cyst: diagnostic and therapeutic difficulties. *Scand J Plast Reconstr Surg*. 1986;20:235-237.
5. Dekio S, Jidoi J, Imaoka C. Lupus miliaris disseminatus faciei: report of a case in an elderly woman. *Clin Exp Dermatol*. 1991;16:295-296.
6. Kumano K, Tani M, Murata Y. Dapsone in the treatment of miliary lupus of the face. *Br J Dermatol*. 1983;109:57-62.
7. Uesugi Y, Aiba S, Usuba M, et al. Oral prednisone in the treatment of acne agminata. *Br J Dermatol*. 1996;134:1098-1100.
8. Jih MH, Friedman PM, Kimyai-Asadi A, et al. Lupus miliaris disseminatus faciei: treatment with the 1450-nm diode laser. *Arch Dermatol*. 2005;141:143-145.
9. Seukeran DC, Stables GI, Cunliffe WJ, et al. The treatment of acne agminata with clofazimine. *Br J Dermatol*. 1999;141:596-597.
10. Pinkus H, Mehregan AH. Predominantly mononuclear granulomas. In: Pinkus H, Mehregan AH, eds. *A Guide to Dermatohistopathology*. 3rd ed. New York, NY: Appleton-Century-Crofts; 1981:231.
11. Palmer L, Welton WA. Lupus miliaris disseminatus faciei—zirconium hypersensitivity as possible cause. *Cutis*. 1967;3:744-748.
12. Simonart T, Lowy M, Rasquin F, et al. Overlap of sarcoidosis and rosacea. *Dermatology*. 1997;194:416-418.