

Fungal Foes: *Lacazia loboi*

Dirk M. Elston, MD; Omar P. Sangüeza, MD

Lobomycosis is a chronic cutaneous infection that may present with keloidal masses, and nodular, verrucous, or ulcerated lesions. The causative organism, *Lacazia* (formerly *Loboa*) *loboi*, affects dolphins as well as humans and is more common where water salinity is reduced. The Amazon Basin is endemic for the disease, but it is being recognized in other parts of the world such as the Indian River Lagoon in Florida. In the Indian River Lagoon, the disease is more common in the southern portion of the lagoon where fresh water effluents dilute the salt water. In one study, 9 of 30 dolphins from the southern portion of the lagoon were found to have lobomycosis compared to none of the 45 dolphins from the northern portion of the lagoon or estuaries off the coast of South Carolina.¹

Human disease occurs mostly in the Amazon Basin. Because of travel, human disease occasionally has been identified in Europe, the United States, and Canada.^{2,3} Keloidal or nodular lesions are most common (Figure 1). Squamous cell carcinoma has been reported in long-standing scars of lobomycosis.⁴

The diagnosis of lobomycosis is confirmed by biopsy, which demonstrates chains of large spherical organisms (6–12 μm in diameter) resembling a child's pop beads. The chains are more easily identified with Gomori methenamine-silver or periodic acid–Schiff stains (Figure 2). In tissue, the organisms reach larger sizes in humans than in dolphins.⁵ *Lacazia loboi* is closely related to *Paracoccidioides brasiliensis* and both demonstrate

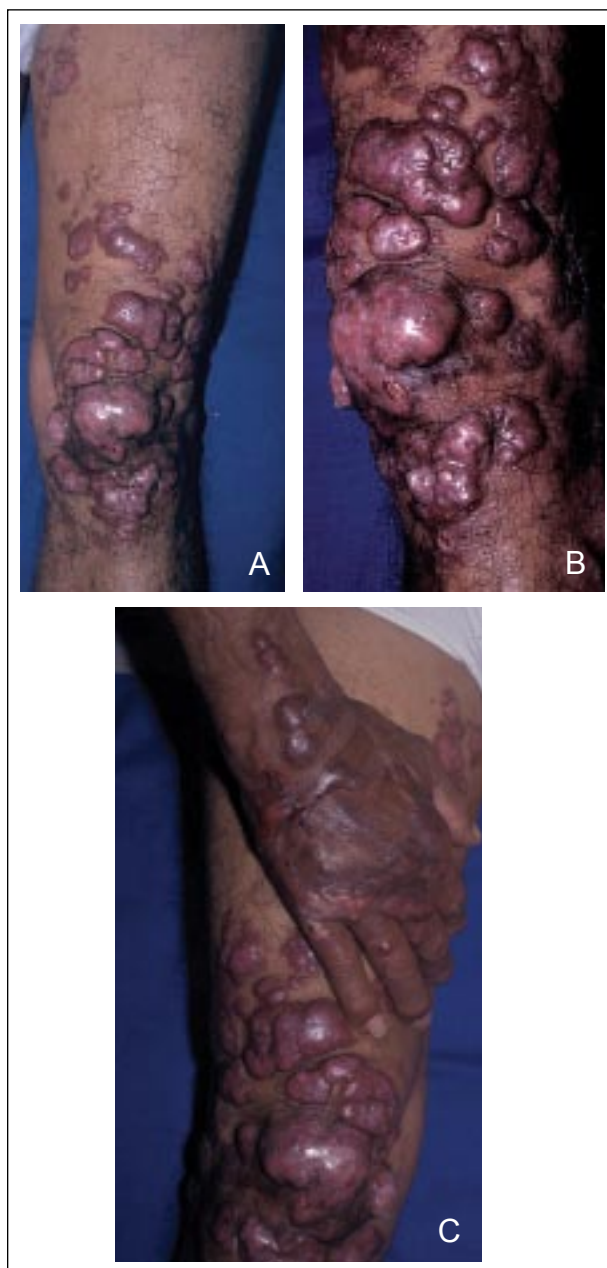

Figure 1. Keloidal and nodular lesions of lobomycosis (A–C).

Accepted for publication September 8, 2008.

Dr. Elston is from the Departments of Dermatology and Laboratory Medicine, Geisinger Medical Center, Danville, Pennsylvania.

Dr. Sangüeza is from Wake Forest University School of Medicine, Winston-Salem, North Carolina.

The authors report no conflict of interest.

The images are in the public domain.

Correspondence: Dirk M. Elston, MD, Department of Dermatology, Geisinger Medical Center, 100 N Academy Ave, Danville, PA 17822-5206 (dmelston@geisinger.edu).

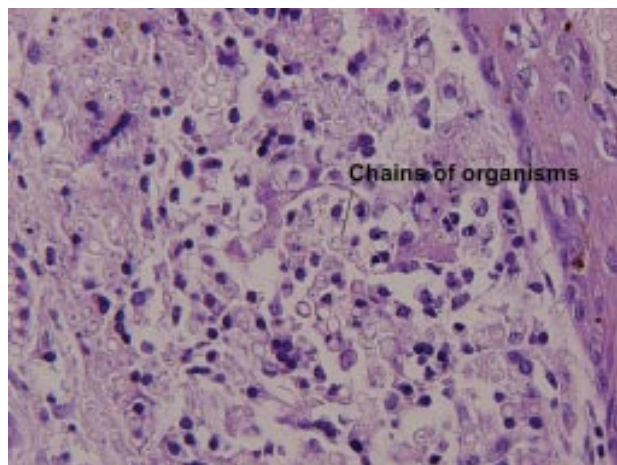


Figure 2. Biopsy specimen demonstrating chains of organisms characteristic of lobomycosis (periodic acid-Schiff, original magnification $\times 200$).

antigenic cross-reactions.⁶ Serologic tests show little to no cross-reaction with other genera. Chronic lobomycosis is associated with partial anergy, evidenced by lack of reactivity to dinitrochlorobenzene in 92% (11/12) of patients tested, as well as negative skin reactions to streptococcal, staphylococcal, trichophytin, and candida antigens in most patients tested. In contrast, the patients tested demonstrated strong reactivity to mycobacterial antigens.⁷

Antifungal therapy generally has not been effective and surgical excision is the mainstay of therapy. Antifungal therapy may be beneficial in

some patients, and treatment with itraconazole and clofazimine was reported as successful even after 32 years of disease.⁸ In contrast, ketoconazole therapy generally has proved ineffective.

REFERENCES

1. Reif JS, Mazzoil MS, McCulloch SD, et al. Lobomycosis in Atlantic bottlenose dolphins from the Indian River Lagoon, Florida. *J Am Vet Med Assoc.* 2006;228:104-108.
2. Elsayed S, Kuhn SM, Barber D, et al. Human case of lobomycosis. *Emerg Infect Dis.* 2004;10:715-718.
3. Burns RA, Roy JS, Woods C, et al. Report of the first human case of lobomycosis in the United States. *J Clin Microbiol.* 2000;38:1283-1285.
4. Baruzzi RG, Rodrigues DA, Michalany NS, et al. Squamous-cell carcinoma and lobomycosis (Jorge Lobo's disease). *Int J Dermatol.* 1989;28:183-185.
5. Haubold EM, Cooper CR Jr, Wen JW, et al. Comparative morphology of *Lacazia loboi* (syn. *Loboa loboi*) in dolphins and humans. *Med Mycol.* 2000;38:9-14.
6. Camargo ZP, Baruzzi RG, Maeda SM, et al. Antigenic relationship between *Loboa loboi* and *Paracoccidioides brasiliensis* as shown by serological methods. *Med Mycol.* 1998;36:413-417.
7. Pecher SA, Fuchs J. Cellular immunity in lobomycosis (keloidal blastomycosis). *Allergol Immunopathol (Madr).* 1988;16:413-415.
8. Fischer M, Chrusciak Talhari A, Reinell D, et al. Successful treatment with clofazimine and itraconazole in a 46 year old patient after 32 years duration of disease [in German]. *Hautarzt.* 2002;53:677-681.