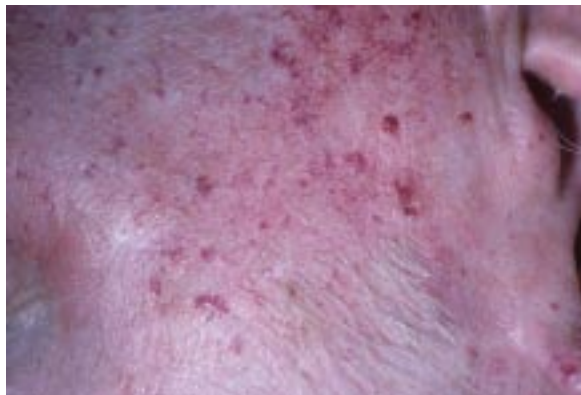
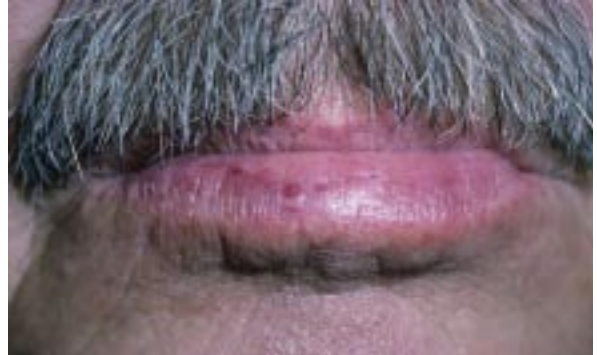
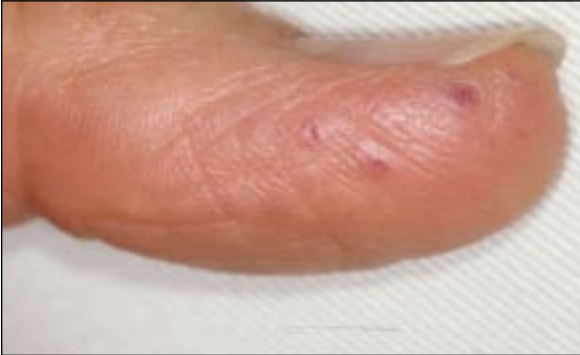What Is Your Diagnosis?

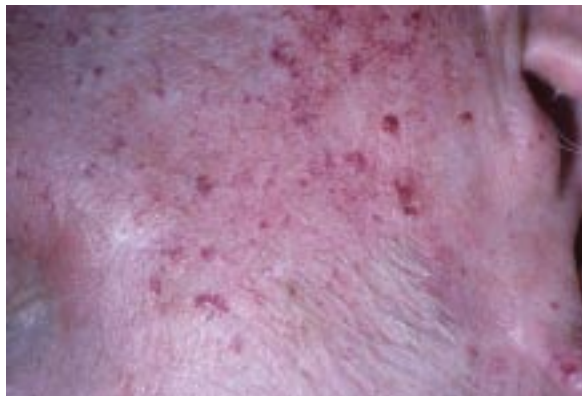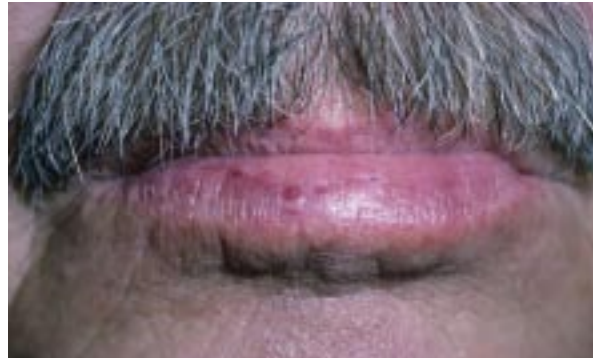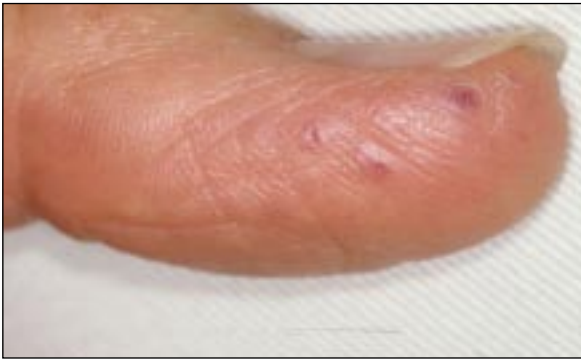


The patient had a history of severe nosebleeds and a family history of cerebral abscess. He presented with multiple skin lesions involving the ears, nose, cheeks, lips, and digits.

PLEASE TURN TO PAGE 13 FOR DISCUSSION

Dirk M. Elston, MD, Departments of Dermatology and Laboratory Medicine, Geisinger Medical Center, Danville, Pennsylvania.
The author reports no conflict of interest.
The images are in the public domain.

The Diagnosis: Hereditary Hemorrhagic Telangiectasia (Osler-Rendu-Weber Disease)



Hereditary hemorrhagic telangiectasia (HHT) is characterized by progressive telangiectasia affecting the nasal, oral, and gastrointestinal mucosa, as well as the skin. The disease is inherited as an autosomal dominant trait with age-related penetrance. Clinical manifestations continue to develop throughout life.¹ In approximately 80% of cases, nosebleed is the first sign of the disease.² Cutaneous lesions are most prominent on the digits, ears, and lips, though they may be widespread. Telangiectatic mats characteristically have individual vessels radiating from the edge, which contrasts with the sharper border of the telangiectatic mats of scleroderma.

Hereditary hemorrhagic telangiectasia is associated with numerous episodes of epistaxis; gastrointestinal tract bleeding; and arteriovenous malformations of the lung, liver, and central nervous system. Coronary arteriovenous malformations also have been reported.³ Severe complications of the disease include cerebral abscess, cerebral

hemorrhage,⁴ and angina. The presence of pulmonary arteriovenous malformations may increase the risk for brain abscess by allowing bacteria to bypass the filtering action of pulmonary capillaries.⁵ Epilepsy also may occur as a complication of HHT.⁶ Patients should be advised about antibiotic prophylaxis during minor procedures, such as dental procedures and skin surgery. Although bleeding is a potential complication during skin procedures, complex skin procedures, including flaps and grafts, have been successfully performed in patients with HHT.⁷

Computed tomography with contrast, angiography, and ultrasonography can be useful in the diagnosis of arteriovenous malformations.⁸ Angiography with selective embolization can be a valuable diagnostic and therapeutic option in patients with severe epistaxis.⁹ In view of the high incidence and potential severe complications associated with arteriovenous malformations, all patients should be screened for their presence and relatives should be screened for signs of the syndrome.¹⁰

Chest radiographs may be insufficiently sensitive to screen for pulmonary arteriovenous malformations. Contrast echocardiography and pulse oximetry are more sensitive tools for screening.¹¹

Most treatment recommendations are based on clinical experience rather than large controlled studies.¹² Supportive therapy should include iron supplementation to correct anemia. Cauterization, photocoagulation, embolization, and excision with grafting have been used to stop bleeding and prevent recurrences. Blood transfusions may be required during episodes of severe bleeding. Aminocaproic acid,¹³ tranexamic acid, and hormonal therapy have been used in an effort to prevent mucosal bleeding.¹⁴ Photocoagulation with the pulsed dye laser (585 nm) may require several treatments before a measurable reduction in the number of bleeding episodes is achieved.¹⁵

Endoglin (CD105), the target gene for HHT type 1, is a cell surface component of the transforming growth factor β receptor complex.¹⁶ Haploinsufficiency leading to reduced protein expression appears to be the predominant mechanism of this autosomal dominant syndrome.¹⁷ Hereditary hemorrhagic telangiectasia type 1 is associated with an increased incidence of pulmonary arteriovenous malformations than HHT type 2, which is associated with mutation of the activin receptor-like kinase 1 gene, *ALK-1*.¹⁸ *ALK-1* is an endothelial cell receptor for the transforming growth factor β superfamily of ligands.¹⁹ Genes for HHT may be linked to genes for familial juvenile polyposis.²⁰ Families with one syndrome should be screened for the other.

REFERENCES

- Shovlin CL, Letarte M. Hereditary hemorrhagic telangiectasia and pulmonary arteriovenous malformations: issues in clinical management and review of pathogenic mechanisms. *Thorax*. 1999;54:714-729.
- Bergler W, Götke K. Hereditary hemorrhagic telangiectasias: a challenge for the clinician. *Eur Arch Otorhinolaryngol*. 1999;256:10-15.
- Gurevitch Y, Hasin Y, Gotsman MS, et al. Coronary arteriovenous malformations in a patient with hereditary hemorrhagic telangiectasia—a case report. *Angiology*. 1998;49:577-580.
- Hosoi K, Tomita H, Tamaki N. Rendu-Osler-Weber disease with cerebral hemorrhage due to a capillary telangiectasia: a case report [in Japanese]. *No Shinkei Geka*. 1999;27:483-486.
- Brydon HL, Akinwunmi J, Selway R, et al. Brain abscesses associated with pulmonary arteriovenous malformations. *Br J Neurosurg*. 1999;13:265-269.
- Griffiths PD, Blaser S, Armstrong D, et al. Cerebellar arteriovenous malformations in children. *Neuroradiology*. 1998;40:324-331.
- Breuninger H, Bogenschütz O, Konrad E, et al. Telangiectasia haemorrhagica hereditaria. surgical therapy for malignant skin tumors (Osler-Weber-Rendu disease) [in German]. *Hautarzt*. 1997;48:496-499.
- Akiyama Y, Takeda Y, Soma T, et al. Familial pulmonary arteriovenous malformation diagnostic of the Osler-Weber-Rendu disease [in Japanese]. *Nihon Kokyuki Gakkai Zasshi*. 1998;36:488-493.
- Mérol JC, Parvy F, Seidermann L, et al. Role of super selective arteriography with embolization in the treatment of severe epistaxis: our experience apropos of 16 cases [in French]. *Rev Laryngol Otol Rhinol (Bord)*. 1996;117:363-366.
- Haitjema T, Westermann CJ, Overtoom TT, et al. Hereditary hemorrhagic telangiectasia (Osler-Weber-Rendu disease): new insights in pathogenesis, complications, and treatment. *Arch Intern Med*. 1996;156:714-719.
- Kjeldsen AD, Oxhøj H, Andersen PE, et al. Pulmonary arteriovenous malformations: screening procedures and pulmonary angiography in patients with hereditary hemorrhagic telangiectasia. *Chest*. 1999;116:432-439.
- Lund VJ, Howard DJ. A treatment algorithm for the management of epistaxis in hereditary hemorrhagic telangiectasia. *Am J Rhinol*. 1999;13:319-322.
- Annichino-Bizzacchi JM, Facchini RM, Torresan MZ, et al. Hereditary hemorrhagic telangiectasia response to aminocaproic acid treatment. *Thromb Res*. 1999;96:73-76.
- Fontana S, Lämmle B. Chronic, hemorrhage-induced iron deficiency anemia in Osler disease. *Ther Umsch*. 1999;56:526-528.
- Harries PG, Brockbank MJ, Shakespeare PG, et al. Treatment of hereditary haemorrhagic telangiectasia by the pulsed dye laser. *J Laryngol Otol*. 1997;111:1038-1041.
- Rius C, Smith JD, Almendro N, et al. Cloning of the promoter region of human endoglin, the target gene for hereditary hemorrhagic telangiectasia type 1. *Blood*. 1998;92:4677-4690.
- Pece-Barbara N, Cymerman U, Vera S, et al. Expression analysis of four endoglin missense mutations suggests that haploinsufficiency is the predominant mechanism for hereditary hemorrhagic telangiectasia type 1. *Hum Mol Gen*. 1999;8:2171-2181.
- Cymerman U, Vera S, Pece-Barbara N, et al. Identification of hereditary hemorrhagic telangiectasia type 1 in newborns by protein expression and mutation analysis of endoglin. *Pediatr Res*. 2000;47:24-35.
- Klaus DJ, Gallione CJ, Anthony K, et al. Novel missense and frameshift mutations in the activin receptor-like kinase-1 gene in hereditary hemorrhagic telangiectasia. mutations in brief no. 164. online. *Hum Mutat*. 1998;12:137.
- Ballauff A, Koletzko S. Hereditary hemorrhagic telangiectasia with juvenile polyposis—coincidence or linked autosomal dominant inheritance? *Z Gastroenterol*. 1999;37:385-388.