

# Langerhans Cell Histiocytosis Arising From a BCC: A Case Report and Review of the Literature

Payal Patel, DO; Rakhshandra Talpur, MD; Madeleine Duvic, MD

RELEASE DATE: June 2010

TERMINATION DATE: June 2011

The estimated time to complete this activity is 1 hour.

## GOAL

To understand Langerhans cell histiocytosis (LCH) to better manage patients with the condition

## LEARNING OBJECTIVES

Upon completion of this activity, you will be able to:

1. Discuss theories of the etiology of LCH.
2. Explain the presentation of LCH in combination with basal cell carcinoma (BCC).
3. Design a treatment course for patients with LCH and BCC.

## INTENDED AUDIENCE

This CME activity is designed for dermatologists and general practitioners.

**CME** Test and Instructions on page 293.

This article has been peer reviewed and approved by Michael Fisher, MD, Professor of Medicine, Albert Einstein College of Medicine. Review date: May 2010.

This activity has been planned and implemented in accordance with the Essential Areas and Policies of the Accreditation Council for Continuing Medical Education through the joint sponsorship of Albert Einstein College of Medicine and Quadrant HealthCom, Inc. Albert Einstein

College of Medicine is accredited by the ACCME to provide continuing medical education for physicians.

Albert Einstein College of Medicine designates this educational activity for a maximum of 1 AMA PRA Category 1 Credit™. Physicians should only claim credit commensurate with the extent of their participation in the activity.

This activity has been planned and produced in accordance with ACCME Essentials.

Drs. Patel, Talpur, and Duvic report no conflict of interest. The authors report no discussion of off-label use. Dr. Fisher reports no conflict of interest. The staff of CCME of Albert Einstein College of Medicine and *Cutis*® have no conflicts of interest with commercial interest related directly or indirectly to this educational activity.

*Langerhans cell histiocytosis (LCH) is a rare disease characterized by a proliferation of Langerhans cells. Several organs may be involved, including*

Dr. Patel was an intern, University Hospitals Richmond Medical Center, Richmond Heights, Ohio, and currently is a dermatology resident, Michigan State University/Genesys Medical Center, Grand Blanc. Dr. Talpur is a faculty member and Dr. Duvic is Deputy Department Chair, both from the Division of Internal Medicine, Department of Dermatology, The University of Texas MD Anderson Cancer Center, Houston.

Correspondence: Payal Patel, DO, Michigan State University/Genesys Medical Center, One Genesys Pkwy, Grand Blanc, MI 48439 (payal.patel@genesys.org).

*the skin, bone, and central nervous system. Adult onset of LCH and solely localized cutaneous involvement are quite uncommon. Langerhans cell histiocytosis has been found in combination with other skin lesions and systemic conditions, but no definitive conclusion exists for this phenomenon. We present a case report of a 63-year-old woman who initially presented with 3 pink papules on her forehead that had developed sequentially within 1 month, all diagnosed by biopsy as basal cell carcinoma (BCC) and appropriately treated. Concurrent with the appearance*

of the third BCC, the patient began developing crusted ulcerative nodules on her scalp. Biopsy of 1 scalp nodule revealed a BCC, but a repeat biopsy of the same nodule weeks later revealed LCH. Langerhans cell histiocytosis arising from a BCC is extremely rare. No absolute explanation exists regarding the transformation of a BCC into LCH, but understanding the behavior of Langerhans cells may give us better insight into how this process could occur.

*Cutis.* 2010;85:295-300.

**L**angerhans cell histiocytosis (LCH) is a rare condition caused by the proliferation of dendritic cells, staining positively for S-100 and CD1a, that accumulate in different organs of the body.<sup>1</sup> The etiology of the disease is unknown; infection with Epstein-Barr virus may be a triggering factor in some cases, and smoking has been identified as the main risk factor for isolated pulmonary LCH.<sup>2</sup> The incidence of LCH in children is 4 to 5 cases per million, while it is approximately 1 to 2 cases per million in adults.<sup>3</sup> Langerhans cell histiocytosis may involve various organs, but skin and nail disease often present first in the sequence of involvement.<sup>4</sup> Although rare, cases of isolated cutaneous involvement have been reported in the literature.<sup>5</sup> Seventy-five percent of patients with adult-onset LCH have cutaneous involvement, commonly in the form of seborrheic dermatitis, skin nodules, papules, purpura, xanthomas, or abscesses.<sup>6</sup> Scalp lesions in LCH classically appear as erythematous confluent plaques and papules with yellowish scale as well as crusting and erosion.<sup>7</sup> We present a case of localized cutaneous LCH in an adult scalp arising from basal cell carcinoma (BCC). In a literature review conducted with a PubMed search of articles indexed for MEDLINE using the terms *adult Langerhans cell histiocytosis* and *adult histiocytosis of basal cell carcinoma*, only 3 other cases of the combination of BCC and LCH in the skin have been reported.<sup>8-11</sup>

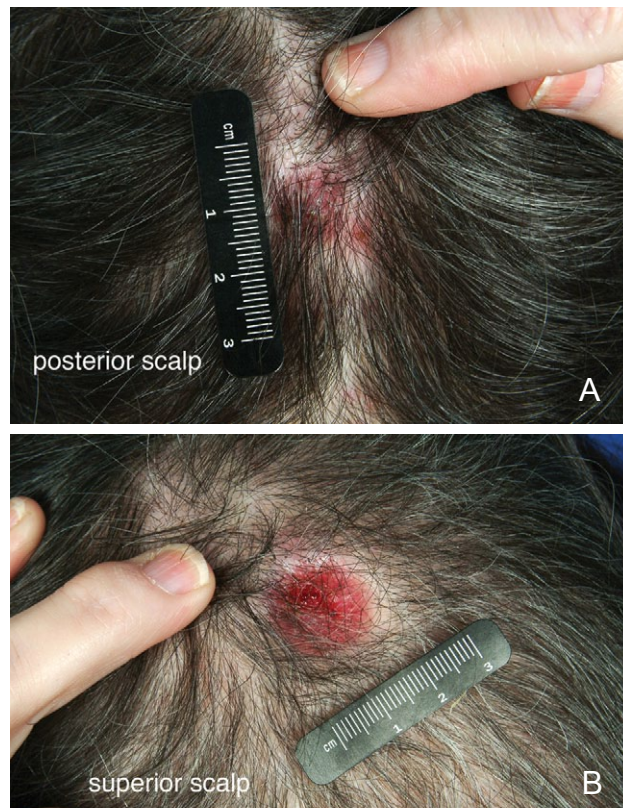### Case Report

A 63-year-old white woman presented with 3 persistent scalp lesions of 6 months' duration; 2 of these lesions were diagnosed as LCH by biopsies conducted by another physician. The patient's medical history included diabetes mellitus, hypertension, gastroesophageal reflux disease, peripheral vascular disease, Sjögren syndrome, diabetic neuropathy, thyroid cancer status post-excision and radioactive iodine therapy, cataracts, and BCC.

The patient reported that initially she had a pink papule on her right forehead that was biopsied and diagnosed as a BCC by another dermatologist. It was

appropriately treated; however, the lesion returned within 2 weeks. A repeat biopsy showed a BCC, which also was appropriately treated. Another lesion appeared in the same area 2 weeks later, which was biopsied, diagnosed as a BCC, and appropriately treated. Around the same time, the patient noticed a small, ulcerated, crusted nodule on the right parietal scalp. It was biopsied, diagnosed as a BCC, and appropriately treated. The lesion persisted and a second biopsy, done within weeks of the first, was consistent with LCH. An immunohistochemical analysis confirmed the expression of CD1a by many of the cells in the infiltrate. Subsequently, a similar lesion developed on the left parietal scalp and also was diagnosed as LCH by biopsy.

The patient was referred to The University of Texas MD Anderson Cancer Center, Houston, for treatment of LCH. By this time she had developed an additional nodule on her occipital scalp measuring 1.1×1.2 cm (Figure 1A), with a brown crusted eschar that crumbled when attempting to remove. An erythematous ulcerated tumor was noted beneath the eschar. Scattered erythematous papules were present on the forehead. The nodule on the left parietal scalp measured 3.0×2.5 cm. The nodule on the right parietal scalp measured 2.5×1.5 cm (Figure 1B). The



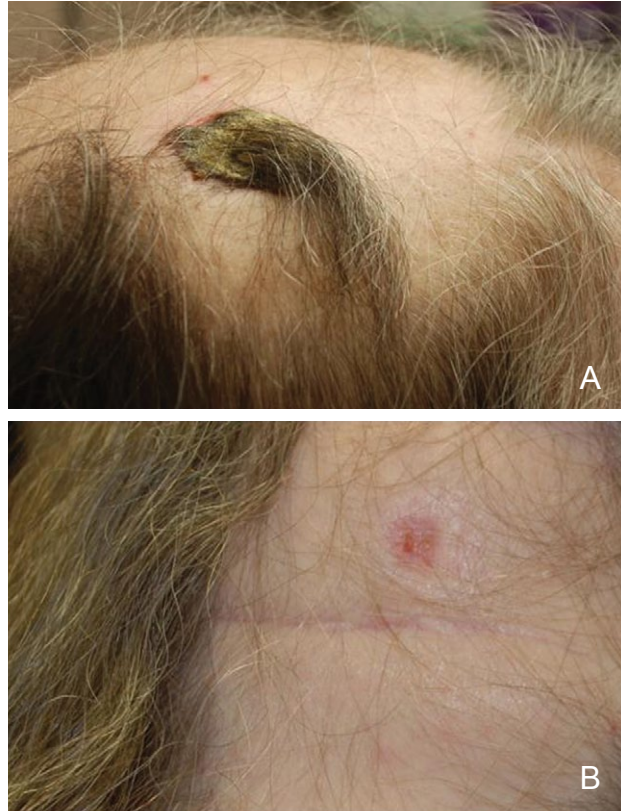**Figure 1.** Nodules on the occipital/posterior scalp (A) and right parietal/superior scalp (B).

rest of the face was clear. There was no rash on the left lower extremity, back, trunk, or buttocks. The nails, feet, palms, and soles were clear. The rest of the physical examination did not reveal any notable findings.

Results of a punch biopsy of the lesion from the occipital scalp showed acute and chronic inflammation with a prominent plasma cell infiltrate. A culture of the occipital scalp nodule grew *Staphylococcus aureus*. The patient was prescribed oral dicloxacillin 500 mg twice daily for 14 days. She was advised to apply mupirocin ointment 2% to all of her scalp lesions to help clear infection. She also was told to rinse the scalp with vinegar and water in a 1:4 ratio. The lesions did not resolve with this treatment for 2 weeks, so the patient was prescribed imiquimod cream 5% for application to the lesions every other day. She also was prescribed ketoconazole shampoo and oral fluconazole 100 mg daily for 5 days based on results from a shave biopsy from a post-auricular scalp lesion that showed the presence of *Pityrosporum ovale*. She was advised to continue using topical mupirocin.

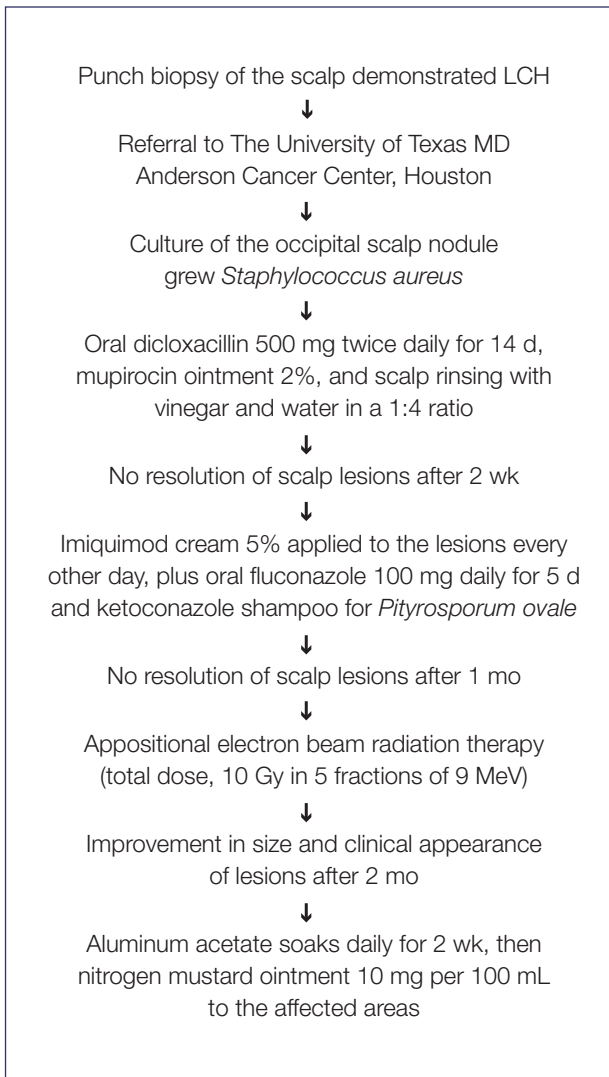
After 1 month of this therapy, the lesions did not show improvement. The patient was sent for local scalp radiation for treatment of LCH. She received appositional electron beam radiation therapy to the 3 affected areas (left parietal, right parietal, and occipital scalp). A total dose of 10 Gy in 5 fractions of 9 MeV was used, which was well-tolerated by the patient. Two months after the radiation therapy, the LCH nodule on the left parietal scalp measured 25×15 mm, and the LCH nodule on the right parietal area measured 37×22 mm (Figure 2A). The ulcers had been replaced by crusted plaques with yellow thick eschar. The lesion on the occipital scalp had remarkably decreased in size and only a pink scar measuring 11×11 mm remained (Figure 2B). Overall the patient improved and was advised to soak the eschars in aluminum acetate daily to remove the crust and apply nitrogen mustard ointment 10 mg per 100 mL to the affected areas after completing 2 weeks of soaks. The treatment course is shown in Figure 3.

The patient's family history included a father with leukemia, a mother with diabetes mellitus and congestive heart failure, and a brother with oral cancer. Her social history did not reveal alcohol or intravenous drug abuse. She had a history of smoking and quit at the time of the LCH diagnosis. Her surgical history included a cholecystectomy, thyroidectomy, cataract surgery, and a femoropopliteal bypass of the lower left extremity. She was not aware of any exposure to hazardous substances. Allergies included sulfonamides, iodine, and tape.



**Figure 2.** Right parietal scalp (A) and occipital scalp (B) 2 months after appositional electron beam radiation therapy.

Her medications included sliding-scale regular insulin, insulin regular, glyburide, atorvastatin calcium, levothyroxine sodium tablets, esomeprazole magnesium delayed-release capsules, clonazepam, nadolol, candesartan cilexetil tablets, doxazosin mesylate, clonidine, tramadol hydrochloride, acetazolamide, dipyridamole, fluoxetine hydrochloride, and cyclosporine ophthalmic emulsion. Her review of systems indicated pruritus of the scalp lesions, fatigue, weight gain, and anxiety. The rest of the review of systems was noncontributory. Laboratory results showed a complete blood cell count within reference range, with a white blood cell count of 10,500/ $\mu$ L (reference range, 4500–11,000/ $\mu$ L) with 63% neutrophils and 1% eosinophils. Immunoglobulin, lactate dehydrogenase, cholesterol, aspartate aminotransferase, alanine aminotransferase, and creatinine levels were within reference range. The thyrotropin level was low at 0.14 mIU/L (reference range, 0.4–4.2 mIU/L), but free thyroxine (FT<sub>4</sub>) was within reference range. Albumin and magnesium levels were mildly decreased at 3.2 g/dL and 1.7 mg/dL, respectively (reference ranges, 3.5–5.0 g/dL and 1.6–2.3 mg/dL, respectively). Epstein-Barr virus serology was compatible with



**Figure 3.** Treatment course for Langerhans cell histiocytosis (LCH) in an adult.

prior infection. A chest radiograph, skeletal survey, and bone scan were reported as negative for findings of LCH.

### Comment

The first case report of a combined basal cell epithelioma and LCH occurred in a 78-year-old man who had been previously treated with radiotherapy for Hodgkin disease.<sup>8,9</sup> The second case of LCH arising at the site of a BCC excision was reported on the shoulder of a 48-year-old woman. The patient had a history of widespread BCCs thought to be secondary to radiotherapy initiated when she was a child for a non-giant hemangioma of the orbit.<sup>10</sup> The third case of combined BCC and localized LCH was described on the scrotum of a 77-year-old man with occupational exposure to coal tar and dust.<sup>11</sup> The scrotum is

a rare site for both BCC and LCH. This case suggests involvement of a carcinogen carried within dust particles in chimney sweeps.<sup>11</sup> Our patient is the fourth case report of localized LCH arising from or in combination with a BCC. The Table presents information on these cases.

The etiology of LCH as a reactive process or true neoplasm remains to be determined. Pathologic cells contain normal DNA, which is support for a reactive process. Two reports show there is no functional abnormality in the Langerhans cell produced from the circulating monocytes of patients with the disease,<sup>10,12</sup> suggesting that LCH may be a defect in T-lymphocyte function.<sup>13</sup> There are many descriptions in the literature of Langerhans cell proliferations triggered by local disturbances in the skin that resolve when the primary disease is controlled.<sup>10</sup> Complex local and systemic cell-cell signaling pathways, which are not fully understood, are known to evoke reactions among cell types. Langerhans cell histiocytosis may, in fact, arise from signals it receives from other cell types.

Alternatively, many individuals support the theory of LCH as a neoplastic process. Some cases of cutaneous LCH show severe cellular atypism with abnormal mitotic figures indicating the clonal expansion of LCH with malignant potential.<sup>14</sup> The observation of clonality in cases of adult LCH gives support to the theory of LCH as a true malignancy.<sup>13</sup> Others have theorized that LCH is considered both a reactive and neoplastic process, and an individual case may fall into either of the 2 forms.<sup>14</sup>

The behavior of LCH remains an important question, as it may help explain why LCH has been found in combination with other skin lesions, such as BCC or melanocytic lesions. One plausible explanation could be that disturbances in the skin (eg, in the form of a neoplastic BCC) bring forth the development of a Langerhans cell response. Local changes in the dermis may actually facilitate the growth of neoplastic clonal cells in the surrounding area.<sup>8</sup> Langerhans cells often populate BCCs, and it has been proposed that the proliferation of the Langerhans cell actually occurs secondary to BCC-induced factors.<sup>9</sup>

There have been cases in the literature showing a strong connection between LCH and other systemic neoplastic processes, such as lymphomas, solid tumors, or leukemias.<sup>15</sup> Reports of LCH occurring in combination with melanocytic nevi also exist and are evidence that LCH may occur adjacently, subadjacently, or concurrently with primary skin lesions and systemic immunologic disease.<sup>8</sup> From the results of our patient's biopsies, it seems as though the Langerhans

Reported Cases of Adults With BCC and LCH of the Skin<sup>a</sup>

Report	Age	Sex	Clinical Presentation	Pertinent Medical History	LCH Involvement	Histology of Lesion
Keen et al, <sup>8</sup> Keen <sup>9</sup>	78	M	Skin lesion reported as a basal cell epithelioma of the back 1 y prior to LCH diagnosis in bone	Hodgkin disease with radiotherapy treatment	Bone and cutaneous LCH	Basal cell epithelioma with adjacent S-100 protein-positive histiocytes
Simonart et al <sup>10</sup>	48	F	2 mo after surgical excision of a BCC on the right shoulder, an ulcerated nodule in the area showed LCH	Multiple and relapsing BCCs; radiotherapy as a child for a non-giant hemangioma of the orbit	Localized cutaneous LCH	Histiocyticleike cells infiltrating the papillary dermis and the epidermis found to be highly reactive to S-100 protein and CD1a antigen; no concurrent BCC
Izikson et al <sup>11</sup>	77	M	Clinically suspected BCC on scrotum treated with cryotherapy; tumor recurred as a gray variegated lesion with crusted bloody scale and necrosis	Multiple prior BCCs on waistline; asbestos pleural disease; exposure to coal tar and dust, machine oil, refinery waste, sulfur waste, asbestos, and hydraulic fluid	Localized cutaneous LCH	Nodular BCC surrounded by a cellular proliferation of round histiocytic cells and numerous eosinophils; histiocytes reactive to S-100 and CD1a antigens
Current report	63	F	Crusted nodules on the scalp that showed BCC; recurrence of nodules showed LCH	Multiple BCCs of the forehead, Sjögren syndrome, thyroid cancer status post-excision and radioactive iodine therapy	Localized cutaneous LCH	Numerous Langerhans cells in the dermis and epidermis reactive to CD1a antigen, supporting the diagnosis of LCH; no concurrent BCC

Abbreviations: BCC, basal cell carcinoma; LCH, Langerhans cell histiocytosis; M, male; F, female.

<sup>a</sup>A PubMed search of articles indexed for MEDLINE using the terms *adult Langerhans cell histiocytosis* and *adult histiocytosis of basal cell carcinoma*.

cells actually replaced the preexisting BCC. In this case, one could argue that Langerhans cells may react toward a BCC and proliferate in numbers large enough to either mask or replace existing cells.

In a study looking at the morphology of Langerhans cells in BCC tumors compared with Langerhans cells found in perilesional skin of patients, a predominance of less dendritic and more rounded Langerhans cells were found in the

BCC tumor itself.<sup>16</sup> The density of Langerhans cells, however, was similar, which raises the possibility that changes brought on by the BCC tumor cells may affect Langerhans cell morphology, function, and perhaps behavior. On the other hand, it could be argued that BCCs may arise in areas where the morphology of the Langerhans immune cells has been altered.<sup>16,17</sup>

Basal cell carcinomas are more common than LCH; therefore, it is possible that the BCCs in

our patient may have arisen prior to LCH purely by coincidence. However, the presentation of several BCCs and LCH over a short time as well as histologic change from a BCC to LCH in the same lesion over time make this theory highly unlikely. In addition, although our patient was white, her fair skin did not show any other signs of sun damage (ie, actinic keratosis, heavy wrinkling, poikiloderma, solar lentiginos) and she did not have a history of BCCs to suggest that she is prone to developing such lesions. Therefore, the presence of BCC and LCH, based on our patient's clinical course, seems to follow a reactive process rather than a malignant process.

It is unclear if the LCH in this patient developed as a reaction to the BCC, or if the BCCs, although appearing first, arose as a reaction to the developing LCH. The chemical mediators that induce the migration and maturation of monocytes into tissues such as the skin is not yet completely understood but involves a set of complicated chemokines and mediators, such as monocyte chemoattractant protein-1, IL-1, granulocyte-macrophage colony-stimulating factor, tumor necrosis factor  $\alpha$ , and IFN- $\beta$ .<sup>18</sup> It is quite possible that these mediators activate other nearby cells in the skin, causing combinations of lesions and changes in whole cell populations, as seen in this case.

## REFERENCES

1. Hancox JG, James AP, Madden C, et al. Adult onset folliculocentric langerhans cell histiocytosis confined to the scalp. *Am J Dermatopathol*. 2004;26:123-126.
2. Stocksclaeder M, Sucker C. Adult Langerhans cell histiocytosis. *Eur J Haematol*. 2006;76:363-368.
3. Singh A, Prieto VG, Czelusta A, et al. Adult Langerhans cell histiocytosis limited to the skin. *Dermatology*. 2003;207:157-161.
4. Jain S, Sehgal VN, Bajaj P. Nail changes in Langerhans cell histiocytosis. *J Eur Acad Dermatol Venereol*. 2000;14:212-215.
5. Conias S, Strutton G, Stephenson G. Adult cutaneous Langerhans cell histiocytosis. *Australas J Dermatol*. 1998;59:106-108.
6. Behrens RJ, Levi AW, Westra WH, et al. Langerhans cell histiocytosis of the thyroid: a report of two cases and review of the literature. *Thyroid*. 2001;11:697-705.
7. Guitart J, Micali G, Norton S. A young adult with a recalcitrant scalp folliculitis: Langerhans' cell histiocytosis (LCDH) presenting as scalp folliculitis in an adult. *Arch Dermatol*. 1995;131:719-720, 722-723.
8. Keen CE, Philip G, Parker BC, et al. Unusual bony lesions of histiocytosis X in a patient previously treated for Hodgkin's disease. *Pathol Res Pract*. 1990;186:519-525.
9. Keen CE. Combined skin lesions. *Am J Dermatopathol*. 1996;18:527-532.
10. Simonart T, Urbain F, Verdebout JM, et al. Langerhans' cell histiocytosis arising at the site of basal cell carcinoma excision. *J Cutan Pathol*. 2000;27:476-478.
11. Izikson L, Vanderpool J, Brodsky G, et al. Combined basal cell carcinoma and Langerhans cell histiocytosis of the scrotum in a patient with occupational exposure to coal tar and dust. *Int J Dermatol*. 2004;43:678-680.
12. Holter W, Ressmann G, Grois N, et al. Normal monocyte-derived dendritic function in patients with Langerhans-cell-histiocytosis. *Med Pediatr Oncol*. 2002;39:181-186.
13. Aricò M. Langerhans cell histiocytosis in adults: more questions than answers? *Eur J Cancer*. 2004;40:1467-1473.
14. Shinmi K, Nagai Y, Matsushima Y, et al. Adult case of Langerhans cell histiocytosis. *J Dermatol*. 2007;34:275-277.
15. Egeler RM, Neglia JP, Aricò M, et al. The relation of Langerhans' cell histiocytosis to acute leukemia, lymphomas, and other solid tumors. the LCH-Malignancy Study Group of the Histiocyte Society. *Hematol Oncol Clin North Am*. 1998;12:369-378.
16. Bergfelt L, Larkö O, Lindberg M. Density and morphology of Langerhans cells in basal cell carcinomas of the face and trunk. *Br J Dermatol*. 1992;127:575-579.
17. Azizi E, Bucana C, Goldber L, et al. Perturbation of epidermal Langerhans' cells in basal cell carcinomas. *Am J Dermatopathol*. 1981;9:465-473.
18. Newman B, Hu W, Nigro K, et al. Aggressive histiocytic disorders that can involve the skin. *J Am Acad Dermatol*. 2007;56:302-316.

### DISCLAIMER

The opinions expressed herein are those of the authors and do not necessarily represent the views of the sponsor or its publisher. Please review complete prescribing information of specific drugs or combination of drugs, including indications, contraindications, warnings, and adverse effects before administering pharmacologic therapy to patients.

### CONFLICT OF INTEREST STATEMENT

The Conflict of Interest Disclosure Policy of Albert Einstein College of Medicine requires that authors participating in any CME activity disclose to the audience any relationship(s) with a pharmaceutical or equipment company. Any author whose disclosed relationships prove to create a conflict of interest, with regard to their contribution to the activity, will not be permitted to present.

The Albert Einstein College of Medicine also requires that faculty participating in any CME activity disclose to the audience when discussing any unlabeled or investigational use of any commercial product, or device, not yet approved for use in the United States.