

# Oral Mucosal Melanoma of the Mandibular Gingiva: A Case Report

Silvia Vanessa Lourenço, DDS, PhD; Sheyla Batista Bologna, DDS; Fabiana Colucci, MD; Cyro Festa Neto, MD, PhD; Fábio L. M. Montenegro, MD, PhD; Marcello Menta S. Nico, MD, PhD

*Oral mucosal melanoma is rare and is reported to be more aggressive than cutaneous melanoma. The incidence of oral mucosal melanoma peaks at 41 to 60 years of age and the male to female ratio is 2 to 1. Preferred sites in the oral mucosa include the hard palate and maxillary alveolar crests. Risk factors have not been clearly identified, but melanotic pigmentation is present in one-third of patients prior to the diagnosis of melanoma. We report an unusual case of oral mucosal melanoma of the mandibular gingiva with the main characteristics of an in situ lesion and areas of superficial invasion in a 45-year-old woman. The patient was treated with surgical resection of the lesion and a 54-month follow-up shows no evidence of recurrence. Oral mucosal melanomas are aggressive neoplasms that may arise from prior pigmented lesions in the oral mucosa. Classification of these tumors is not well-established and the main prognostic factor appears to be lymph node compromise. The main treatment modality is surgical resection.*

*Cutis.* 2010;86:89-93.

**P**rimarily malignant melanoma has been described in virtually all sites and organ systems that neural crest cells migrate. More than 90% of melanomas occur on the skin with slightly

more than 1% of melanomas arising from mucosal surfaces. Oral mucosal melanoma is extremely rare, accounting for only 0.5% of oral malignancies.<sup>1-4</sup>

The incidence of oral mucosal melanoma peaks at 41 to 60 years of age and the male to female ratio is 2 to 1.<sup>5,6</sup> Preferred sites in the oral mucosa include the hard palate and maxillary alveolar crests. Risk factors have not been clearly identified, but melanotic pigmentation is present in one-third of patients prior to the diagnosis of melanoma.<sup>7-9</sup>

Oral mucosal melanomas are reported to be more aggressive than cutaneous melanomas; however, it is unknown if the worse prognosis of oral mucosal melanoma is attributed to differences in its histologic behavior, or if late diagnosis or anatomic features are determinant of the prognosis.<sup>10</sup> Additionally, there is no well-defined clinical and histologic classification for oral mucosal melanoma; the majority of information is based on case series because of the rarity of the lesion.<sup>7</sup>

We report an unusual case of oral mucosal melanoma of the mandibular gingiva with the main characteristics of an in situ lesion and areas of superficial invasion.

## Case Report

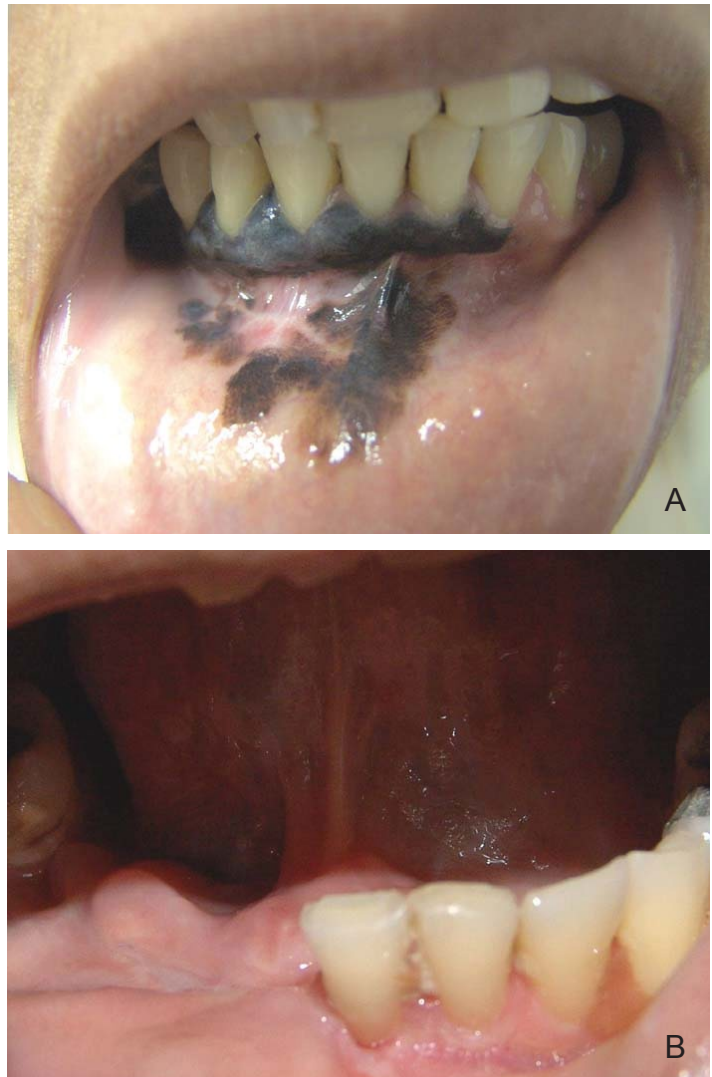A 45-year-old woman (Fitzpatrick skin type V) reported a black spot on the gingiva of the lower jaw of 15 years' duration. She noticed the lesion had progressively increased in size in the last 2 years. The patient denied smoking and/or alcoholism. Clinical examination revealed a large, black, irregular macula on the vestibular and lingual anterior mandibular gingiva extending to the vestibular sulcus and inferior labial mucosa (Figure 1A). An incision biopsy was performed with the hypothesis of oral mucosal melanoma. Histopathologic analysis with hematoxylin and eosin stain revealed a melanoma in situ of the gingival mucosa. Computed tomography and cervical ultrasound showed no abnormalities in the parotid gland, thyroid

---

Drs. Lourenço and Batista Bologna are from the Department of General Pathology, Dental School, and Drs. Festa Neto and Nico are from the Department of Dermatology, all at the School of Medicine, University of São Paulo, Brazil. Dr. Colucci is from private practice, São Paulo. Dr. Montenegro is from the Department of Head and Neck Surgery, Hospital das Clínicas, School of Medicine, University of São Paulo.

The authors report no conflict of interest.

Correspondence: Silvia Vanessa Lourenço, DDS, PhD, Dental School, University of São Paulo, Av Prof Lineu Prestes, 2227 Cidade Universitária, São Paulo CEP: 05508-000, São Paulo, Brazil (silvialourenco.70@terra.com.br).



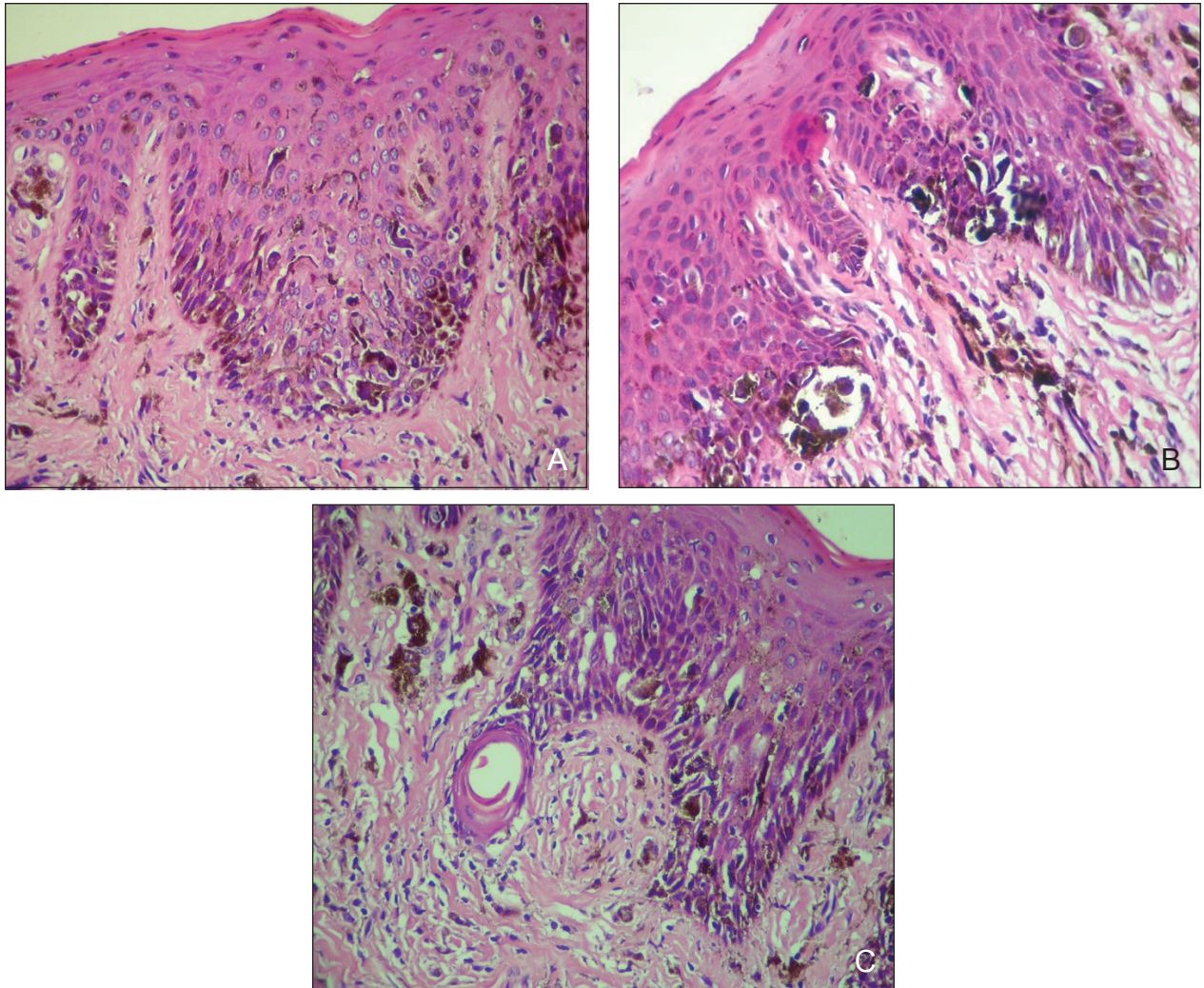
**Figure 1.** Clinical aspect of oral mucosal melanoma, including a large, black, irregular lesion extending from the anterior mandibular gingiva (vestibular and lingual) to the vestibular sulcus and labial mucosa (A). Four months after surgical excision, there was no evidence of recurrence or local and regional metastasis (B).

gland, and lymph nodes. Additional investigation revealed no distant metastasis. Treatment was performed by tumor excision with a marginal mandibulectomy and extraction of 4 inferior teeth (right inferior incisor, canine, first premolar, and second premolar). Resection margins were 1.5 cm from the pigmented area. Histopathologic analysis of serial sections of the surgical specimen revealed, for the most part, melanoma in situ with junctional activity and intraepithelial nests of neoplastic atypical melanocytes. Neoplastic melanocytes also were seen in the superior strata of the epithelium and some dendritic melanocytes also could be observed. Multiple foci of invasive malignant melanoma also were present in the superficial portion of the lamina propria (measuring <1 mm). The presence of invasion was confirmed by melanocytes positive for melan-A protein on immunohistochemistry, which

was present in the epithelium and lamina propria. Angiolymphatic and perineural invasion were not detected. Histopathologic aspects are illustrated in Figure 2. Melanoma in situ was detected in the surgical lateral margins. Surgical margins were widened and additional bilateral resection of cervical lymph nodes was performed. No adjuvant therapy was undertaken. After 4 months of close follow-up, there was no evidence of recurrence or local and regional metastasis (Figure 1B). At 54 months of follow-up, no recurrence was observed.

#### Comment

Primary oral mucosal melanomas are rare lesions comprising 0.2% to 8.0% of all melanomas and 0.5% of all malignancies.<sup>11-13</sup> We report a case of oral mucosal melanoma still in its early stages of invasion. In agreement with epidemiologic



**Figure 2.** Histologic aspects of oral mucosal melanoma included a neoplastic proliferation of melanocytes within the covering epithelium and pigment incontinence in the lamina propria with presence of melanophages. Neoplastic melanocytes were present in the upper layers of the epithelium (A)(H&E, original magnification  $\times 200$ ). Aspects of areas of melanoma in situ included intraepithelial proliferation of neoplastic melanocytes and evidence of junctional activity. Neoplastic melanocytes also were seen in the superior strata of the epithelium and some dendritic melanocytes also were observed (B and C)(H&E, original magnification  $\times 200$  for both).

reports stating that oral melanoma is more prevalent in males with a wide age range, the present case showed compromise of the lower gingiva in a woman in the fifth decade of life. The palate and maxillary gingiva are the preponderant sites affected by primary oral mucosal melanomas; the buccal mucosa, lips, and mandibular gingiva, as reported herein, are the least involved sites, according to the literature.<sup>11,14</sup>

Oral melanoma is widely reported to be more aggressive than cutaneous melanoma, with most reported cases presenting as nodular lesions with a vertical growth phase or both an invasive and in situ pattern.<sup>3</sup> Our case represents a lesion that

is still in its initial phase of invasion, and on histologic examination, the presence of junctional activity and transmucosal migration are some of the features favoring a diagnosis of a primary oral mucosal melanoma. These features are important prognostic factors when analyzing oral melanomas, though there is no consensus on prognostic features in the English-language literature.

While cutaneous melanomas are divided into clinically and pathologically well-established varieties, definitive classification of oral mucosal melanoma is not available.<sup>15,16</sup> The workshop on oral malignant melanomas that convened at the annual meeting of the Western Society of Teachers of



Oral Pathology in 1995 established that oral lesions should be classified separate from cutaneous forms, and the terms *in situ oral malignant melanoma*, *invasive oral malignant melanoma*, and *atypical melanocytic proliferation* (for an equivocal lesion) were considered appropriate to refer to oral lesions.<sup>17</sup> Additionally, in view of the histologic differences between oral and cutaneous melanoma, it is impossible to apply Breslow and Clark classifications to the former for prognosis.<sup>18,19</sup>

In general, prognostic factors for poor survival include location of the primary tumor, stage at presentation, thickness greater than 5 mm, presence or absence of vascular invasion, and development of nodal and distant metastases.<sup>4,20-22</sup> However, it has been shown that tumor thickness, vascular invasion, and necrosis have no remarkable influence on survival.<sup>23</sup> Increased tumor thickness, depth, and the vertical growth phase of the tumor at diagnosis also are related to poor prognosis.<sup>4,13</sup> Presumably, in our case the predominant superficial spreading characteristic may be decisive in the patient's longevity, but we cannot determine it with a follow-up of only 54 months.

Controversy surrounds the role of melanosis that existed prior to the development of oral mucosal melanoma, but anecdotal reports on possible transformation of benign oral pigmentation to primary oral mucosal melanoma exists.<sup>4,9</sup> In our case, according to the patient's clinical history, a pigmented spot with 15 years of evolution existed prior to the onset of melanoma. This information may indicate that a pigmented lesion with transformed melanocytes and very slow growth rate could have been present prior to the present diagnosis, yet the literature states that more than one-third of oral mucosal melanomas develop from melanotic lesions that might host the neoplastic radial growth phase many months before the diagnosis of melanoma.<sup>7</sup>

The reported prognosis of oral mucosal melanoma is poor, with a 5-year survival rate of 0% to 55%.<sup>22</sup> Median survival for all oral mucosal melanomas is slightly over 2 years from the time of diagnosis,<sup>13</sup> which depends on the presence or absence of lymph node involvement (18 months vs 46 months).<sup>11</sup> In our patient, because there was no lymph node compromise or metastasis and the patient was under a close follow-up, we expect a better survival rate.

The main treatment modality is surgical resection, which offers the best chance for long-term survival.<sup>4,7,24,25</sup> Rapidis et al<sup>11</sup> affirm that excision of the tumor has to be performed with a surgical margin of 1.5 to 2 cm of free tissue of the microscopic lesion. Treatment with topical imiquimod for multifocal intraepithelial melanoma of the oral

mucosa as an adjuvant therapy after surgery and chemotherapy has been described with some rate of success.<sup>26</sup> This treatment modality may be an alternative for patients with multifocal superficial disease who cannot undergo complete resection. However, due to the scarcity of reported cases, its real effectiveness remains to be established.

*Acknowledgments*—Fundação de Amparo à Pesquisa do Estado de São Paulo grant 06/56625-5 and 07/50319-2.

## REFERENCES

- Allen AC, Spitz S. Malignant melanoma: clinicopathologic analysis of the criteria for diagnosis and prognosis. *Cancer*. 1953;6:1-45.
- Chang AE, Karnell LH, Mench HR. The National Cancer Data Base report on cutaneous and noncutaneous melanoma: a summary of 84,836 cases from past decade. The American College of Surgeons Commission on Cancer and the American Cancer Society. *Cancer*. 1998;83:1664-1678.
- Hicks MJ, Flaitz CM. Oral mucosal melanoma: epidemiology and pathobiology. *Oral Oncol*. 2000;36:152-169.
- Garzino-Demo P, Fasolis M, Maggioro GM, et al. Oral mucosal melanoma: a series of case reports. *J Craniomaxillofac Surg*. 2004;32:251-257.
- Regezi JA, Hayward JR, Pickens TN. Superficial melanomas of oral mucous membranes. *Oral Surg Oral Med Oral Pathol*. 1978;45:730-740.
- Manolidis S, Donald PJ. Malignant mucosal melanoma of the head and neck: review of the literature and report of 14 patients. *Cancer*. 1997;80:1373-1386.
- Rapini RP, Golitz LE, Greer RO Jr, et al. Primary malignant melanoma of the oral cavity. a review of 177 cases. *Cancer*. 1985;55:1543-1551.
- Batsakis JG, Suarez P, El-Naggar AK. Mucosal melanomas of the head and neck. *Ann Otol Rhinol Laryngol*. 1998;107:626-630.
- Kahn MA, Weathers DR, Hoffman JG. Transformation of a benign oral pigmentation to primary oral melanoma. *Oral Surg Oral Med Oral Pathol Oral Radiol Endod*. 2005;100:454-459.
- González-García R, Naval Gias L, Martos PL, et al. Melanoma of the oral mucosa. clinical cases and review of the literature. *Med Oral Patol Oral Cir Bucal*. 2005;10:264-271.
- Rapidis AD, Apostolidis C, Vilos G, et al. Primary malignant melanoma of the oral mucosa. *J Oral Maxillofac Surg*. 2003;61:1132-1139.
- Lopez-Graniel CM, Ochoa-Carrillo FJ, Meneses-Garcia A. malignant melanoma of the oral cavity: diagnosis and treatment experience in a Mexican population. *Oral Oncol*. 1999;35:425-430.
- Chidzonga MM, Mahomva L, Marimo C, et al. Primary malignant melanoma of the oral mucosa. *J Oral Maxillofac Surg*. 2007;65:1117-1120.

14. Batsakis JG, Suarez P. Mucosal melanomas: a review. *Adv Anat Pathol*. 2000;7:167-180.
15. Barnhill RL, Mihm MC Jr. The histopathology of cutaneous malignant melanoma. *Semin Diagn Pathol*. 1993;10:47-75.
16. McGovern VJ, Mihm MC Jr, Bailly C, et al. The classification of malignant melanoma and its histologic reporting. *Cancer*. 1973;32:1446-1457.
17. Barker BF, Carpenter WM, Daniels TE, et al. Oral mucosal melanomas: the WESTOP Banff workshop proceedings. Western Society of Teachers of Oral Pathology. *Oral Surg Oral Med Oral Pathol Oral Radiol Endod*. 1997;83:672-679.
18. Breslow A. Thickness, cross-sectional areas and depth of invasion in the prognosis of cutaneous melanoma. *Ann Surg*. 1970;172:902-908.
19. Clark WH Jr, Ainsworth AM, Bernardino EA, et al. The developmental biology of primary human malignant melanomas. *Semin Oncol*. 1975;2:83-103.
20. Patel SG, Prasad ML, Escrig M, et al. Primary mucosal malignant melanoma of the head and neck. *Head Neck*. 2002;24:247-257.
21. Gu GM, Epstein JB, Morton TH Jr. Intraoral melanoma: long-term follow-up and implication for dental clinicians. a case report and literature review. *Oral Surg Oral Med Oral Pathol Oral Radiol Endod*. 2003;96:404-413.
22. Mendenhall WM, Amdur RJ, Hinerman RW, et al. Head and neck mucosal melanoma. *Am J Clin Oncol*. 2005;28:626-630.
23. Prasad ML, Patel SG, Huvos AG, et al. Primary mucosal melanoma of the head and neck: a proposal for micro-staging localized, stage I (lymph node-negative) tumors. *Cancer*. 2004;100:1657-1664.
24. van der Waal RI, Snow GB, Karim AB, et al. Primary malignant melanoma of the oral cavity: a review of eight cases. *Br Dent J*. 1994;176:185-188.
25. Medina JE, Ferlito A, Pellitteri PK, et al. Current management of mucosal melanoma of the head and neck. *J Surg Oncol*. 2003;83:116-122.
26. Spieth K, Kovács A, Wolter M, et al. Topical imiquimod: effectiveness in intraepithelial melanoma of oral mucosa. *Lancet Oncol*. 2006;7:1036-1037.