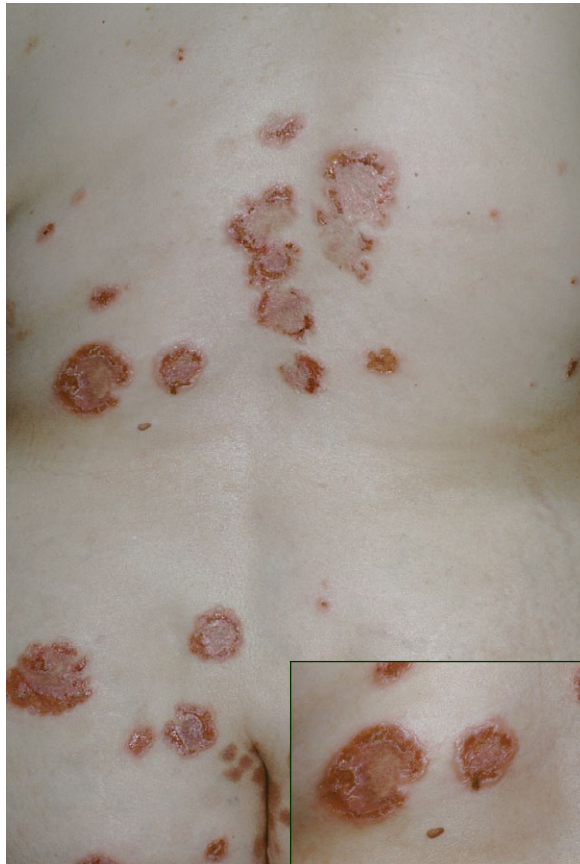

## What Is Your Diagnosis?



A 50-year-old white woman presented to the dermatology clinic with a pruritic bullous eruption involving the head, trunk, and extremities. Her medical history was remarkable for asthma, scoliosis, osteoporosis, migraines, gastroesophageal reflux disease, and deep vein thrombosis status post–Greenfield filter placement. Family history was noncontributory. Medications at presentation included morphine, oxycodone and acetaminophen tablets, cisapride, fentanyl patch, gabapentin, omeprazole delayed-release capsules, theophylline anhydrous, and multivitamins. A biopsy specimen from a skin lesion revealed a subepidermal bulla with neutrophils.

PLEASE TURN TO PAGE 125 FOR DISCUSSION

---

Mark N. Schwendiman, DO, San Antonio Uniformed Services Health Education Consortium, Texas.

George W. Turiansky, MD, Uniformed Services University of the Health Sciences, Bethesda, Maryland; Dermatology Service, Walter Reed Army Medical Center, Washington, DC; and Dermatology Department, National Naval Medical Center, Bethesda. The authors report no conflict of interest.

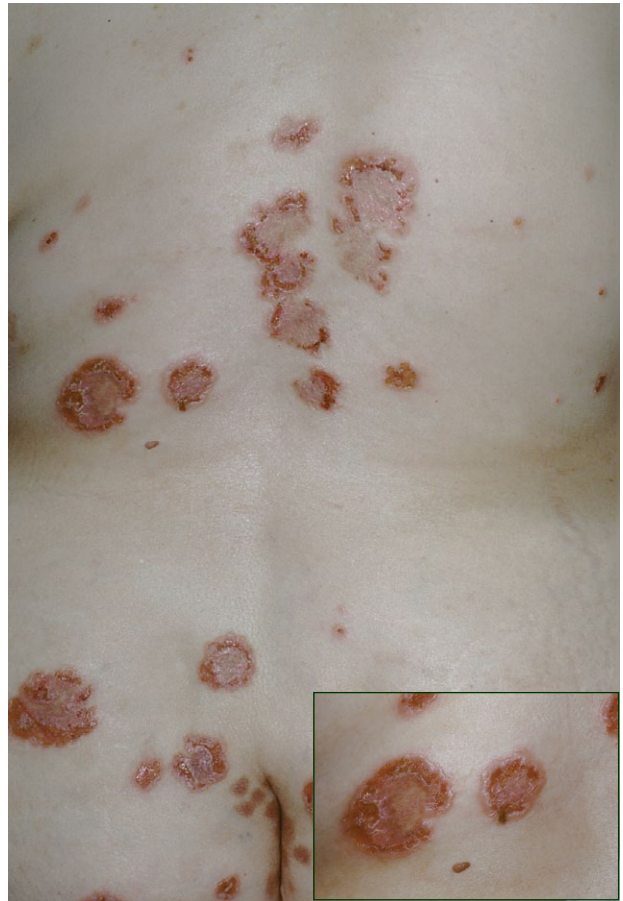The opinions expressed in this article are those of the authors and do not represent the viewpoints of the US Army or the US Department of Defense.

## The Diagnosis: Linear IgA Dermatitis

**L**inear IgA dermatosis (LAD) is an autoimmune subepidermal blistering skin disease characterized by the presence of linear deposits of IgA at the dermoepidermal junction. Also known as linear IgA bullous dermatosis, LAD has an idiopathic, waxing and waning presentation in most patients<sup>1</sup>; however, a drug-induced pathogenesis has been described. Both adults and children are affected. Childhood disease is known as chronic bullous disease of childhood (CBDC), which often appears before the age of 5 years, while LAD frequently appears after the age of 60 years.<sup>1</sup>

The most common clinical presentation of LAD involves a combination of tense vesicles and bullae, grouped papules, erythematous patches, and erosions. Classically LAD has a crown of jewels or string of pearls presentation, which refers to the presence of circumferential vesicles or bullae around the edges of the lesions. The eruption may be pruritic and occurs predominantly on the trunk; extremities, including the extensor surfaces such as the elbows and knees; and the buttocks (Figure 1). Mucosal involvement is fairly common and may be as high as 80% in idiopathic cases and 40% to 45% in drug-induced cases.<sup>1,2</sup> Two cases of LAD initially presenting as ulcerative lesions in the larynx and pharynx have been reported. One case progressed to partial airway stenosis requiring tracheostomy with eventual fatality due to tracheostomy complications.<sup>3</sup> Cutaneous findings of drug-induced LAD are similar to idiopathic LAD and also have substantial variability to include bullous, urticarial, erythematous, and targetoid erythema multiforme–like lesions that often favor the trunk and extremities, including the palms and soles, while sparing the head and neck.<sup>4</sup>

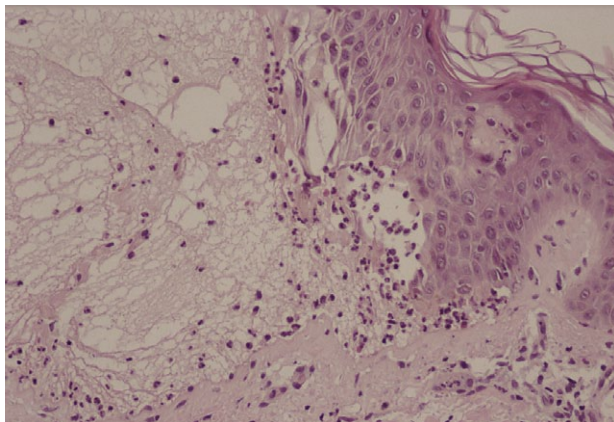
The diagnosis can be confirmed with a skin biopsy and direct immunofluorescence (DIF) testing of perilesional skin. Histopathology reveals subepidermal blisters and basal cell vacuolization with a predominantly neutrophilic infiltrate in the dermal papillae (Figure 2). Direct immunofluorescence testing reveals linear deposition of IgA at the dermoepidermal junction (Figure 3). IgG and C3 deposition infrequently are found at the basement membrane zone (BMZ).<sup>5,6</sup> Indirect immunofluorescence occasionally yields serum IgA anti-BMZ antibodies and may be useful for differentiating between various subepidermal blistering disorders. In a study of 24 patients with various IgA deposition disorders, use of the salt-split skin technique for performing indirect immunofluorescence (incubation of skin in



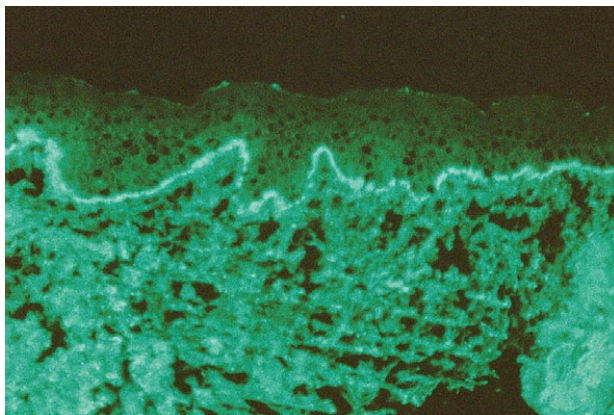
**Figure 1.** Round, crusted, erythematous patches and plaques. In the inset photograph, vesicles and bullae were demonstrated at the periphery of the skin lesions.

1 mol/L sodium chloride results in a split in the lamina lucida) increased the rate of detecting IgA anti-BMZ antibodies (41% vs 64% for intact skin and salt-split skin, respectively).<sup>7</sup>

A heterogeneous group of antigens localized to the BMZ has been implicated in the etiology of LAD.<sup>8</sup> Multiple target antigens for the IgA autoantibodies of LAD exist and most commonly include the 97 kD ectodomain of the hemidesmosomal transmembrane glycoprotein BP180 antigen (type XVII collagen) and the 120 kD secreted portion of the BP180 antigen (LAD-1 [linear IgA dermatosis autoantigen]).<sup>9,10</sup> Occasionally, autoantibodies also target a 285 kD antigen identified in the lamina lucida and the sublamina densa, but this antigen has yet to be further characterized.<sup>11</sup> Various antigenic sites on the extracellular domain of BP180 have been shown to be targeted by autoantibodies in



**Figure 2.** Subepidermal bulla with neutrophils (H&E, original magnification  $\times 200$ ).



**Figure 3.** Direct immunofluorescence of perilesional skin showed strong linear IgA at the basement membrane zone (original magnification  $\times 100$ ).

other autoimmune bullous skin diseases, including bullous pemphigoid and cicatricial pemphigoid.<sup>12</sup> One study found LAD and CBDC was highly associated with HLA haplotypes Cw7, B8, and DR3, while possession of HLA-B8, DR3, and DQ2 perhaps facilitated earlier presentation of the disease.<sup>13</sup> HLA-B8 appears more frequently in patients with CBDC than LAD.<sup>1</sup>

While the majority of LAD cases are idiopathic, drug-induced cases are increasing in frequency. Drug-induced LAD is associated most frequently with vancomycin, though other commonly associated medications include penicillin, cephalosporin, and captopril. Other implicated medications include diclofenac, naproxen, amiodarone hydrochloride, atorvastatin calcium, lithium, cefamandole nafate, phenytoin, and somatostatin.<sup>14,15</sup>

The differential diagnosis of LAD includes multiple blistering disorders such as dermatitis herpetiformis (DH), bullous pemphigoid, epidermolysis bullosa acquisita, cicatricial pemphigoid, bullous

systemic lupus erythematosus (SLE), erythema multiforme, and bullous drug reactions such as Stevens-Johnson syndrome. These diseases can be confirmed by lesional skin biopsies for hematoxylin and eosin staining and perilesional skin biopsies for DIF studies. Elicitation of a complete history of drug use including herbal and over-the-counter drugs as well as temporal history precludes the diagnosis of drug-induced LAD and other bullous drug reactions.

The cutaneous presentation of DH may be identical to LAD; therefore, DIF is required to differentiate the two. While LAD typically has a linear IgA deposition along the BMZ in the perilesional skin biopsy, DH commonly has nonuniform or granular IgA deposition in the dermal papillary tips.<sup>16</sup> Additionally, DH often yields both a rash and enteropathy that are gluten dependent, whereas LAD does not.<sup>17</sup> Serum of DH patients reveals antiendomysial antibodies. Evidence exists demonstrating that there is no tissue transglutaminase in the sera of patients with LAD, while sera of patients with DH contains transglutaminase.<sup>18,19</sup>

Bullous pemphigoid is characterized by tense blisters usually arising on normal-appearing skin and is differentiated from LAD by the presence of linear deposits of IgG and/or C3 in the BMZ.<sup>20</sup> Indirect immunofluorescence testing reveals that the autoantibodies causing bullous pemphigoid target a 230 kD protein (BPAg1) within the hemidesmosomes along with a transmembranous 180 kD protein (BPAg2).<sup>21</sup>

Epidermolysis bullosa acquisita presents with a subepidermal blister and is characterized by linear deposition of IgG at the BMZ. Indirect immunofluorescence testing of sera from epidermolysis bullosa acquisita patients reveal the presence of autoantibodies against type VII collagen.<sup>22</sup>

Cicatricial pemphigoid is a blistering disorder often presenting in the mouth, oropharynx, and rarely the nasopharyngeal or rectal mucosae, which frequently leads to scarring. Ocular involvement ultimately may lead to blindness. The autoantibodies in cicatricial pemphigoid are directed against BP180, laminin 5, and type VII collagen.<sup>23,24</sup>

Bullous SLE presents with vesiculobullous skin lesions, often in sun-exposed areas. Patients must have criteria for the diagnosis of SLE. The DIF may be positive for IgG, IgM, or IgA at the BMZ. The autoantibodies in bullous SLE disease recognize the major anchoring fibril component type VII collagen.<sup>22</sup>

Bullous lesions may be seen with erythema multiforme minor. The eruption of bullous erythema multiforme consists of erythematous to dusky-colored macules, papules, and bullae that form targetlike lesions in a symmetrical fashion. Erythema multiforme



minor usually is associated with preceding orolabial herpes simplex virus infection.

Bullous lesions occur with Stevens-Johnson syndrome, which is a disease often associated with antibiotics such as sulfonamides or penicillin as well as anticonvulsant agents such as phenytoin or carbamazepine, nonsteroidal anti-inflammatory drugs, allopurinol, nevirapine, and corticosteroids.<sup>25,26</sup>

While nonidiopathic LAD most frequently has been associated with drugs, associations with systemic diseases also exist. Acquired LAD has presented in patients diagnosed with ulcerative colitis. Authors of one report speculated that foreign antigens penetrating the inflamed bowel mucosa might encourage the production of autoantibodies involved in the pathogenesis of LAD.<sup>27</sup> Another literature review discussed a possible association of LAD with Hodgkin lymphoma.<sup>28</sup> One report documented LAD improvement during pregnancy, enabling therapy to be reduced or stopped. However, most patients had a relapse approximately 3 months postpartum.<sup>29</sup>

Dapsone generally is accepted as the drug of choice for the treatment of LAD and CBDC. Most patients will respond to a daily dosage of 100 to 150 mg of dapsone with improvement of the skin lesions within 24 to 48 hours. The dosage gradually may be lowered to a maintenance level of 50 mg every other day. Some patients might require long-term therapy. The potential exists for dapsone to cause hemolytic anemia, decreased hemoglobin values, or even methemoglobinemia, which can occur with or without glucose-6-phosphate dehydrogenase deficiency. Glucose-6-phosphate dehydrogenase deficiency status needs to be established prior to initiating treatment. Clinical symptoms of methemoglobinemia are shortness of breath, cyanosis, mental status changes, lethargy, and arrhythmias or seizures. Dapsone also might induce agranulocytosis, hepatitis, or peripheral neuropathy, which is primarily a motor neuropathy, but the neuropathy also can be sensory or mixed. Dapsone therapy requires a baseline complete blood cell count. Complete blood cell count with differential is then taken every week for 4 weeks, then every 2 weeks until week 12, and then every 3 to 4 months thereafter. Liver function tests and renal function tests are needed at baseline and then every 3 to 4 months.<sup>30</sup> Sulfapyridine 250 to 500 mg administered 3 times daily generally is considered an acceptable alternative treatment. One study showed that flucloxacillin may be considered among the first alternative therapies for CBDC, especially when there is a baseline glucose-6-phosphate dehydrogenase deficiency present.<sup>31</sup> Drug-induced LAD is treated by immediately discontinuing the offending drug. Typically, new lesions cease to form 24 to

72 hours after discontinuation of the medication and the remaining lesions often resolve within 2 to 7 weeks.<sup>32</sup> Drug-induced LAD has a better prognosis because of resolution of skin disease with cessation of the causative drug, while idiopathic LAD may be chronic. Spontaneous resolution may occur in LAD; however, one study demonstrated that remission occurred in only 64% (16/25) of patients with CBDC and 48% (12/25) of patients with LAD.<sup>1</sup> The remainder of patients will have lifelong relapsing and remitting symptoms.

## REFERENCES

1. Wojnarowska F, Marsden RA, Bhogal C, et al. Chronic bullous disease of childhood, childhood cicatricial pemphigoid, and linear IgA disease of adults: a comparative study demonstrating clinical and immunopathologic overlap. *J Am Acad Dermatol.* 1988;19(5, pt 1):792-805.
2. Palmer RA, Ogg G, Allen J, et al. Vancomycin-induced linear IgA disease with autoantibodies to BP180 and LAD285. *Br J Dermatol.* 2001;145:816-820.
3. Sato K, Hanazawa H, Sato Y, et al. Initial presentation and fatal complications of linear IgA bullous dermatosis in the larynx and pharynx. *J Laryngol Otol.* 2005;119:314-318.
4. Collier PM, Wojnarowska F. Drug-induced linear immunoglobulin A disease. *Clin Dermatol.* 1993;11:529-533.
5. Neugebauer BI, Negron G, Pelton S, et al. Bullous skin disease: an unusual allergic reaction to vancomycin. *Am J Med Sci.* 2002;323:273-278.
6. Nousari HC, Kimyai-Asadi A, Caeiro JP, et al. Clinical, demographic, and immunohistologic features of vancomycin-induced linear IgA bullous disease of the skin: report of 2 cases and review of the literature. *Medicine (Baltimore).* 1999;78:1-8.
7. Weng MW, Qiu BS, Kang KF. An analysis of 24 patients with IgA deposition at the BMZ. *J Dermatol.* 1993;20:276-278.
8. Navi D, Michael DJ, Fazel N. Drug-induced linear IgA bullous dermatosis. *Dermatol Online J.* 2006;12:12.
9. Zone JJ, Taylor TB, Kadunce DP, et al. Identification of the cutaneous basement membrane zone antigen and isolation of antibody in linear immunoglobulin A bullous dermatosis. *J Clin Invest.* 1990;85:812-820.
10. Marinkovich MP, Taylor TB, Keene DR, et al. LAD-1, the linear IgA bullous dermatosis autoantigen, is a novel 120-kDa anchoring filament protein synthesized by epidermal cells. *J Invest Dermatol.* 1996;106:734-738.
11. Wojnarowska F, Whitehead P, Leigh IM, et al. Identification of the target antigen in chronic bullous disease of childhood and linear IgA disease of adults. *Br J Dermatol.* 1991;124:157-162.
12. Georgi M, Scheckenbach C, Kromminga A, et al. Mapping of epitopes on the BP180 ectodomain targeted by IgA and IgG autoantibodies in patients with the lamina lucida-type of linear IgA disease. *Arch Dermatol Res.* 2001;293:109-114.

13. Collier PM, Wojnarowska F, Welsh K, et al. Adult linear IgA disease and chronic bullous disease of childhood: the association with human lymphocyte antigens Cw7, B8, DR3 and tumour necrosis factor influences disease expression. *Br J Dermatol.* 1999;141:867-875.
14. Herron MD, Zone JJ. Dermatitis herpetiformis and linear IgA bullous dermatosis. In: Bologna JL, Jorizzo JL, Rapini RP, et al, eds. *Dermatology.* Vol 1. London, England: Mosby; 2003:479-489.
15. Kuechle MK, Stegemeir E, Maynard B, et al. Drug-induced linear IgA bullous dermatosis: report of six cases and review of the literature. *J Am Acad Dermatol.* 1994; 30(2, pt 1):187-192.
16. Zone JJ, Meyer LJ, Petersen MJ. Deposition of granular IgA relative to clinical lesions in dermatitis herpetiformis. *Arch Dermatol.* 1996;132:912-918.
17. Leonard JN, Griffiths CE, Powles AV, et al. Experience with a gluten free diet in the treatment of linear IgA disease. *Acta Derm Venereol.* 1987;67:145-148.
18. Peters MS, McEvoy MT. IgA antiendomysial antibodies in dermatitis herpetiformis. *J Am Acad Dermatol.* 1989;21:1225-1231.
19. Friedman IS, Rudikoff D, Phelps RG, et al. Captopril-triggered linear IgA bullous dermatosis. *Int J Dermatol.* 1998;37:608-612.
20. Vaillant L, Bernard P, Joly P, et al. Evaluation of clinical criteria for diagnosis of bullous pemphigoid. French Bullous Study Group. *Arch Dermatol.* 1998;134:1075-1080.
21. Ghohestani R, Kanitakis J, Nicolas JF, et al. Comparative sensitivity of indirect immunofluorescence to immunoblot assay for the detection of circulating antibodies to bullous pemphigoid antigens 1 and 2. *Br J Dermatol.* 1996;135: 74-79.
22. Woodley DT, Briggaman RA, O'Keefe EJ, et al. Identification of the skin basement-membrane autoantigen in epidermolysis bullosa acquisita. *N Engl J Med.* 1984;310:1007-1013.
23. Dahl MG. Epidermolysis bullosa acquisita—a sign of cicatricial pemphigoid? *Br J Dermatol.* 1979;101:475-484.
24. Wolff K, Johnson RA, Suurmond R. Bullous diseases. In: Wolff K, Johnson RA, Suurmond R, eds. *Fitzpatrick's Color Atlas and Synopsis of Clinical Dermatology.* 5th ed. New York, NY: McGraw-Hill; 2005:92-117.
25. Roujeau JC, Kelly JP, Naldi L, et al. Medication use and the risk of Stevens-Johnson syndrome or toxic epidermal necrolysis. *N Engl J Med.* 1995;333:1600-1607.
26. Fagot JP, Mockenhaupt M, Bouwes-Bavinck JN, et al. Nevirapine and the risk of Stevens-Johnson syndrome or toxic epidermal necrolysis. *AIDS.* 2001;15:1843-1848.
27. De Simone C, Guerriero C, Pellicano R. Linear IgA disease and ulcerative colitis. *Eur J Dermatol.* 1998;8:48-50.
28. Jacyk WK, Nagel GJ, van der Hoven AE. Linear IgA dermatosis and Hodgkin's lymphoma—report of a case in an African and review of the literature. *J Dermatol.* 1990;17:633-637.
29. Collier PM, Kelly SE, Wojnarowska F. Linear IgA disease and pregnancy. *J Am Acad Dermatol.* 1994;30:407-411.
30. Hall RP, Mickle CP. Dapsone. In: Wolverton SE, ed. *Comprehensive Dermatologic Drug Therapy.* 2nd ed. Philadelphia, PA: Saunders Elsevier; 2007:239-257.
31. Alajlan A, Al-Khawajah M, Al-Sheikh O, et al. Treatment of linear IgA bullous dermatosis of childhood with flucloxacillin. *J Am Acad Dermatol.* 2006;54:652-656.
32. Wiadrowski TP, Reid CM. Drug-induced linear IgA bullous disease following antibiotics. *Australas J Dermatol.* 2001;42:196-199.