

# Pemphigoid Gestationis: A Case Report and Review of the Literature

Shannon M. Campbell, DO; Kathryn Balazs, DO; Michael Conroy, MD

*Pemphigoid gestationis (PG) is an uncommon autoimmune bullous disease that almost exclusively presents during pregnancy. Patients typically present with a diffuse blistering and intensely pruritic eruption that begins periumbilically and spreads to involve the rest of the body. Direct immunofluorescence demonstrating C3 in a linear pattern along the dermoepidermal junction confirms the diagnosis of PG. Corticosteroids remain the choice of therapy and early intervention is essential because of possible adverse effects of PG on the fetus. We report a case of PG and review the literature.*

*Cutis.* 2011;88:21-26.

## Case Report

A 27-year-old white woman (gravida 2, para 1) presented to our clinic at 32 weeks' gestation with a report of a severely pruritic eruption of 6 weeks' duration. She had been seen by her primary care physician a few weeks prior and was diagnosed with rhus dermatitis. She was treated with a 12-day prednisone taper of 30 mg for 3 days, 20 mg for 3 days, 10 mg for 3 days, and 5 mg for 3 days, which initially provided some relief. However, the eruption persisted and intense pruritus returned. Subsequently, she was referred to our clinic.

Physical examination revealed annular, urticarial, vesicular plaques covering her entire back, forearms, flank, chest, abdomen, and legs (Figure 1). Yellow

crusting, bullae, and vesicles were present throughout the plaques (Figure 2). An initial clinical assessment of pemphigoid gestationis (PG) was made. Punch biopsy of the left forearm was taken for hematoxylin and eosin staining and a perilesional site was sampled for direct immunofluorescence. In the interim, we started the patient on triamcinolone acetonide cream 0.1%, a 30-day prednisone taper starting at 60 mg daily for 5 days and decreasing 10 mg daily every 5 days until a dosage of 10 mg daily was achieved, and ciproheptadine hydrochloride 4 mg 3 times daily. In addition, we gave her a 7-day course of erythromycin 500 mg twice daily and instructed her to apply mupirocin ointment to secondarily impetiginized areas.

Punch biopsy results showed subepidermal vesicles and papillary dermal edema (Figure 3). Scattered lymphocytes, histiocytes, and eosinophils were located in the dermis in a perivascular distribution (Figure 4). Direct immunofluorescence staining was negative for IgG, IgM, and IgA, but C3 was present in a linear fashion along the dermoepidermal junction, confirming the diagnosis of PG.

The patient responded well within 2 weeks of starting the prednisone taper and her lesions regressed. She delivered at 38 weeks' gestation and did not flare at the time of delivery. The infant was healthy and had no evidence of skin lesions or adrenal suppression at birth. However, at 1-week postpartum and at the onset of her first menses, the patient experienced a resurgence of her PG. Again, the patient was started on the same prednisone taper used during her pregnancy and her lesions completely resolved during both relapses. At the time of this publication, she had no further recurrence of PG.

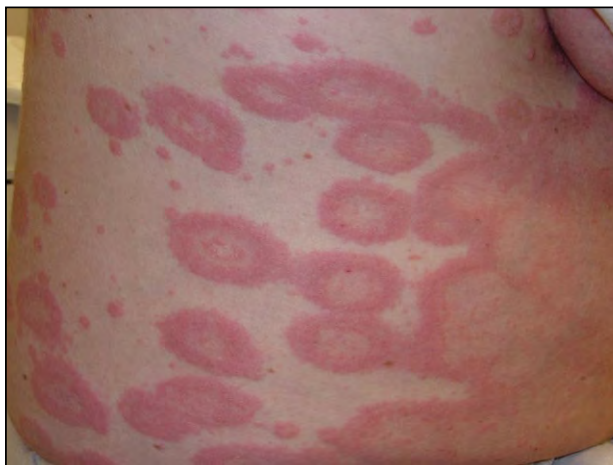## Comment

Pemphigoid gestationis is a rare dermatosis that almost exclusively presents during pregnancy.<sup>1</sup> It also has been associated with trophoblastic diseases such as hydatidiform mole<sup>2</sup> or choriocarcinoma.<sup>3</sup> Pemphigoid gestationis, known historically as herpes gestationis, has no known viral etiology or association with the

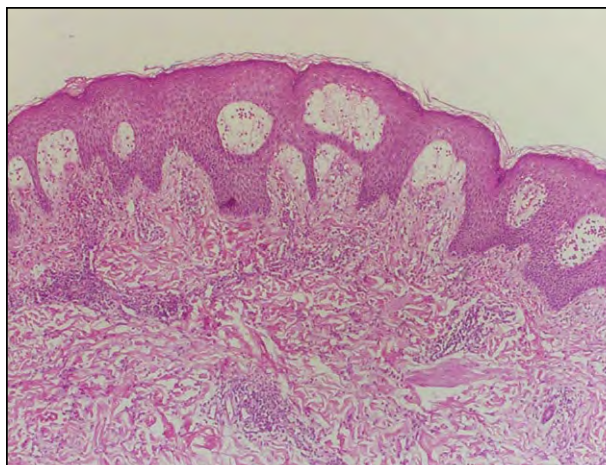
---

Dr. Campbell was from Ohio University College of Osteopathic Medicine, O'Bleness Memorial Hospital Dermatology Residency Program, Athens, and currently is from the Department of Dermatology, Boston Medical Center, Massachusetts. Dr. Balazs is from Beaver Creek Dermatology, Ohio. Dr. Conroy is from Dermatopathology Laboratory of Central States, Dayton, Ohio, and Dermatologists of Greater Columbus, Dublin, Ohio. The authors report no conflict of interest.

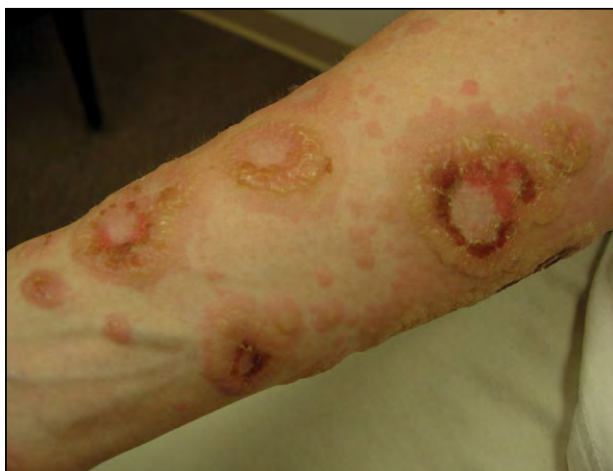Correspondence: Shannon M. Campbell, DO, Boston Medical Center, 720 Harrison Ave, DOB 801A, Boston, MA 02118 (shannoncampbell25@gmail.com).



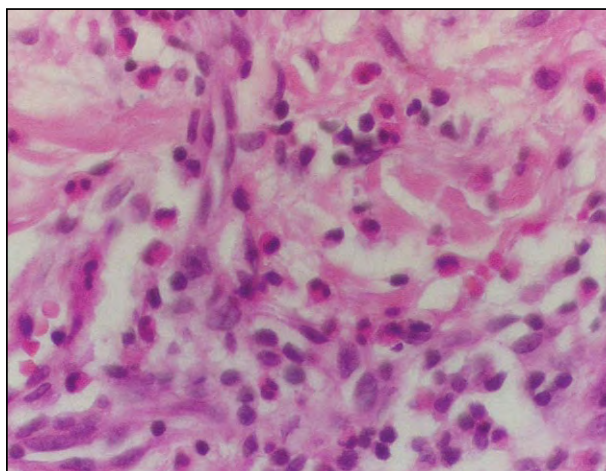
**Figure 1.** Large urticarial plaques involving the abdomen and right flank, extending to the chest and back.



**Figure 3.** Punch biopsy results showed subepidermal vesicles and papillary dermal edema (H&E, original magnification  $\times 40$ ).



**Figure 2.** Urticarial plaques with multiple bullae and vesicle formation on the right anterior forearm.



**Figure 4.** Perivascular inflammatory infiltrate consisting of lymphocytes and eosinophils (H&E, original magnification  $\times 400$ ).

herpes simplex virus. The term *herpes gestationis* was coined in recognition of the herpetiform lesions classically seen in PG.<sup>4</sup> Interestingly, PG shares clinical, histological, and immunological characteristics with bullous pemphigoid, suggesting that the 2 diseases may be related.<sup>5</sup>

Pemphigoid gestationis is a rare disease with a wide range of incidences reported. Several reports estimate the incidence of PG at 1 in 50,000 to 60,000 pregnancies.<sup>6,7</sup> Higher incidences, up to 1 in 3000,<sup>8</sup> also have been recorded, but these numbers have been criticized for accuracy secondary to referral bias and the inclusion of cases that fail to meet immunologic criteria for PG.<sup>9</sup> In a study performed by Zurn et al,<sup>10</sup> the incidence was estimated at 1 in 7000,

which has led many investigators to speculate that cases of PG may be underreported. There is some predilection for race with considerably more cases documented in white individuals than other races.<sup>11,12</sup> This demographic finding may be related to the suspected pathogenic role of major histocompatibility complex class antigens and the fact that white individuals have an increased frequency of HLA-DR3 and DR4.<sup>11</sup>

**Clinical Characteristics**—The clinical presentation of PG is polymorphic and evolutionary in nature. Typically, patients initially present with erythematous papules, plaques, or targetoid lesions reminiscent of erythema multiforme. Over time, small vesicles and bullae appear on normal skin or on top of urticarial

plaques, reminiscent of urticarial bullous pemphigoid. There are some cases of PG in which blister formation never occurs.<sup>13-15</sup> Pemphigoid gestationis lesions characteristically begin periumbilically and then spread outward to include the buttocks, trunk, and extremities, sparing the mucous membranes and face.<sup>14</sup> Nonetheless, there have been case reports of PG with primary involvement of the oral mucosa.<sup>16</sup>

Intense pruritus is the consistent hallmark of PG, while the clinical course is variable. Pemphigoid gestationis typically presents during the second or third trimester with a mean onset of 21 weeks but may develop in the first trimester, the time of delivery (75% of cases),<sup>17,18</sup> the first postpartum month,<sup>13-15</sup> and with the onset of menses or the use of oral contraceptives in the postpartum period.<sup>13,14,19</sup> In 20% of cases, the initial presentation occurs in the immediate postpartum period.<sup>5</sup> Some studies have shown that breastfeeding may decrease the duration of the disease,<sup>9,19</sup> with lesions for breastfeeding and bottle-feeding mothers lasting on average 5 weeks and 24 weeks, respectively.<sup>9</sup>

Most commonly, PG resolves spontaneously without scarring within weeks to months after delivery.<sup>20</sup> Pemphigoid gestationis can arise in subsequent pregnancies and may have a tendency to occur earlier in gestation and be more severe at times. Mothers affected by PG do not always experience the disease in succeeding pregnancies. In fact, skip pregnancies have been noted in the literature, estimated at 5% to 8%.<sup>15,21</sup> In multiparous patients with PG, the postpartum duration of PG may be extensive and, as shown in one unusual case, may last for several years after delivery.<sup>22</sup>

Pemphigoid gestationis also has been linked with an increased risk for autoimmune diseases, especially Graves disease.<sup>23</sup> An estimated 10% of patients with PG also have a concurrent autoimmune disease.<sup>24</sup> Cases of alopecia areata, vitiligo, and ulcerative colitis also have been reported in patients with PG.<sup>23</sup>

Differential diagnosis of PG includes pruritic urticarial papules and plaques of pregnancy (PUPPP) and bullous pemphigoid. Although pathologic analysis is the only way to clearly differentiate between these diagnoses, clinical features may lend support to one diagnosis over the other. Pruritic urticarial papules and plaques of pregnancy, the most common dermatosis of pregnancy, typically occurs in primigravid patients in the third trimester and lesions tend to lack bullae and appear more focally on the lower abdomen and thighs instead of periumbilically. In addition, the lesions of PUPPP characteristically appear in the striae. Bullous pemphigoid primarily affects elderly patients and both sexes equally. Other potential diagnoses such as erythema multiforme and dermatitis

herpetiformis also resemble PG in presentation and should be included on the list of potential diagnoses.

*Histopathology, Immunofluorescence, and Pathophysiology*—The histologic findings in PG parallel bullous pemphigoid and consequently fail to distinguish it from this autoimmune subepidermal disease. In PG, there is a subepidermal bulla with an underlying inflammatory infiltrate consisting of histiocytes, lymphocytes, and eosinophils in the dermis. Blisters, if present, are found subepidermally. Direct immunofluorescence shows deposition of C3 in a linear pattern along the basement membrane and is considered pathognomonic for diagnosis of PG.<sup>17</sup> In approximately 25% to 30% of cases, IgG deposition also can be found along the basement membrane.<sup>25</sup>

In addition to histologic analysis and direct immunofluorescence to aid in the diagnosis of PG, Powell et al<sup>26</sup> demonstrated that a serologic test measuring the major immunoreactive portion of the NC16A domain of BP180 antigen can be used to verify the diagnosis of PG and differentiate it from PUPPP. Sitaru et al<sup>27</sup> also supported the use of NC16A levels to measure the presence of autoantibodies and assist in the diagnosis of PG. Furthermore, because NC16A levels correlate with disease activity, they can be used to follow disease progression and consequently may impact the course of treatment.<sup>27</sup>

Pemphigoid gestationis is considered an autoimmune blistering disease in which autoantibodies develop against the basement membrane zone, the same mechanism believed to be responsible for bullous pemphigoid.<sup>28</sup> Approximately 20% of patients with PG have a complement-fixing protein in their serum, known as the herpes gestationis factor, a revelation that was further defined by Jordon et al<sup>29</sup> and Katz et al<sup>30</sup> as complement-fixing anti-basement membrane zone IgG. Kelly et al<sup>25</sup> identified IgG1 as the major subclass of PG anti-basement membrane zone autoantibodies. In contrast, Patton et al<sup>31</sup> found that the predominant IgG subclass in PG is IgG4, the major subclass in bullous pemphigoid. Regardless, it is accepted that the PG autoantibodies recognize the BP180 antigen, also known as collagen type XVIII and BPAG2,<sup>32-38</sup> and activate complement via the classical pathway.<sup>17</sup> The bullous pemphigoid antigen is located in the basement membrane of normal skin and in the basement membrane zone of amniotic epithelium of both the placenta and umbilical cord.<sup>39,40</sup> An allogenic autoimmune response, possibly facilitated by the abnormal expression of class II major histocompatibility complex antigens in the placenta, may explain the pathophysiologic phenomenon of PG.<sup>1</sup>

There appears to be a genetic basis for the development of PG, particularly with HLA-DR3 and DR4.

As many as 61% to 85% of patients with PG have HLA-DR3, 50% have HLA-DR4,<sup>41</sup> and 43% to 45% have both HLA-DR3 and DR-5.<sup>19,41</sup> In addition, 50% of husbands of PG patients have HLA-DR2. The paternal role in the pathogenesis of PG also has been studied. In a study by Holmes et al,<sup>19</sup> a change in paternity and noted increase in PG implied that the 2 events may be related and that the development of PG may depend on antigens provided by the father. In contrast, Jenkins et al<sup>15</sup> asserted that their study showed no correlation between partner change and the occurrence of PG; skip pregnancies could not be explained by partner changes either. The hypothesis that PG results from an allogenic response to placental basement membrane zones raises the issue of the paternal role in the pathogenesis of PG because the placenta primarily is of paternal origin.<sup>19</sup>

**Fetal Risk**—One of the most important considerations in approaching the patient with PG is the effect the disease may or may not have on the fetus. Patients with PG should be identified as a high-risk pregnancy and be followed accordingly. Most studies show that infants of PG mothers tend to be small for gestational age and have an increased likelihood to be born premature, findings consistent with low-grade placental insufficiency. Furthermore, a controversial study performed by Lawley et al<sup>13</sup> claimed that PG was associated with an increase in fetal death. However, later studies have disputed this claim and did not find an increase in fetal morbidity or mortality in PG.<sup>4,42</sup> Some infants of PG mothers, approximately 5% to 10%,<sup>43</sup> have a transient subepidermal blistering eruption that resolves on its own with no known sequelae. This finding is most likely due to transplacental passage of antibodies from the mother to the baby.<sup>44</sup> After delivery, infants of mothers treated with corticosteroids should be monitored for signs of adrenal insufficiency.

**Treatment**—Pemphigoid gestationis usually can be managed with the administration of topical or oral corticosteroids or a combination thereof. Mild lesions can be managed with topical steroids,<sup>9,45</sup> while more severe cases require the use of systemic steroids.<sup>46</sup> Most cases of PG respond well to low dosages (20–60 mg daily), but the need for higher dosages up to 180 mg daily have been reported.<sup>13</sup> Multiple steroid tapers may be necessary for treatment because the eruption may flare right after delivery or with the onset of menses. It does not appear that treatment with systemic steroids adversely affects the fetus.<sup>47</sup> Effective management is gauged by the disappearance of old lesions and the lack of new lesions erupting. Antipruritic drugs such as diphenhydramine, hydroxyzine, loratadine, or cetirizine are effective to help alleviate pruritis.<sup>15</sup> Due to excoriations as

well as bullae and vesicles breaking open, patients should be monitored for secondary infection and treated accordingly.

A mixture of other agents have been used to treat PG in the postpartum period. There has been variable success noted with the use of dapsone, sulfapyridine,<sup>48</sup> gold,<sup>49</sup> cyclophosphamide,<sup>50</sup> pyridoxine,<sup>51</sup> and methotrexate.<sup>49</sup> Intravenous immunoglobulin in conjunction with cyclosporine also has been used in resistant cases.<sup>52</sup> There also have been some promising results with tetracycline in postpartum PG.<sup>53</sup> In addition, plasmapheresis has been applied in refractory cases with some clinical improvement.<sup>4,15</sup>

## Conclusion

In summary, PG is an autoimmune disease that occurs almost exclusively during pregnancy. Its clinical course is variable, but eruptions typically respond to steroid therapy. It is important to diagnose and treat PG early, not only to provide symptomatic relief to patients but to prepare for possible adverse outcomes on the fetus.

## REFERENCES

1. Engineer L, Bhol K, Ahmed AR. Pemphigoid gestationis: a review. *Am J Obstet Gynecol.* 2000;183:483-491.
2. Tindall JG, Rea TH, Shulman I, et al. Herpes gestationis in association with a hydatidiform mole. immunopathologic studies. *Arch Dermatol.* 1981;117:510-512.
3. Tillman WG. Herpes gestationis with hydatidiform mole and chorion epithelioma. *Br Med J.* 1950;1:1471.
4. Shornick JK. Herpes gestationis. *J Am Acad Dermatol.* 1987;17:539-556.
5. Borradori L, Saurat JH. Specific dermatoses of pregnancy. toward a comprehensive view? *Arch Dermatol.* 1994;130:778-780.
6. Kolodny RC. Herpes gestationis: a new assessment of incidence, diagnosis, and fetal prognosis. *Am J Obstet Gynecol.* 1969;104:39-45.
7. Holmes RC, Black MM, Dann J, et al. A comparative study of toxic erythema of pregnancy and herpes gestationis. *Br J Dermatol.* 1982;106:499-510.
8. Russell B, Thorne NA. Herpes gestationis. *Br J Dermatol.* 1957;69:339-357.
9. Yancey KB. Herpes gestationis. *Dermatol Clin.* 1990;8:727-735.
10. Zurn A, Celebi CR, Bernard P, et al. A prospective immunofluorescence study of 111 cases of pruritic dermatoses of pregnancy. IgM anti-basement membrane zone antibodies as a novel finding. *Br J Dermatol.* 1992;126:474-478.
11. Shornick JK, Meek TJ, Nesbitt LT Jr, et al. Herpes gestationis in blacks. *Arch Dermatol.* 1984;120:511-513.
12. García-González E, Castro-Llamas J, Karchmer S, et al. Class II major histocompatibility complex typing across

- the ethnic barrier in pemphigoid gestationis: a study of Mexicans. *Int J Dermatol*. 1999;38:46-51.
13. Lawley TJ, Stingl G, Katz SI. Fetal and maternal risk factors in herpes gestationis. *Arch Dermatol*. 1978;114:552-555.
  14. Shornick JK, Bangert JL, Freeman RG, et al. Herpes gestationis: clinical and histological features of twenty-eight cases. *J Am Acad Dermatol*. 1983;8:214-224.
  15. Jenkins RE, Hern S, Black MM. Clinical features and management of 87 patients with pemphigoid gestationis. *Clin Exp Dermatol*. 1999;24:255-259.
  16. Shimanovich I, Skrobek C, Rose C, et al. Pemphigoid gestationis with predominant involvement of oral mucous membranes and IgA autoantibodies targeting the C-terminus of BP180. *J Am Acad Dermatol*. 2002;47:780-784.
  17. Shornick JD. Dermatoses of pregnancy. *Semin Cutan Med Surg*. 1998;17:172-181.
  18. Baxi LV, Kovilam OP, Collins MH, et al. Recurrent herpes gestationis with postpartum flare: a case report. *Am J Obstet Gynecol*. 1991;164:778-780.
  19. Holmes RC, Black MM, Jurecka W, et al. Clues to aetiology and pathogenesis of herpes gestationis. *Br J Dermatol*. 1983;109:131-139.
  20. Holmes RC, Black MM, Williamson DM, et al. Herpes gestationis and bullous pemphigoid: a disease spectrum. *Br J Dermatol*. 1980;103:535-541.
  21. Shornick JK. Herpes gestationis. *Dermatol Clin*. 1993;11:527-533.
  22. Holmes RC, Williamson DM, Black MM. Herpes gestationis persisting for 12 years postpartum. *Arch Dermatol*. 1986;122:375-376.
  23. Shornick JK, Black MM. Secondary autoimmune diseases in herpes gestationis (pemphigoid gestationis). *J Am Acad Dermatol*. 1992;26:563-566.
  24. Karna P, Brocker AH. Neonatal herpes gestationis. *J Pediatr*. 1991;119:299-301.
  25. Kelly SE, Cerio R, Bhogal BS, et al. The distribution of IgG subclasses in pemphigoid gestationis: PG factor is an IgG1 autoantibody. *J Invest Dermatol*. 1989;92:695-698.
  26. Powell M, Sakuma-Oyama Y, Oyama N, et al. Usefulness of BP180 NC16a enzyme-linked immunosorbent assay in the serodiagnosis of pemphigoid gestationis (HG) and differentiating between pemphigoid gestationis and pruritic urticarial papules and plaques of pregnancy. *Arch Dermatol*. 2005;141:705-710.
  27. Sitaru C, Powell J, Messer G, et al. Immunoblotting and enzyme-linked immunosorbent assay for the diagnosis of pemphigoid gestationis. *Obstet Gynecol*. 2004;103:757-763.
  28. Provost TT, Tomasi TB Jr. Evidence for complement activation via the alternate pathway in skin disease, I: herpes gestationis, systemic lupus erythematosus, and bullous pemphigoid. *J Clin Invest*. 1973;52:1779-1787.
  29. Jordon RE, Heine KC, Tappeiner G, et al. The immunopathology of herpes gestationis. immunofluorescence studies and characterization of the "HG factor." *J Clin Invest*. 1976;57:1426-1431.
  30. Katz SI, Hertz KC, Yaoita H. Herpes gestationis. immunopathology and characterization of the HG factor. *J Clin Invest*. 1976;57:1434-1441.
  31. Patton T, Plunkett RW, Beutner EH, et al. IgG4 as the predominant IgG subclass in pemphigoid gestationis. *J Cutan Pathol*. 2006;33:299-302.
  32. Morrison LH, Labib RS, Zone JJ, et al. Herpes gestationis autoantibodies recognize a 180-kD human epidermal antigen. *J Clin Invest*. 1988;81:2023-2026.
  33. Giudice GJ, Emery DJ, Zelickson BD, et al. Bullous pemphigoid and herpes gestationis autoantibodies recognize a common non-collagenous site on the BP180 ectodomain. *J Immunol*. 1993;151:5742-5750.
  34. Matsumara K, Amagai M, Nishikawa T, et al. The majority of bullous pemphigoid and herpes gestationis serum samples react with NC16a domain of the 180-kDa bullous pemphigoid antigen. *Arch Dermatol Res*. 1996;288:507-509.
  35. Kelly SE, Bhogal BS, Wojnarowska F, et al. Western blot analysis of the antigen in pemphigoid gestationis. *Br J Dermatol*. 1990;122:445-449.
  36. Shornick JK, Jenkins RE, Artlett CM, et al. Class II MHC typing in pemphigoid gestationis. *Clin Exp Dermatol*. 1995;20:123-126.
  37. Stanley JR, Hawley-Nelson P, Yuspa SH, et al. Characterization of bullous pemphigoid antigen: a unique basement membrane protein of stratified squamous epithelia. *Cell*. 1981;24:897-903.
  38. Amagai M, Hashimoto T, Tajima S, et al. Partial cDNA cloning of the 230-kD mouse bullous pemphigoid antigen by use of a human monoclonal anti-basement membrane zone antibody. *J Invest Dermatol*. 1990;95:252-259.
  39. Ortonne JP, Hsi BL, Verrando P, et al. Herpes gestationis factor reacts with the amniotic epithelial basement membrane. *Br J Dermatol*. 1987;117:147-154.
  40. Kelly SE, Bhogal BS, Wojnarowska F, et al. Expression of a pemphigoid gestationis-related antigen by human placenta. *Br J Dermatol*. 1988;118:605-611.
  41. Shornick JK, Stastny P, Gilliam JN. High frequency of histocompatibility antigens HLA-DR3 and DR4 in herpes gestationis. *J Clin Invest*. 1981;68:553-555.
  42. Holmes RC, Black MM. The fetal prognosis in pemphigoid gestationis. *Br J Dermatol*. 1984;110:67-72.
  43. Katz A, Minto JO, Toole JW, et al. Immunopathologic study of herpes gestationis in mother and infant. *Arch Dermatol*. 1977;113:1069-1072.
  44. Chorzelski TP, Jablonska S, Beutner EH, et al. Herpes gestationis with identical lesions in the newborns: passive transfer of the disease? *Arch Dermatol*. 1976;112:1129-1131.
  45. Kroupouzou G, Cohen LM. Dermatoses of pregnancy. *J Am Acad Dermatol*. 2001;45:1-19.
  46. Pönninhaus JM, Ziegler H, Kowalick L. Herpes gestationis: oral corticosteroids cannot be avoided [in German]. *Zentralbl Gynakol*. 1998;120:548-550.

## Pemphigoid Gestationis

47. Shornick JK, Black MM. Fetal risks in herpes gestationis. *J Am Acad Dermatol.* 1992;26:63-68.
48. Al-Fouzan AW, Galadari I, Oumeish I, et al. Herpes gestationis (pemphigoid gestationis). *Clin Dermatol.* 2006;24:109-112.
49. Fine DJ, Omura EF. Herpes gestationis: persistent disease activity 11 years postpartum. *Arch Dermatol.* 1985;121:924-926.
50. Castle SP, Mather-Mondrey M, Bennion S, et al. Chronic herpes gestationis and antiphospholipid antibody syndrome successfully treated with cyclophosphamide. *J Am Acad Dermatol.* 1996;34(2, pt 2):333-336.
51. Burkhart CG. Pyridoxine-responsive herpes gestationis. *Arch Dermatol.* 1982;118:535.
52. Hern S, Harman K, Bhogal BS, et al. A severe persistent case of pemphigoid gestationis treated with intravenous immunoglobulins and cyclosporin. *Clin Exp Dermatol.* 1998;23:185-188.
53. Satoh S, Seishima M, Sawada Y, et al. The time course of the change in antibody titres in herpes gestationis. *Br J Dermatol.* 1999;140:119-123.