

Tinea Capitis Caused by Dermatophytes: A 15-Year Retrospective Study From a Mississippi Dermatology Clinic

John C. Chapman, MD; C. Ralph Daniel III, MD; Jonathan G. Daniel, MHA, MBA; Melissa P. Daniel, PhD; Sabra Sullivan, MD, PhD; Dena Howell, MD; Boni E. Elewski, MD; Loretta Conrad Thames, LPN

Tinea capitis is a highly contagious disorder occurring predominantly in children. Presentation is variable and, as such, mycologic confirmation of dermatophyte infection would be useful in targeting specific therapy and implementing preventive measures to interrupt spread of infection. This retrospective study was performed at an outpatient dermatology clinic in Jackson, Mississippi, over a 15-year period (1983-1998). Dermatophyte infections were confirmed using scalp scrapings cultured on Mycosel™ Agar containing cycloheximide and chloramphenicol. Cultures were performed on 1220 patients of all ages presenting with signs and symptoms suggestive of tinea capitis. Of the total patients meeting the inclusion criteria, 66% were younger than 13 years. Overall, 39% (478/1220) had positive cultures for dermatophytes, with black individuals having the highest percentage of positive cultures (87% [414/478]). In addition to a review of findings, we examine the impact of a cultural diagnosis of dermatophyte infection on the treatment and prevention of this highly contagious infection.

Cutis. 2011;88:230-233.

Dr. Chapman was from the University of Mississippi Medical Center, Jackson, and currently is from Tulane Medical Center, New Orleans, Louisiana. Drs. C.R. Daniel and Sullivan are from private practice, Jackson. Mr. Daniel, Dr. M.P. Daniel, and Mrs. Thames are from the University of Mississippi Medical Center. Dr. Howell is from private practice, Mobile, Alabama. Dr. Elewski is from the University of Alabama, Birmingham.

The authors report no conflict of interest.

Correspondence: John C. Chapman, MD, Tulane Department of Dermatology, 1430 Tulane Ave #8036, New Orleans, LA 70112 (Jchapma4@tulane.edu).

Fungal infections of the stratum corneum and other keratinized tissues of the skin, hair, and nails results from infection by a number of yeast and fungi, including the dermatophyte molds, and is a problem worldwide.^{1,2} The dermatophytes consist of 3 genera of fungi—*Epidermophyton*, *Trichophyton*, and *Microsporum*—that commonly cause skin disease in humans and animals. These pathogenic genera of dermatophytes often are defined on the basis of their natural reservoir and potential for infection as geophilic (*Epidermophyton* species), anthropophilic (*Trichophyton* species), or zoophilic (*Microsporum* species). The general term *tinea* denotes the clinical manifestation of these infections, followed by the common site of the infection such as the feet (*tinea pedis*), groin (*tinea cruris*), trunk (*tinea corporis*), scalp (*tinea capitis*), and nails (*tinea unguium*).

Worldwide, *Microsporum canis* is the most frequent cause of zoophilic dermatophytosis.¹ Geophilic organisms such as *Microsporum gypseum* are less frequent causes of human disease and usually are seen in tropical climates. Outbreaks of infection have been reported, however, in gardeners and farmworkers.² Anthropophilic dermatophytes are the most frequent clinical cause of dermatophytosis. *Trichophyton rubrum* is the major anthropophilic dermatophyte causing superficial skin infections, including *tinea cruris*, *tinea pedis*, and *tinea corporis*.

Tinea capitis causes both an endemic and epidemic disease. Although the most common cause of *tinea capitis* worldwide is *M canis*, the most common cause in the United States is *Trichophyton tonsurans*.¹ Poor social and economic factors, including overcrowding, poor hygiene, and protein malnutrition, as well as frequent person-to-person contact and warm humid climates, appear to favor the occurrence of *tinea capitis*.³ Although the disease is seen in all age groups, *tinea capitis* occurs most frequently in

children, especially black individuals, and may be seen in epidemic proportions.⁴

Tinea capitis may be diagnosed by clinical appearance, but prior studies have shown it is commonly underdiagnosed in infants and children who present with scaly scalp lesions.^{5,6} In contrast, seborrheic dermatitis or other inflammatory conditions frequently are misdiagnosed as tinea capitis in adolescents and adults.⁷ Hence, there is a need for the clinician to perform an office-based laboratory test that identifies dermatophytes as a cause of the clinical manifestations.

This retrospective study was performed to (1) determine the incidence of tinea capitis caused by dermatophytes in patients presenting with scalp lesions in a large private dermatology practice, (2) verify the previously noted increased incidence of tinea capitis in black individuals applied to this private practice population, and (3) document the utility of cultures in diagnosing tinea capitis. A microbiologic diagnosis of tinea capitis is useful in facilitating appropriate antifungal therapy and implementing methods of preventing person-to-person spread of disease. This study documents the utility of cultures in diagnosing tinea capitis in the clinical practice of dermatology.

Materials and Methods

Patients—This retrospective study was conducted over a 15-year period (1983-1998) at an author's (C.R.D) outpatient dermatology clinic in Jackson, Mississippi, that treated patients of all ages. During this period the clinic recorded more than 100,000 patient visits with a variety of clinical diagnoses. The overall patient population was approximately 50% white and approximately 50% black. The inclusion criteria for patients cultured were defined by clinical signs suggestive of tinea capitis, including scaly scalp lesions that may or may not be associated with erythema, itching, inflammation, cervical adenopathy, and/or alopecia. Patients were excluded from culture if other obvious clinical diagnoses were present, such as psoriasis, contact dermatitis, seborrheic dermatitis, or eczema.

Cultures—Scrapings of scalp lesions and plucked hairs were cultured at room temperature on a highly selective medium that contained cycloheximide and chloramphenicol (Mycosel™ Agar) and examined twice weekly for growth of dermatophytes for at least 3 weeks and up to 6 weeks. Positive cultures were identified as those with typical mycelial colonies as described for dermatophytes.⁸

Results

During the 15-year study period, 1220 patients were considered to have signs and symptoms of tinea capitis

and were included for cultures. Data were collected and analyzed for several important demographic characteristics. The age of patients identified as positive for dermatophytic tinea capitis is an important epidemiologic risk factor. Most patients meeting the inclusion criteria for culture were younger than 13 years (66% [810/1220]). Further, different ethnic groups have been reported to have increased risk for infection. Thus patients were identified as white, black, Hispanic, Asian, or other. Although equally represented in our patient population, 939 (77%) of patients meeting the clinical criteria for inclusion in the study and subsequent culture were black. Gender differences also were noted as a possible correlate of infection. Male and female populations cultured were similar (42% and 58%, respectively)(Table 1).

Positive cultures were reported in 478 patients (39%). Approximately half (53%) of the culture-positive patients were younger than 13 years. Of the 478 positive cultures, 414 (87%) were from black patients. No disparity in gender was noted, with similar rates of positive cultures for both male and female patients entered into the study (46% and 54%, respectively) (Table 2; Figure).

Comment

The signs and symptoms of tinea capitis vary from mild scaling of the scalp with minimal inflammation to a severe pustular dermatitis (kerion), alopecia, and lymphadenopathy.⁹ In addition to tinea capitis, a number of other clinical conditions may present with scaly alopecia of the scalp. The differential diagnosis includes alopecia areata, discoid lupus erythematosus, dissecting cellulitis, folliculitis decalvans, impetigo,

Table 1.

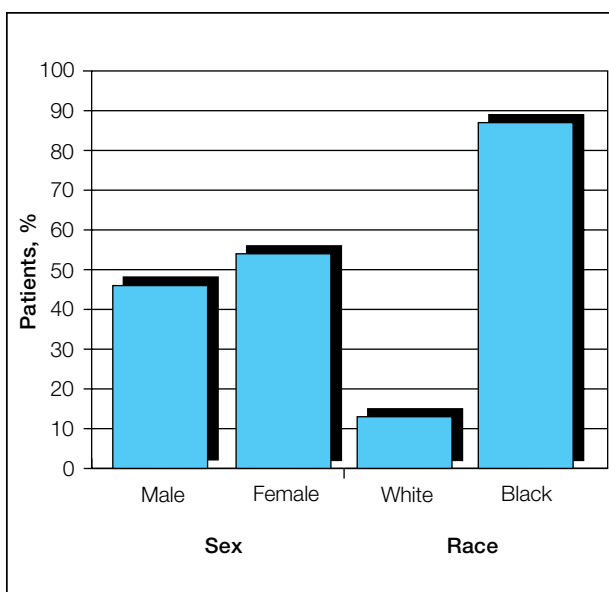
Demographics of Study Population Cultured

	Patients, n (%) (N=1220)
Sex	
Male	512 (42)
Female	708 (58)
Race	
White	281 (23)
Black	939 (77)

Table 2.

Demographics of Patients With Positive Culture Results

	Patients, n (%) (n=478)
Sex	
Male	220 (46)
Female	258 (54)
Race	
White	64 (13)
Black	414 (87)



Demographics of patients with positive culture results (n=478).

lichen planus, psoriasis, seborrheic dermatitis, and secondary syphilis, hence the need for definitive identification of dermatophytic infection for appropriate diagnosis and treatment.

Although a microscopic examination of potassium hydroxide (KOH) preparations of clinical skin scraping or hair affords a rapid diagnostic test, some limitations have been noted. Some clinicians have little experience interpreting KOH preparations, thus reducing the value of the test.¹⁰ Artifacts including heterologous fibers, fat globules, and environmental contaminants may result in false positives.

A false-negative KOH preparation may be the result of early or inflammatory lesions, or it may be observed in patients partially treated with topical agents. Thus a negative KOH result cannot rule out the diagnosis of tinea capitis¹¹ and the definitive diagnosis should be made by culture.¹²

The time required for growth of dermatophytes and the identification of genus and species may be prolonged. Although detailed information concerning the infecting dermatophyte is valuable for epidemiologic purposes, determination of the genus and species is not necessary because treatment options for all of the dermatophytic molds that are associated with tinea capitis require oral therapy and are standard. Furthermore, epidemiologic data have repeatedly shown that *T tonsurans* is the predominant, if not exclusive, cause of tinea capitis in the United States.¹³⁻¹⁵

Interestingly, in comparison to other studies, nearly half of our culture-positive patients (47%) were 13 years and older. A clinical diagnosis of tinea capitis based only on appearance of the lesions often is incorrect in this older age group. Tinea capitis typically is a disease of childhood with the predominant age range affected between 3 and 7 years, though adults also can be affected.² The results of this study confirm prior literature documenting a higher prevalence of tinea capitis in children younger than 13 years (53% of positive cultures). The increased fungistatic action of triglycerides in the sebum produced following puberty usually is considered protective in adults in whom tinea capitis generally is considered uncommon.¹⁶ Therefore, a 47% incidence of dermatophyte-positive cultures in patients 13 years and older may represent a remarkable shift in epidemiology. Positive culture in these cases led to an initiation of antifungal therapy or a change to appropriate therapy.

In the United States, the incidence of tinea capitis correlates with large family size, crowded living conditions, and low socioeconomic status, and has been found to disproportionately affect black individuals.¹⁶ In our survey, black individuals represented 87% (414 of 478 positive cultures) of dermatophytic infections of the scalp. Elewski¹⁷ has suggested that certain culturally associated hair fashions, such as the plaiting of hair into tight rows or the use of pomades, may increase the incidence of tinea capitis by providing more favorable conditions for the establishment of infections.

Tinea capitis is highly contagious, with person-to-person spread occurring in families, classrooms, and other crowded environments. A specific mycologic diagnosis will facilitate earlier initiation of oral antifungal therapy. In addition, preventative measures may be implemented to reduce person-to-person spread in the home, school, or other social settings. These measures include using combination therapy

with oral antifungal agents and topical shampoos to decrease spore shedding, identifying and treating asymptomatic carriers, and managing sources of fomite contagion.^{17,18} Cultures also may be useful in identifying mixed infections, especially in immunocompromised hosts and patients with atypical skin lesions, and in performing follow-up for relapse of infection. Although not done in this study, identification of genus and species can be useful for identifying change in causation, epidemiology of endemic disease, and determination of point-source outbreaks.

Conclusion

Tinea capitis continues to be a frequent skin infection of children, though our study found 47% of patients 13 years and older. Further, we confirm that these infections continue to occur in specific ethnic groups, especially black individuals, which is of public health significance owing to its contagious nature. The clinical presentation of tinea capitis may be varied and confirmation of dermatophyte infection by culture ensures delineation of specific antifungal therapy and a variety of preventive measures to limit person-to-person spread and reduce recurrence.

Acknowledgment—We thank Stanley W. Chapman, MD, and Donna C. Sullivan, PhD, for review of the manuscript.

REFERENCES

- Weeks J, Moser SA, Elewski BE. Superficial cutaneous fungal infections. In: Dismukes WE, Pappas PG, Sobel JD, eds. *Clinical Mycology*. New York, NY: Oxford University Press; 2003:367-389.
- Hay J. Dermatophytosis and other superficial mycoses. In: Mandell GL, Bennet JE, Dolin A, eds. *Principles and Practice of Infectious Diseases*. Vol 2. 6th ed. Philadelphia, PA: Churchill Livingstone; 2010:3345-3355.
- Martin AG, Kobayashi GS. Fungal diseases with cutaneous involvement. In: Fitzpatrick TB, Eisen A, Wolff K, et al, eds. *Dermatology in General Medicine*. Vol 2. New York, NY: McGraw-Hill; 1993:2421-2451.
- Aly R, Hay J, Del Palacio A, et al. Epidemiology of tinea capitis. *Med Mycol*. 2000;38(suppl 1):183-188.
- Romano C, Gianni C, Papinin M. Tinea capitis in infants less than 1 year of age. *Pediatr Dermatol*. 2001;18:465-468.
- Goldstein BG, Goldstein AO. Approach to the patient with a scalp eruption. *UpToDate*. <http://www.uptodate.com/contents/approach-to-the-patient-with-a-scalp-eruption>. Updated December 22, 2008. Accessed October 18, 2011.
- Goldstein AO, Goldstein BG. Dermatophyte (tinea) infections. *UpToDate*. <http://www.uptodate.com/contents/dermatophyte-tinea-infections>. Updated June 14, 2011. Accessed October 18, 2011.
- Summerbell RC. *Trichophyton*, *Microsporum*, *Epidermophyton*, and agents of superficial mycoses. In: Murray PR, Baron EJ, Jorgenson JH, et al, eds. *Manual of Clinical Microbiology*. Vol 2. 9th ed. Washington, DC: ASM Press; 2007:1874-1897.
- Chapman SW, Daniel CR III. Cutaneous manifestations of fungal infection. *Infect Dis Clin North Am*. 1994;8:879-910.
- Thomas B. Clear choices in managing epidermal tinea infections. *J Fam Pract*. 2003;52:850-862.
- Turnin L, Riva F, Galbiati F, et al. Fast, simple and highly sensitive double rounded polymerase chain reaction assay to detect medically relevant fungi in dermatological specimens. *Eur J Clin Invest*. 2000;30:511-518.
- Aly R. Ecology, epidemiology and diagnosis of tinea capitis. *Pediatr Infect Dis J*. 1999;18:180-185.
- Gan VM, Petruska M, Ginsburg CM. Epidemiology and treatment of tinea capitis: ketoconazole vs. griseofulvin. *Pediatr Infect Dis J*. 1987;6:46-49.
- Lucky AW. Epidemiology, diagnosis, and management of tinea capitis in the 1980s. *Pediatr Dermatol*. 1985;2:226-228.
- Kemna ME, Elewski BE. A U.S. epidemiologic survey of superficial fungal diseases. *J Am Acad Dermatol*. 1996;35:539-542.
- Gupta AK, Summerbell RC. Tinea capitis. *Med Mycol*. 2000;38:255-287.
- Elewski BE. Tinea capitis: a current perspective. *J Am Acad Dermatol*. 2000;42(1, pt 1):1-20.
- Nesbitt LT Jr. Treatment of tinea capitis. *Int J Dermatol*. 2000;39:261-262.



NEED MORE INFORMATION?

Access these related articles in our online archives at www.cutis.com

- ▾ Tinea Capitis: Current Concepts in Clinical Practice
- ▾ Topical Treatment of Tinea Capitis in a Neonate

Use our Advanced Search to find these articles and more online!