

Series Editor: Camila K. Janniger, MD

# Congenital Infantile Fibrosarcoma: A Clinical Mimicker of Hemangioma

Deepali Jain, MD; Kavita Kohli, MD

*Congenital infantile fibrosarcoma (CIFS) is a rare pediatric soft tissue tumor; clinically, it presents as a highly vascular mass and may simulate a hemangioma. It usually occurs in the first year of life and has a relatively better prognosis compared to other aggressive spindle cell sarcomas of childhood. We report a patient with CIFS who presented with a nonspecific ulcerated mass lesion over the right shoulder region that was clinically diagnosed as a benign vascular lesion. Histology revealed a highly cellular tumor with closely packed fascicles of spindle cells. Immunohistochemically, the tumor cells expressed vimentin.*

*Cutis.* 2012;89:61-64.

**C**ongenital infantile fibrosarcoma (CIFS) is a malignant soft tissue tumor originating from fibroblasts.<sup>1</sup> It is an uncommon pediatric malignancy with a good prognosis. The diagnosis is made on the basis of clinical, pathological, and immunohistochemical examination. As a hypervascular tumor, it can be misdiagnosed as congenital hemangioma on clinical and radiological grounds.<sup>1-3</sup> We describe a patient with CIFS who presented with an ulcerated mass lesion over the right shoulder region. Clinical and radiological diagnosis suggested a hemangioma.

## Case Report

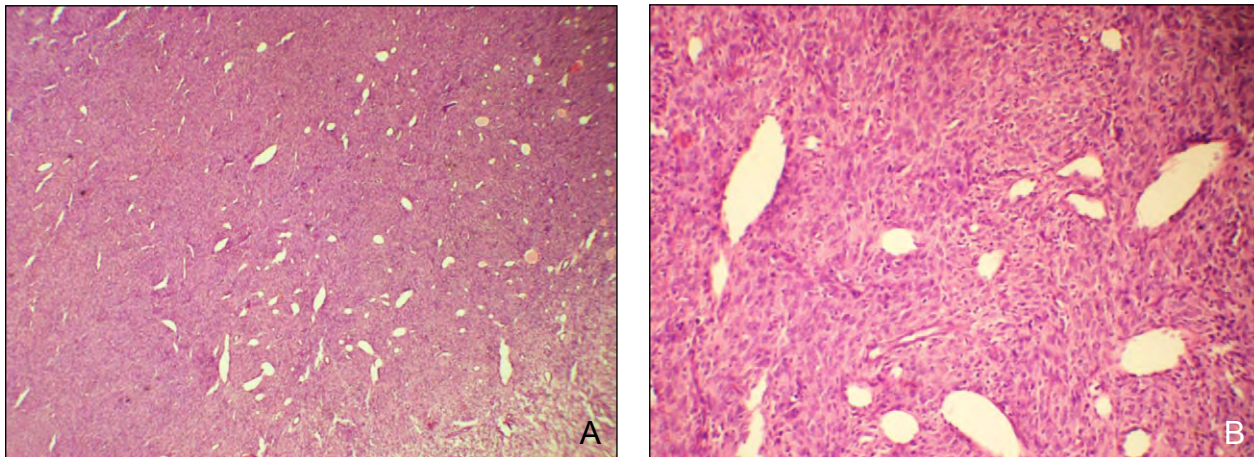
A 6-month-old female infant presented with a hemorrhagic and ulcerated mass over the right shoulder region. The mass initially started as a painful swelling that later ruptured and became ulcerated. Clinically, the mass measured 6×5 cm and was present over the right shoulder region, reaching the clavicle anteriorly and spine of scapula posteriorly. The lesion was highly vascular and reddish in color with irregular borders and areas of ulceration. Ultrasonography revealed a heterogeneous, lobulated, hypoechoic mass with increased vascularity. There also was evidence of effusion in the right shoulder joint. Clinical and radiological diagnosis suggested a hemangioma. Images were not taken because the lesion was clinically and radiologically characteristic of a benign vascular lesion.

The mass was surgically removed and sent for histopathologic examination. Grossly, the tumor was in multiple fragments measuring 6.5×5×4 cm. The tissue fragments were grey-white in color, focally encapsulated, and showed areas of congestion. Multiple sections showed a highly cellular tumor. The tumor cells were closely packed and present in fascicles with a prominent hemangiopericytomalike vascular pattern (Figure 1). The tumor showed minimal pleomorphism and high mitotic activity (1–4 per high-power field)(Figures 2A and 2B). Individual tumor cells were spindle-shaped with ovoid to spindle-shaped hyperchromatic nuclei and had variable amounts of tapering cytoplasm (Figure 1). There were focal chronic inflammatory cells and areas of necrosis were absent. Immunohistochemically, the tumor cells expressed vimentin (V9; 1:500 dilution; Santa Cruz Biotechnology, Inc) and were negative for CD34 (clone QBEnd 10; 1:50 dilution; DakoCytomation), smooth muscle actin (clone 1A4; 1:100 dilution; DakoCytomation), and S-100 protein (clone 15E2E2; 1:80 dilution; BioGenex

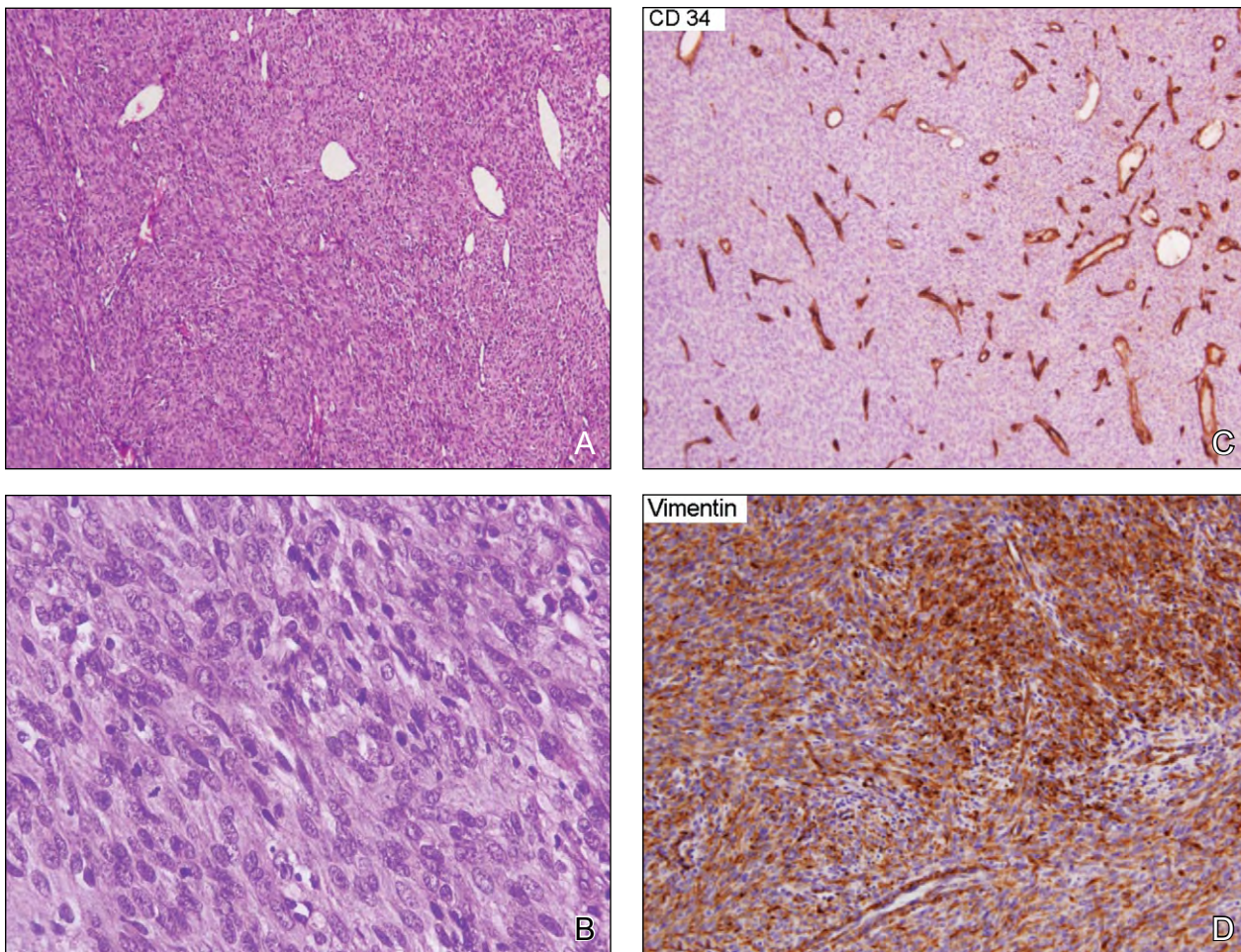
From the Department of Pathology, Maulana Azad Medical College, New Delhi, India.

The authors report no conflict of interest.

Correspondence: Deepali Jain, MD, Department of Pathology, Maulana Azad Medical College, New Delhi, India 110002 (deepaljain76@gmail.com).



**Figure 1.** Histology of the tumor showed high cellularity and pleomorphic, small to large spindle cells arranged in fascicles with a prominent hemangiopericytomalike appearance (A and B)(H&E; original magnifications  $\times 40$  and  $\times 200$ , respectively).



**Figure 2.** Photomicrograph showed tumor cells (A) with individual cell pleomorphism and mitosis (B)(H&E; original magnifications  $\times 40$  and  $\times 400$ , respectively). Immunohistochemistry revealed CD34 positivity in blood vessels (C) (original magnification  $\times 40$ ); however, tumor cells were positive for vimentin diffusely (D)(original magnification  $\times 200$ ).



Laboratories, Inc)(Figures 2C and 2D). Based on these findings, a final diagnosis of CIFS was made.

### Comment

Congenital infantile fibrosarcoma is a malignant soft tissue tumor that clinically presents as a mass lesion ranging in size from 1 to 20 cm.<sup>4</sup> The distal segments of the limbs are described as the most frequently involved sites (71%), whereas axial locations represent only 29% of cases.<sup>5</sup> However, in our patient, the lesion was present at the shoulder region, infiltrating into the joint cavity. More than 300 cases of CIFS have been reported in the literature but few have been reported as a clinical mimicker of congenital hemangiomas.<sup>2,3</sup> Congenital infantile fibrosarcoma may mimic hemangioma clinically, but the disease courses vary. Features that are similar to both

congenital hemangiomas and CIFS include occurrence of both in neonates; history of rapid growth; vascular, sometimes hemorrhagic, appearance; and consumption coagulopathy.<sup>2</sup> Regrettably, radiologic imaging techniques have shown poor discrimination between highly vascularized CIFS and congenital hemangiomas.<sup>6</sup> Magnetic resonance imaging (MRI) for CIFS depicts a well-circumscribed mass that is isointense on T1-weighted MRI and hyperintense on T2-weighted MRI because of a high cellular component. Sometimes CIFS may appear heterogeneous, septate, and strongly enhanced.<sup>6</sup> There are various differentiating features between CIFS and congenital hemangiomas that can help clinicians to make an accurate diagnosis (Table). However, none of the clinical features are specific for either CIFS or congenital hemangioma in an individual case. Likewise,

### Clinicopathological Differences Between CIFS and CH

Features	CIFS	CH
Age at presentation	Uncommon tumor; one-third to more than half of these lesions are present at birth	Most common tumor of infancy; usually appears in the first weeks of life
Sex	More likely in males	More likely in females
Site	Head, neck, limbs	Extremities, trunk, head, neck
Consistency	Firm, shiny	Softer and compressible
Clinical presentation	Spherical and protruding; poorly circumscribed; infiltrative; often fixed to underlying tissues; light grey	Plaquelike with lobular borders; well-circumscribed; mobile
Histopathology	Sheets of small, uniform, solidly packed spindle cells; collagen and mitotic figures; richly vascular areas	Distinctly lobulated with centrally located feeder vessels
Immunohistochemistry	Vimentin	CD34
Cytogenetics	t(12;15)(p13;q26) and <i>ETV6-NTRK3</i> fusion positive	Negative
Treatment	Surgery, chemotherapy; may regress	Resection; spontaneous regression in most cases

Abbreviations: CIFS, congenital infantile fibrosarcoma; CH, congenital hemangioma; *ETV6*, ets variant 6; *NTRK3*, neurotrophic tyrosine kinase receptor, type 3.

in our patient, the lesion was diagnosed as a vascular lesion. It is to be noted that the index patient was female and the lesion was not present at the time of birth. Therefore, histopathology is always important to make the correct diagnosis. Both the clinician and pathologist should be aware that CIFS can present as a subtle benign vascular lesion. There should be a high index of suspicion for CIFS, as prognosis differs from benign hemangiomas.

Histologic mimickers of CIFS include infantile fibromatosis, particularly a cellular variant; inflammatory myofibroblastic tumor if a prominent chronic inflammatory infiltrate is present<sup>7</sup>; and spindle cell variant of embryonal rhabdomyosarcoma. Immunohistochemically, the spindle cells of CIFS stain for vimentin and variably for muscle markers including muscle specific and smooth muscle actin. Desmin rarely is expressed.<sup>8</sup>

Congenital infantile fibrosarcomas are classified as low-grade sarcomas of fibroblastic/myofibroblastic differentiation. Ultrastructural examination reveals dilated rough endoplasmic reticulum, intracytoplasmic intermediate filaments, lysosomes, and focal basement membrane-like material.<sup>9</sup> Unfortunately, we could not perform cytogenetics and ultrastructural analysis in our patient due to a lack of facilities.

Congenital infantile fibrosarcomas are associated with a high risk for local recurrence in up to 50% of cases.<sup>4,5</sup> Surgical resection with a wide margin is the treatment of choice. Adjuvant chemotherapy has been advocated to reduce the risk for local recurrence and distant metastasis. The most common chemotherapy regimen consisted of vincristine, actinomycin D, and cyclophosphamide. In a few cases, ifosfamide is substituted for cyclophosphamide or doxorubicin for actinomycin D.<sup>10</sup> In our patient, surgical resection was performed due to the large size and deep infiltration. However, tumor margins were involved; therefore, the patient was referred to the tertiary center for close follow-up and further treatment.

## Conclusion

It is clear from this report that CIFS can clinically present as a hemangioma; therefore, histopathology is important to make the correct diagnosis, which is essential for the prognosis and treatment to be given.

## REFERENCES

1. Boon LM, Fishman SJ, Lund DP, et al. Congenital fibrosarcoma masquerading as congenital hemangioma: report of two cases. *J Pediatr Surg.* 1995;30:1378-1381.
2. Yan AC, Chamlin SL. Congenital infantile fibrosarcoma: a masquerader of ulcerated hemangioma. *Pediatr Dermatol.* 2006;23:330-334.
3. Requena C, Miranda L, Cañete A, et al. Congenital fibrosarcoma simulating congenital hemangioma. *Pediatr Dermatol.* 2008;25:141-144.
4. Soule EH, Pritchard DJ. Fibrosarcoma in infants and children: a review of 110 cases. *Cancer.* 1997;40:1711-1721.
5. Blocker S, Koenig J, Ternberg J. Congenital fibrosarcoma. *J Pediatr Surg.* 1987;22:665-670.
6. Canale S, Vanel D, Couanet D, et al. Infantile fibrosarcoma: magnetic resonance imaging findings in six cases [published online ahead of print June 11, 2009]. *Eur J Radiol.* 2009;72:30-37.
7. Sheng WQ, Hisaoka M, Okamoto S, et al. Congenital-infantile fibrosarcoma. a clinicopathologic study of 10 cases and molecular detection of the ETV6-NTRK3 fusion transcripts using paraffin-embedded tissues. *Am J Clin Pathol.* 2001;115:348-355.
8. Coffin CM, Jaszcz W, O'Shea PA, et al. So-called congenital-infantile fibrosarcoma: does it exist and what is it? *Pediatr Pathol.* 1994;14:133-150.
9. Argyle JC, Tomlinson GE, Stewart D, et al. Ultrastructural, immunocytochemical, and cytogenetic characterization of a large congenital fibrosarcoma. *Arch Pathol Lab Med.* 1992;116:972-975.
10. Kurkchubasche AG, Halvorson EG, Forman EN, et al. The role of preoperative chemotherapy in the treatment of infantile fibrosarcoma. *J Pediatr Surg.* 2000;35:880-883.



### NEED MORE INFORMATION?

Access articles in our Pediatric Dermatology department online at [www.cutis.com](http://www.cutis.com)

Use our Advanced Search to find articles online!