

Poromatosis in Pregnancy: A Case of 8 Eruptive Poromas in the Third Trimester

Jeffrey P. North, MD; Justin Lo, BS; Maeran Landers, MD

The poroid family of neoplasms includes hidroacanthoma simplex, eccrine poroma, dermal duct tumor, and poroid hidradenoma. These benign adnexal neoplasms are derived from the eccrine or apocrine sweat ducts or glands. Poroid neoplasms, including poromas, have been reported during pregnancy and have been hypothesized to be hormonally influenced. Poromatosis, the occurrence of multiple poromas, rarely has been reported in association with hidrotic ectodermal dysplasia, prior radiation therapy, and non-Hodgkin lymphoma occurring after chemotherapy. We report a case of eruptive poromatosis in pregnancy with 8 poromas occurring in the third trimester, further supporting the hypothesis of a hormonal association in the etiology of this neoplasm.

Cutis. 2012;89:81-83.

Case Report

A 33-year-old woman presented at 35 weeks' gestation with painful red papules on the arms, hands, and feet of 2 weeks' duration. These papules all appeared during the third trimester of her pregnancy. Her medical history was notable for melanoma of the leg and Hodgkin lymphoma treated with chemotherapy and an autologous stem cell transplant 15 years prior. Physical examination revealed 8 firm, flesh-colored to red papules measuring 1 to 4 mm: 1 on her left forearm, 2 on her right palm, 1 on her right lateral foot,

1 on her right fifth toe, 1 on her left volar forearm, and 2 on her left plantar foot (Figure, A and B).

Excisional punch biopsies from 2 papules demonstrated well-demarcated neoplasms in the superficial dermis comprised of monomorphic basaloid cells with multiple epidermal connections exhibiting duct formation consistent with the diagnosis of eccrine poromas (Figure, C and D). Scattered mitotic figures were present, but no significant cytologic atypia was noted. The 6 remaining papules were successfully treated with cryotherapy. There was no recurrence at 6 months postpartum.

Comment

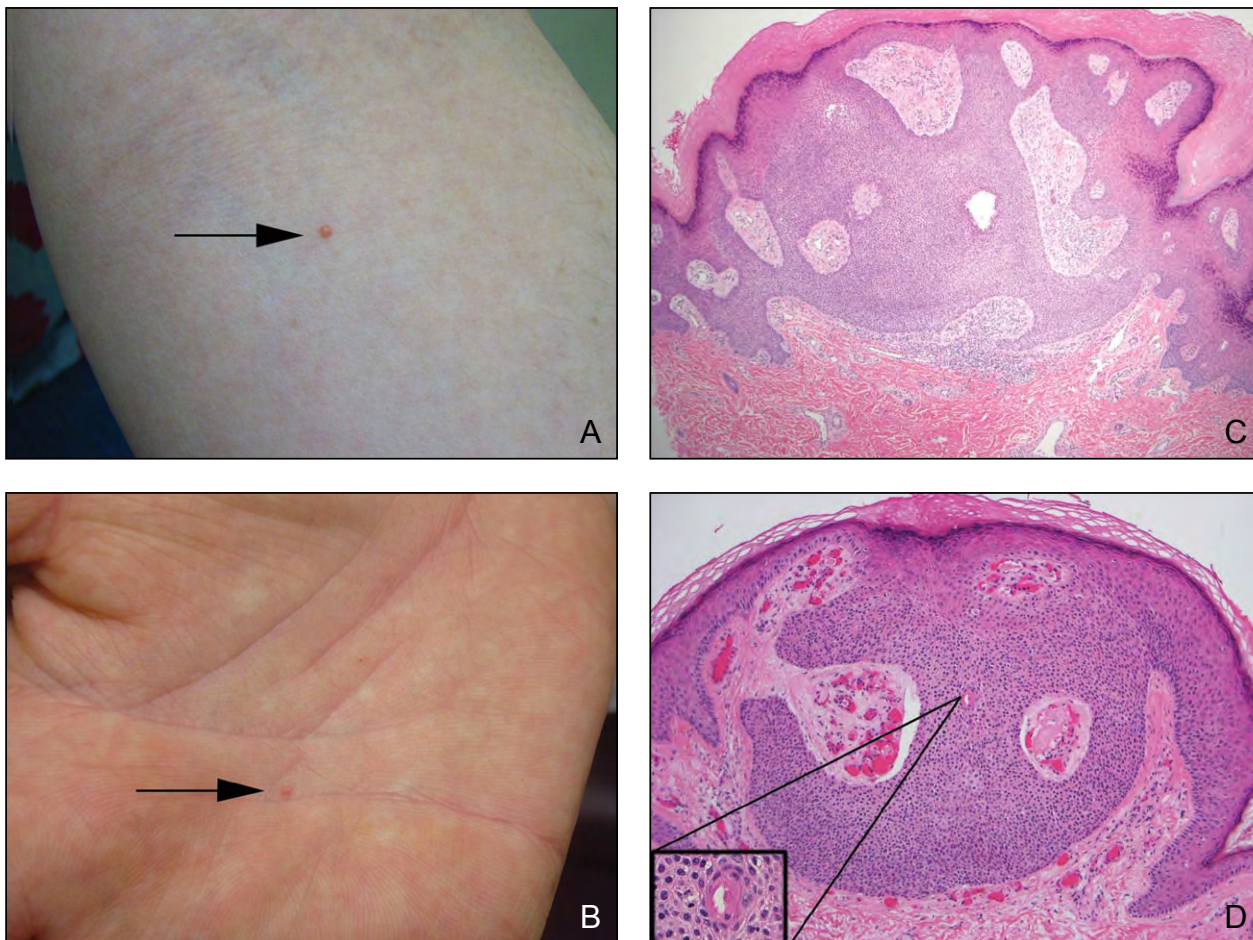
Poromas are benign adnexal neoplasms derived from the epithelium of sweat ducts of either eccrine or apocrine origin. There are 4 recognized types of poroid neoplasms: hidroacanthoma simplex, eccrine poroma, dermal duct tumor, and poroid hidradenoma.¹ A malignant poroid neoplasm with metastatic capability also exists. Eccrine poroma originally was described by Pinkus et al² and is characterized by collections of monomorphic, cuboidal, basophilic cells (poroid cells) in the superficial dermis with a variable degree of duct formation and broad epidermal connections. Dermal duct tumor and poroid hidradenoma are both nodular dermal neoplasms without epidermal connection, the former consisting of multiple nodules of poroid cells and the latter as a nodule of poroid cells with solid and cystic components. Hidroacanthoma simplex is differentiated from others by its intraepidermal location.

The derivation of poromas (eccrine vs apocrine) is somewhat controversial.³ For decades, poromas were thought to derive from the acrosyringium (intraepidermal portion of the eccrine sweat duct). However, as more cases have emerged with elements of sebaceous or follicular differentiation, the possibility that poromas also arise from apocrine ducts has gained

From the Department of Dermatology, Oregon Health & Science University, Portland.

The authors report no conflict of interest.

Correspondence: Jeffrey P. North, MD, 3303 SW Bond Ave, CH16D, Portland, OR 97239 (jeffreypaulnorth@gmail.com).



Eruptive poromas (arrows)(A and B). Histology showed adnexal neoplasms with monomorphic basaloid cell populations and multiple epidermal connections (C)(H&E, original magnification $\times 40$). Prominent ductules were present (inset)(D)(H&E, original magnification $\times 100$).

popularity because the apocrine sweat unit, sebaceous gland, and hair follicle all derive from the same embryologic bud, while the eccrine sweat unit derives from a separate embryologic epithelial bud.

Poromas typically present as solitary papules, plaques, or nodules, often on acral skin where eccrine ducts are abundant, but they also have been reported on the head, face, trunk, and anogenital regions. Poromas can be flesh colored or red due to a highly vascularized stroma that gives them an appearance similar to a pyogenic granuloma. They occasionally present as pigmented lesions. Although most poromas occur in adults with no sexual or racial predilection, they also can occur in children.

Solitary poromas have been reported in association with radiation therapy,⁴ nevus sebaceus,⁵ trauma/burns,⁶⁻⁸ and basal cell nevus syndrome.⁹ Poromatosis, the occurrence of multiple poromas, rarely has

been reported in patients with hidrotic ectodermal dysplasia, prior radiation therapy, and non-Hodgkin lymphoma occurring after chemotherapy.¹⁰⁻¹⁴ A linear variant also has been described.¹⁵

Solitary poromas also have been reported in pregnancy¹⁶⁻¹⁸ as well as malignant eccrine poroma.¹⁹ Ban and Kitajima¹⁶ and Guimerá Martín-Neda et al¹⁸ discussed the possibility of hormonal changes during pregnancy, which predisposes patients to the development of poromas; however, according to a PubMed search of articles indexed for MEDLINE using the terms *poroma and pregnancy* as well as *poromatosis*, no cases of poromatosis in pregnancy have been reported.

Conclusion

We report a case of eruptive poromatosis in pregnancy with 8 poromas occurring in the third trimester,

lending further support to a potential hormonal contribution in the pathogenesis of poromas.

REFERENCES

1. Abenozza P, Ackerman AB. Poromas. In: Abenozza P, ed. *Neoplasms With Eccrine Differentiation*. Philadelphia, PA: Lea & Febiger; 1990:113-186.
2. Pinkus H, Rogin JR, Goldman P. Eccrine poroma; tumors exhibiting features of the epidermal sweat duct unit. *AMA Arch Derm*. 1956;74:511-521.
3. Harvell JD, Kerschmann RL, LeBoit PE. Eccrine or apocrine poroma? six poromas with divergent adnexal differentiation. *Am J Dermatopathol*. 1996;18:1-9.
4. Sidro-Sarto M, Guimerá-Martin-Neda F, Perez-Robayna N, et al. Eccrine poroma arising in chronic radiation dermatitis (published online ahead of print May 6, 2008). *J Eur Acad Dermatol Venereol*. 2008;22:1517-1519.
5. Bonvalet D, Barrandon Y, Foix C, et al. Benign adnexal tumors of late occurrence in verrucoid-sebaceous nevus (Jadassohn). apropos of 7 cases [in French]. *Ann Dermatol Venereol*. 1983;110:337-342.
6. Wakamatsu J, Yamamoto T, Minemura T, et al. The occurrence of eccrine poroma on a burn site. *J Eur Acad Dermatol Venereol*. 2007;21:1128-1129.
7. Nemoto I, Akiyama M, Aoyagi S, et al. Eccrine porocarcinoma and eccrine poroma arising in a scar. *Br J Dermatol*. 2004;150:1232-1233.
8. Johnson RC, Rosenmeier G, Keeling JH 3rd. A painful step. eccrine poroma. *Arch Dermatol*. 1992;128:1530, 1533.
9. Groben PA, Hitchcock MG, Leshin B, et al. Apocrine poroma: a distinctive case in a patient with nevoid basal cell carcinoma syndrome. *Am J Dermatopathol*. 1999;21:31-33.
10. Navi D, Fung M, Lynch PJ. Poromatosis: the occurrence of multiple eccrine poromas. *Dermatol Online J*. 2008;14:3.
11. Wilkinson RD, Schopflocher P, Rozenfeld M. Hidrotic ectodermal dysplasia with diffuse eccrine poromatosis. *Arch Dermatol*. 1977;113:472-476.
12. Goldner R. Eccrine poromatosis. *Arch Dermatol*. 1970;101:606-608.
13. Kurokawa M, Amano M, Miyaguni H, et al. Eccrine poromas in a patient with mycosis fungoides treated with electron beam therapy. *Br J Dermatol*. 2001;145:830-833.
14. Ullah K, Pichler E, Fritsch P. Multiple eccrine poromas arising in chronic radiation dermatitis. *Acta Derm Venereol*. 1989;69:70-73.
15. Ogino A. Linear eccrine poroma. *Arch Dermatol*. 1976;112:841-844.
16. Ban M, Kitajima Y. A case of rapidly-growing eccrine poroma during pregnancy. *J Dermatol*. 1997;24:554-555.
17. Kircik L, Armus S, Kipping H, et al. Eccrine poroma in an unusual location. *Cutis*. 1994;54:183-184.
18. Guimerá Martín-Neda F, García Bustinduy M, Noda Cabrera A, et al. A rapidly growing eccrine poroma in a pregnant woman. *J Am Acad Dermatol*. 2004;50:124-126.
19. Kairi-Vassilatou E, Grapsa D, Dafnios N, et al. A malignant eccrine poroma in a pregnant woman: case report and review of the literature. *Eur J Gynaecol Oncol*. 2007;28:421-422.



NEED MORE INFORMATION?

Access this related article in our online archives at www.cutis.com

▼ An Unusually Large Eccrine Poroma: A Case Report and Review of the Literature

Use our Advanced Search to find this article and more online!