

Series Editor: Camila K. Janniger, MD

# Burkitt Lymphoma in a Child With Atopic Dermatitis and a 7-Year History of Regular Topical Tacrolimus Use

Latawnya Pleasant, MD; Sean Skinner, MD; Joseph Pulliam, MD; Harigovinda Challa, MD; John D'Orazio, MD, PhD

*We describe the case of a boy who presented with abdominal Burkitt lymphoma; he had been regularly using tacrolimus ointment 0.1% for severe recurrent atopic dermatitis for 7 years immediately prior to developing cancer. We present his medical history and review the current knowledge regarding a link between topical tacrolimus and malignancy risk.*

*Cutis.* 2012;89:117-120.

## Case Report

A previously healthy 11-year-old boy presented with decreased appetite, intermittent abdominal pain, and 10-lb weight loss in the last month. An abdominal computed tomography scan revealed an ileocecal intussusception (Figure 1) and the child was referred to the pediatric surgical service for further management. His medical history was relevant for recurrent severe atopic dermatitis of 7 years' duration, which was treated with tacrolimus ointment 0.1% applied to the skin behind the ears, in the flexor creases of the elbows and knees extending to the flexor surfaces of the arms and legs, and to the skin immediately surrounding the eyes. Topical tacrolimus was used on average twice daily for 3 to 4 days every 2 weeks for 7 years prior to presentation. The child's atopic dermatitis responded well to the tacrolimus each time it was used. We estimate that he had received

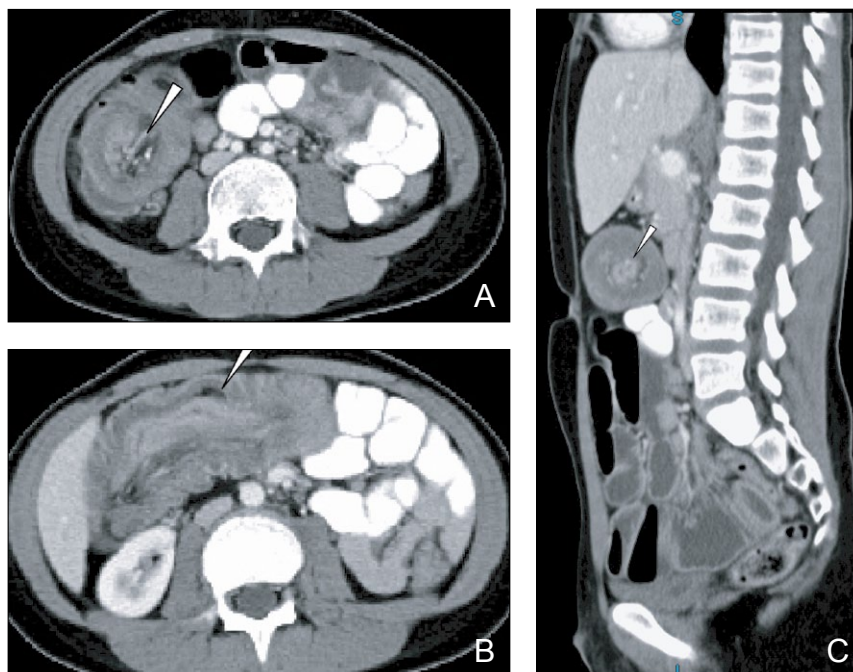
approximately 12 to 15 doses applied to roughly 10% of his body surface area monthly for 7 years. Otherwise, his medical history was unremarkable. There was neither a history of serious infections nor pertinent family medical history.

The patient was stable on arrival. Vital signs included a temperature of 36.7°C, a regular pulse of 115 beats per minute (reference range, 60–96 beats per minute), regular respirations of 30 breaths per minute (reference range, 14–22 breaths per minute), and a blood pressure of 129/73 mm Hg (reference range, 100–120/60–75 mm Hg). The patient's oxygen saturation was 97% on room air as measured by pulse oximetry. Height (162 cm; >95th percentile for age) and weight (52 kg; 90th–95th percentile for age) were appropriate. The patient was well-developed, nondysmorphic, alert, oriented, and cooperative. We noted lichenified and somewhat hypopigmented skin around the eyes, behind the ears, and in the flexor surfaces behind the elbows and knees, consistent with chronic atopic dermatitis. Physical examination was most notable for abdominal tenderness and fullness localized to the right lower quadrant with diminished bowel sounds. There was no hepatosplenomegaly and the remainder of the physical examination, including heart, lung, and neurologic examinations, did not reveal any abnormalities. There was no abnormal lymphadenopathy, cyanosis, edema, petechiae, or ecchymoses. The white blood cell count was 10,400 cells/ $\mu$ L (reference range, 4500–11,000 cells/ $\mu$ L; 65% segmented neutrophils [reference range, 36%–74%]; 24% lymphocytes [reference range, 14%–48%]; 8% monocytes [reference range, 4%–9%]; 2% eosinophils [reference range, 0.5%–5%]; and 1% basophils [reference range, 0%–1%]), the hemoglobin level was 13.3 g/dL (reference range, 14.0–17.5 g/dL), the hematocrit was 38.5% (reference range, 41%–50%),

From the University of Kentucky College of Medicine, Lexington. Drs. Pleasant and D'Orazio are from the Department of Pediatrics, Dr. Skinner is from the Department of Surgery, Dr. Pulliam is from the Department of Pathology, and Dr. Challa is from the Department of Radiology.

The authors report no conflict of interest.

Correspondence: John D'Orazio, MD, PhD, University of Kentucky College of Medicine, Markey Cancer Center, Combs Research Building, 800 Rose St, Lexington, KY 40536-0096 (jdorazio@uky.edu).



**Figure 1.** Abnormal computed tomography showed transverse (A and B) and longitudinal (C) views of intussusception. Areas demonstrating the tumor and associated intussusception are indicated by the white arrowheads. Extension of ileocecal intussusception into the transverse colon was noted (B).

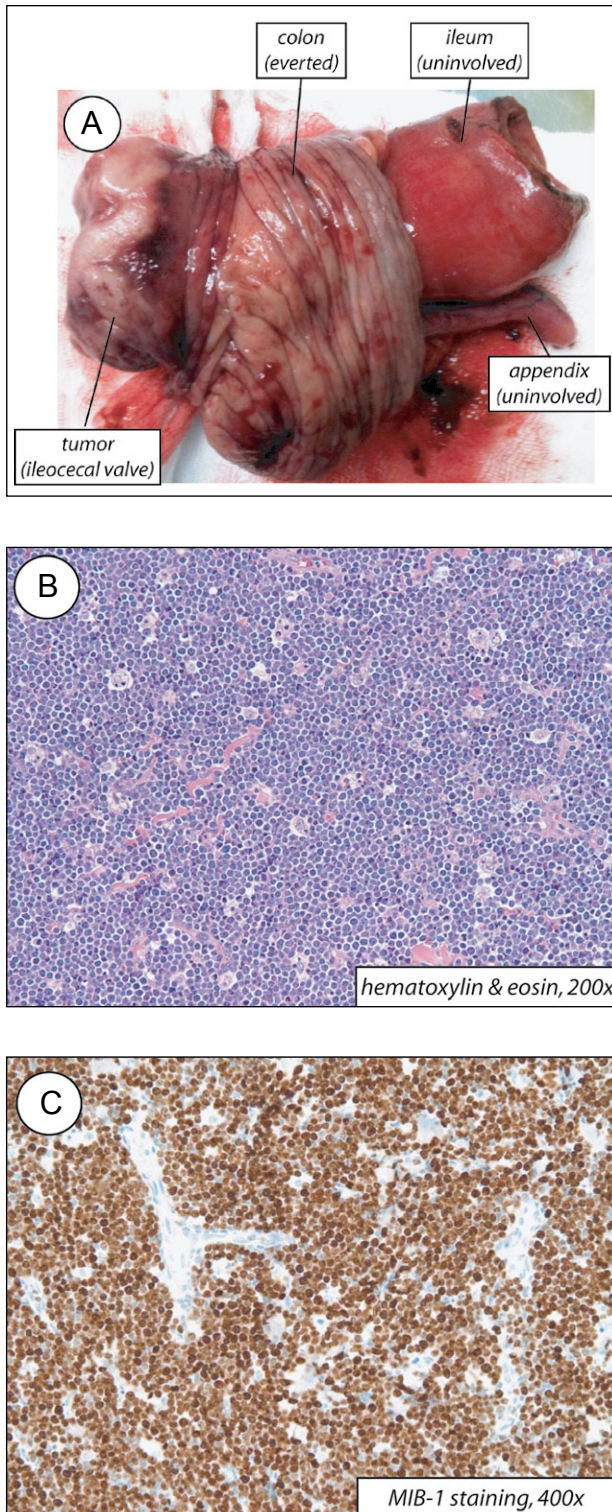
the mean corpuscular volume was 84 fL (reference range, 80–100 fL), and the platelet count was 329,000/ $\mu$ L (reference range, 150,000–350,000/ $\mu$ L). Electrolyte panel and liver function tests revealed no abnormalities; serum lactate dehydrogenase was 137 U/L (reference range, 100–200 U/L) and serum uric acid was 1.3 mg/dL (reference range, 4.0–8.0 mg/dL). Total protein and albumin levels were low at 3.8 g/dL (reference range, 6.0–8.0 g/dL) and 1.3 g/dL (reference range, 3.5–5.0 g/dL), respectively. Serum blood urea nitrogen and creatinine levels were 7 mg/dL (reference range, 8–23 mg/dL) and 0.48 mg/dL (reference range, 0.6–1.2 mg/dL), respectively.

Because intussusception in older children frequently is associated with diseases that require surgical intervention (eg, tumors, polyps), the patient was taken immediately to the operating room for abdominal surgery. Laparoscopic exploration revealed a 5.1 $\times$ 4 $\times$ 2.5-cm mass involving the ileocecal valve that served as the lead point for the ileocecal intussusception. The tumor was resected en bloc along with the distal ileum, ileocecal valve, appendix, and proximal large intestine (Figure 2A). The mass was comprised of a monotonous population of atypical lymphocytes with frequent mitoses and scattered tangible body macrophages, which gave the typical starry sky appearance of Burkitt lymphoma within the ileocecal valve (Figure 2B). Immunohistochemistry and flow cytometry revealed a monoclonal lambda restricted B-lymphocyte population with markedly increased proliferation index (>95%) (normal, <5%) by MIB-1 staining (Figure 2C). Fluorescence in situ hybridization studies confirmed at

(8;14)(q24;q32) IgH-Myc translocation. The tumor was negative for Epstein-Barr virus (EBV) by in situ hybridization testing, and serologic studies were negative for both EBV and cytomegalovirus. Fifteen associated lymph nodes removed at the time of surgery were found to be uninvolved by tumor. Together, the pathologic analysis was consistent with a diagnosis of localized ileocecal Burkitt lymphoma. The patient's recovery was complicated by abdominal abscess and wound dehiscence, which were treated with prolonged antibiotic administration and optimal wound management. The patient's malignant staging workup, which included bone marrow aspiration and biopsy, cerebrospinal fluid examination, and computed tomography and positron emission tomography, was negative. Thus according to the Murphy staging criteria, the patient was diagnosed with completely resected stage II abdominal Burkitt lymphoma and was treated according to the Children's Cancer Group Study CCG-5961 (Group A) oncology protocol.<sup>1</sup> He received his first dose of chemotherapy 10 days after surgery without complication and was subsequently treated with 2 cycles of cyclophosphamide, doxorubicin, vincristine, and prednisone (CHOP). He has since recovered fully and is free of disease, now 20 months after diagnosis. The patient's atopic dermatitis has abated and is now managed with skin moisturizers and judicious topical steroid use.

### Comment

Burkitt lymphoma is a malignant neoplasm of lymphoid lineage.<sup>2</sup> It is one of the most commonly



**Figure 2.** The freshly excised intussuscepted portion of the terminal ileum and proximal right colon demonstrated a large tumor at the ileocecal valve (A). Histopathology of the patient's tumor showed the typical starry sky appearance of Burkitt lymphoma (B)(H&E, original magnification  $\times 200$ ) and strongly positive MIB-1 staining of the tumor (C)(original magnification  $\times 400$ ), indicating a high rate of proliferation.

diagnosed non-Hodgkin lymphomas of childhood, occurring in at least 3 distinct clinical patterns: endemic, sporadic, and human immunodeficiency virus related. Endemic Burkitt lymphoma, typically presenting as fast-growing tumors of the jaw, occurs mainly in equatorial Africa and South America. Almost 95% of endemic Burkitt lymphoma isolates bear evidence of EBV incorporated into the tumor genome, establishing a clear link between this malignancy and EBV. In contrast, the EBV genome is found in only 10% to 15% of cases of sporadic Burkitt lymphoma. Sporadic Burkitt lymphoma occurs in North American and European populations and presents mainly as extraosseous tumors, most often in the abdomen. Human immunodeficiency virus-related Burkitt lymphoma, presumably caused by T-cell deficiency, is EBV positive in up to 70% of cases. Thus EBV infection has a known association with Burkitt lymphoma, though this malignancy can occur independently of EBV.<sup>2</sup> Epstein-Barr virus did not appear to play a role in our patient's tumor, as no evidence of EBV was found in the tumor sample.

Atopic dermatitis is a waxing and waning pediatric inflammatory skin disorder characterized by pruritus, risk for superinfection, and variable severity. Because of its tendency to involve multiple anatomic areas and to relapse, there is a great need for safe treatments that can be used repeatedly in children. For many patients, atopic dermatitis can be managed by avoiding known triggers and by optimizing skin hydration with topical emollients and prudent bathing practices. However, more severe or refractory disease, as in our patient, often requires more aggressive therapies. Immunosuppressive agents, especially those that interfere with T lymphocyte function, are particularly useful in controlling recalcitrant disease, underscoring the central role of inappropriate immune activation in this disorder.<sup>3</sup> Topical corticosteroids, often used as front-line agents, are highly effective but interfere with dermal collagen synthesis and thus can cause skin atrophy when used repeatedly in the same sites over time.<sup>4</sup> For this reason, many practitioners prefer steroid-sparing topical agents in patients with atopic dermatitis that requires frequent treatment.

Tacrolimus, isolated in the early 1980s from the broth of the soil fungus *Streptomyces tsukubaensis*, inhibits helper T cell function by interfering with the calcineurin signaling pathway.<sup>5</sup> It has proven to be effective against a host of immune-mediated diseases including solid organ graft rejection, graft-versus-host disease, and atopic dermatitis. However, as tacrolimus and other calcineurin inhibitors (eg, sirolimus, pimecrolimus) became more widely used, it was appreciated that patients, mainly solid organ transplant recipients, taking regular intravenous or oral

preparations of these agents for long periods of time were at an increased risk for malignancies including skin cancers, lymphoproliferative disorders, and lymphomas.<sup>5</sup> Because of these clinical observations, concerns arose surrounding the safety of topically applied preparations of these drugs, especially in pediatric patients. At least 2 factors place children at higher risk for systemic immunosuppression from topically applied agents. First, children have a higher body surface area to body mass ratio, which favors more systemic absorption. Second, the epidermal barrier is most permeable in childhood<sup>6</sup> and in inflammatory conditions such as atopic dermatitis.<sup>7</sup> Although it is likely that the majority of children who are treated with topical calcineurin inhibitors have very low systemic absorption, as measured by serum drug concentration,<sup>8</sup> there is at least 1 documented report of a child with particularly widespread atopic dermatitis treated with tacrolimus ointment who demonstrated serum levels of tacrolimus approaching those obtained in transplant patients taking oral tacrolimus for control of graft rejection.<sup>9</sup> In 2006, the US Food and Drug Administration issued a black-box warning regarding the long-term safety of topical calcineurin antagonists and recommended that patients with inflammatory skin disorders use these agents only for short periods of time and in the minimal amount required to control symptoms. The US Food and Drug Administration also cautioned against the use of topical calcineurin inhibitors in children younger than 2 years or in individuals with preexisting immunodeficiency.<sup>10</sup> Several retrospective clinical studies suggest that topical tacrolimus is safe for use and does not increase risk for malignancy in most children.<sup>11-16</sup> However, there have been no large-scale randomized trials designed to carefully determine if application of the drug to a large amount of body surface area repeatedly over time in children is associated with systemic immunosuppression and subsequent risk for infection or malignancy. Although we realize that many cases of pediatric Burkitt lymphoma are sporadic and random, our patient's regular exposure to tacrolimus ointment 0.1% applied to a substantial body surface area of inflamed skin for 7 years' duration immediately prior to his presentation of abdominal pain raises the possibility that tacrolimus use may have contributed at least in part to the development of malignancy in his case. Although it would likely require a large number of patients to be adequately powered, a randomized controlled study investigating factors such as patient age, extent of body surface area involved, formulation (cream vs ointment), and dosing patterns would be of great benefit in determining the safety of regular topical calcineurin use in children.

## REFERENCES

1. Lones MA, Auperin A, Raphael M, et al. Mature B-cell lymphoma/leukemia in children and adolescents: intergroup pathologist consensus with the revised European-American lymphoma classification. *Ann Oncol.* 2000;11:47-51.
2. Reiter A, Ferrando AA. Malignant lymphomas and lymphadenopathies. In: Orkin SH, Fisher DE, Look AT, et al, eds. *Oncology of Infancy and Childhood*. Philadelphia, PA: Saunders Elsevier; 2009:417-505.
3. Simpson EL. Atopic dermatitis: a review of topical treatment options. *Curr Med Res Opin.* 2010;26:633-640.
4. Henge UR, Ruzicka T, Schwartz RA, et al. Adverse effects of topical glucocorticosteroids. *J Am Acad Dermatol.* 2006;54:1-15.
5. Jonas S, Bechstein WO, Rayes N, et al. Posttransplant malignancy and newer immunosuppressive protocols after liver transplantation. *Transplant Proc.* 1996;28:3246-3247.
6. Giusti F, Martella A, Bertoni L, et al. Skin barrier, hydration, and pH of the skin of infants under 2 years of age. *Pediatr Dermatol.* 2001;18:93-96.
7. Addor FA, Aoki V. Skin barrier in atopic dermatitis. *An Bras Dermatol.* 2010;85:184-194.
8. Krueger GG, Eichenfield L, Goodman JJ, et al. Pharmacokinetics of tacrolimus following topical application of tacrolimus ointment in adult and pediatric patients with moderate to severe atopic dermatitis. *J Drugs Dermatol.* 2007;6:185-193.
9. McCollum AD, Paik A, Eichenfield LF. The safety and efficacy of tacrolimus ointment in pediatric patients with atopic dermatitis. *Pediatr Dermatol.* 2010;27:425-436.
10. Fonacier L, Charlesworth EN, Spergel JM, et al. The black box warning for topical calcineurin inhibitors: looking outside the box. *Ann Allergy Asthma Immunol.* 2006;97:117-120.
11. Thaçi D, Salgo R. Malignancy concerns of topical calcineurin inhibitors for atopic dermatitis: facts and controversies. *Clin Dermatol.* 2010;28:52-56.
12. Remitz A, Reitamo S. Long-term safety of tacrolimus ointment in atopic dermatitis. *Expert Opin Drug Saf.* 2009;8:501-506.
13. Hui RL, Lide W, Chan J, et al. Association between exposure to topical tacrolimus or pimecrolimus and cancers [published online ahead of print November 10, 2009]. *Ann Pharmacother.* 2009;43:1956-1963.
14. Patel TS, Greer SC, Skinner RB Jr. Cancer concerns with topical immunomodulators in atopic dermatitis: overview of data and recommendations to clinicians. *Am J Clin Dermatol.* 2007;8:189-194.
15. Arellano FM, Wentworth CE, Arana A, et al. Risk of lymphoma following exposure to calcineurin inhibitors and topical steroids in patients with atopic dermatitis [published online ahead of print November 9, 2006]. *J Invest Dermatol.* 2007;127:808-816.
16. Kang S, Lucky AW, Pariser D, et al. Long-term safety and efficacy of tacrolimus ointment for the treatment of atopic dermatitis in children. *J Am Acad Dermatol.* 2001;44(suppl 1):S58-S64.