

What's Eating You? The Sticktight Flea (*Echidnophaga gallinacea*)

Roger Kapoor, MD, MBA; Dirk M. Elston, MD

Laterally compressed bodies and large hind legs characterize all fleas. Unlike the dog and cat fleas, the sticktight flea (*Echidnophaga gallinacea*) (Figures 1 and 2) lacks genal (mustache area) and pronotal (back of head) ctenidia (combs) and is less than half the size of the cat flea (Figure 3). Unlike the *Xenopsylla* flea, the sticktight flea has no pleural rod (a vertical rod visible within the mesopleuron above the second pair of legs). Additional features include a head that is flattened anteriorly and 2 pairs of setae (hairs) found behind the antennae. True to its name, the sticktight flea has the ability to tightly stick to its host through broad and serrated laciniae (stiletto-shaped cutting extensors of the maxilla).

Echidnophaga gallinacea infests a wide variety of birds and mammals worldwide, and while it is mainly a poultry flea, it is becoming more common on dogs.¹⁻³ It has a predilection to attach to bare spots on the skin (eg, eyes, anus). It is the only species in the genus found in North America, especially in the southern and western United States, and has been noted to be the most common flea on dogs in areas of South Africa. It also is becoming more common on dogs in the United States.⁴⁻⁷ In New Mexico, *E gallinacea* can be found on cottontail rabbits, while in Angola it can be found on rodents.^{8,9} A report of a sticktight flea found on the cheek of a 2-year-old boy in Los Angeles, California, also was reported.¹⁰ Public health significance relates to its ability to serve as a vector for the plague and murine typhus as well as



Figure 1. The sticktight flea (*Echidnophaga gallinacea*).

an intermediate host of the dog tapeworm. Because this flea is increasingly recognized as a common flea on wild animals and domestic pets, it represents an important disease vector.

Flea bites can cause irritation to cats, dogs, rabbits, rodents, horses, and humans, resulting in pruritic papules and vesicles on the exposed areas of the upper and lower extremities. Severe bites also may result in bullous lesions. In birds, swelling and ulceration may result. Young birds may die from intense infestations, either from anemia or starvation; eyelid swelling may inhibit the bird's ability to hunt for food. In humans, the affected areas commonly correspond to exposed areas while handling infested animals. *Echidnophaga gallinacea* fleas are wingless and therefore can affect areas on the body that are within jumping height of carpets and furniture. Once on an incidental host, the flea tends to remain on the host for a prolonged period of time and can be somewhat difficult to remove as it embeds its head into the host's flesh.

Dr. Kapoor is from the Department of Dermatology, Massachusetts General Hospital, Harvard Medical School, Boston. Dr. Elston was from the Departments of Dermatology and Pathology, Geisinger Medical Center, Danville, Pennsylvania, and currently is from Ackerman Academy of Dermatopathology, New York, New York. The authors report no conflict of interest.

Correspondence: Dirk M. Elston, MD, Ackerman Academy of Dermatopathology, 145 E 32nd St, 10th Floor, New York, NY 10016 (delston@dermpathdiagnostics.com).

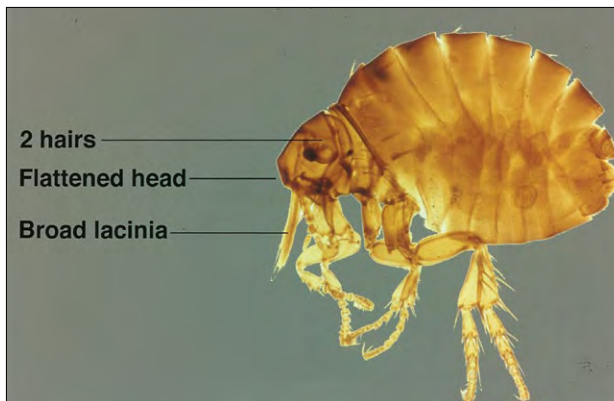


Figure 2. Distinguishing features of the sticktight flea (*Echidnophaga gallinacea*).



Figure 3. Distinguishing features of the cat flea.

Histopathologic examination of a flea bite reveals a wedge-shaped, perivascular, dermal infiltrate with scattered eosinophils. Endothelial swelling is prominent and vesicles and/or bullae may be present.

Treatment often is challenging, as the flea attaches tightly with its laciniae and may embed its head into the flesh of the host. Nevertheless, fleas can be removed with firm grasping and pulling with tweezers. When numerous fleas are present, malathion 5% liquid or gel has been topically applied. Insecticides utilized to treat outdoor animal pens are available to prevent the risk for reinfestation.¹¹ Dichlorovos and propetamphos demonstrate superior activity on

hard surfaces, while organophosphates are superior for fabric and carpet. Pets should be treated by a knowledgeable veterinarian. Agents that have been used include fipronil, selamectin, imidacloprid, metaflumizone, nitenpyram, lufenuron, methoprene, and pyriproxyfen. Lufenuron must be ingested by the larvae of the fleas to be effective, while methoprene and pyriproxyfen require only surface contact.¹¹

REFERENCES

1. Harman DW, Halliwell RE, Greiner EC. Flea species from dogs and cats in north-central Florida. *Vet Parasitol.* 1987;23:135-140.
2. Kalkofen UP, Greenberg J. *Echidnophaga gallinacea* infestation in dogs. *J Am Vet Med Assoc.* 1974;165:447-448.
3. Patrick MJ, Harrison RL. Fleas on gray foxes in New Mexico. *J Med Entomol.* 1995;32:201-204.
4. Rautenbach GH, Boomker J, de Villiers IL. A descriptive study of the canine population in a rural town in southern Africa. *J S Afr Vet Assoc.* 1991;62:158-162.
5. Beard CB, Butler JF, Hall DW. Prevalence and biology of endosymbionts of fleas (Siphonaptera: Pulicidae) from dogs and cats in Alachua County Florida. *J Med Entomol.* 1990;27:1050-1061.
6. Boughton RK, Atwell JW, Schoech SJ. An introduced generalist parasite, the sticktight flea (*Echidnophaga gallinacea*), and its pathology in the threatened Florida scrub-jay (*Aphelocoma coerulescens*). *J Parasitol.* 2006;92:941-948.
7. Durden LA, Judy TN, Martin JE, et al. Fleas parasitizing domestic dogs in Georgia, USA: species composition and seasonal abundance [published online ahead of print April 14, 2005]. *Vet Parasitol.* 2005;130:157-162.
8. Pfaffenberger GS, Valencia VB. Ectoparasites of sympatric cottontails (*Sylvilagus audubonii* Nelson) and jack rabbits (*Lepus californicus* Mearns) from the high plains of Eastern New Mexico. *J Parasitol.* 1988;74:842-846.
9. Linardi PM, Gomes AF, Botelho JR, et al. Some ectoparasites of commensal rodents from Huambo, Angola. *J Med Entomol.* 1994;31:754-756.
10. Carlson JC, Fox MS. A sticktight flea removed from the cheek of a two-year-old boy from Los Angeles. *Dermatol Online J.* 2009;15:4.
11. Gyimesi ZS, Hayden ER, Greiner EC. Sticktight flea (*Echidnophaga gallinacea*) infestation in a Victoria crowned pigeon (*Goura victoria*). *J Zoo Wildl Med.* 2007;38:594-596.