

Plantar Molluscum Contagiosum: A Case Report of Molluscum Contagiosum Occurring on the Sole of the Foot and a Review of the World Literature

Philip R. Cohen, MD; Jaime A. Tschen, MD

Molluscum contagiosum (MC) is a skin infection caused by the double-stranded DNA virus of the family Poxviridae that typically presents as flesh-colored asymptomatic umbilicated papules. Plantar MC is uncommon. We describe a 23-year-old man who presented with multiple plantar MC. We also summarize the epidemiologic features of the 34 previously reported patients with plantar MC and discuss the clinical characteristics, differential diagnosis, and treatment of plantar MC. The patients were immunocompetent and the median age at diagnosis was 21 years. Although the plantar MC were asymptomatic in some individuals, a common presenting symptom was pain while walking. Patients had 1 lesion (23/35), 2 lesions (5/35), 3 lesions (4/35), or more than 5 lesions (3/35). Giant MC (≥ 1 cm in diameter) was observed in more than 75% (a minimum of 27/35) of patients. At the initial patient evaluation, plantar verruca often was suspected; subsequently, light and/or electron microscopy of the plantar lesion confirmed the diagnosis of plantar MC. Removal or destruction of the lesion resulted in definitive treatment of the plantar MC.

Cutis. 2012;90:35-41.

Both from the Department of Dermatology, University of Texas Medical School, Houston. Dr. Cohen also is from the University of Houston Health Center, and the Department of Dermatology, University of Texas MD Anderson Cancer Center, Houston. Dr. Tschen also is from Saint Joseph Dermatopathology, Houston, and the Department of Dermatology, Baylor College of Medicine, Houston.

The authors report no conflict of interest.

Correspondence: Philip R. Cohen, MD, 805 Anderson St, Bellaire, TX 77401 (mitehead@gmail.com).

Molluscum contagiosum (MC) is a double-stranded DNA virus of the family Poxviridae that is spread by either skin-to-skin contact or less commonly fomite-to-skin contact and typically presents as flesh-colored, dome-shaped papules with a central depression.¹ The plantar surface of the foot is an atypical location for this viral skin infection. We describe a 23-year-old man with multiple plantar MC lesions on the sole of his right foot. The epidemiologic features of individuals with plantar MC are summarized and the clinical characteristics, differential diagnosis, and treatment of plantar MC are discussed.

Case Report

A healthy 23-year-old Indian man presented for evaluation of tender “dead skin” on the sole of his right foot that he noted 7 months prior to presentation. He previously wore flip-flop sandals but had to change his footwear when the lesions became painful while walking. Three months prior to presentation the plantar lesions began to grow more rapidly. Two months later a new asymptomatic papule appeared on the top of his right foot (Figure 1).

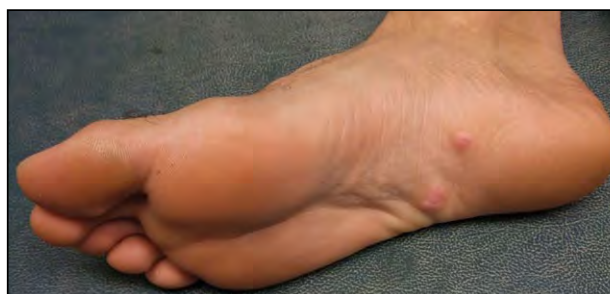

Figure 1. The patient's right foot with a small flesh-colored papule on the dorsal surface and 3 larger flesh-colored nodules on the ventral surface.

Plantar Molluscum Contagiosum

Examination showed 3 flesh-colored nodules with 1 or more well-circumscribed areas of depressed epidermis that extruded small amorphous-appearing material (consistent with molluscum bodies) from the epithelium on the plantar surface of his right foot in the area of the arch (Figure 2). One of the plantar lesions was medially located and measured 8×8 mm. The other 2 plantar lesions were adjacently located lateral to the center of the foot and each measured 8×6 mm. All 3 nodules were tender to palpation. An additional flesh-colored, dome-shaped, umbilicated papule also was present; it was asymptomatic, located

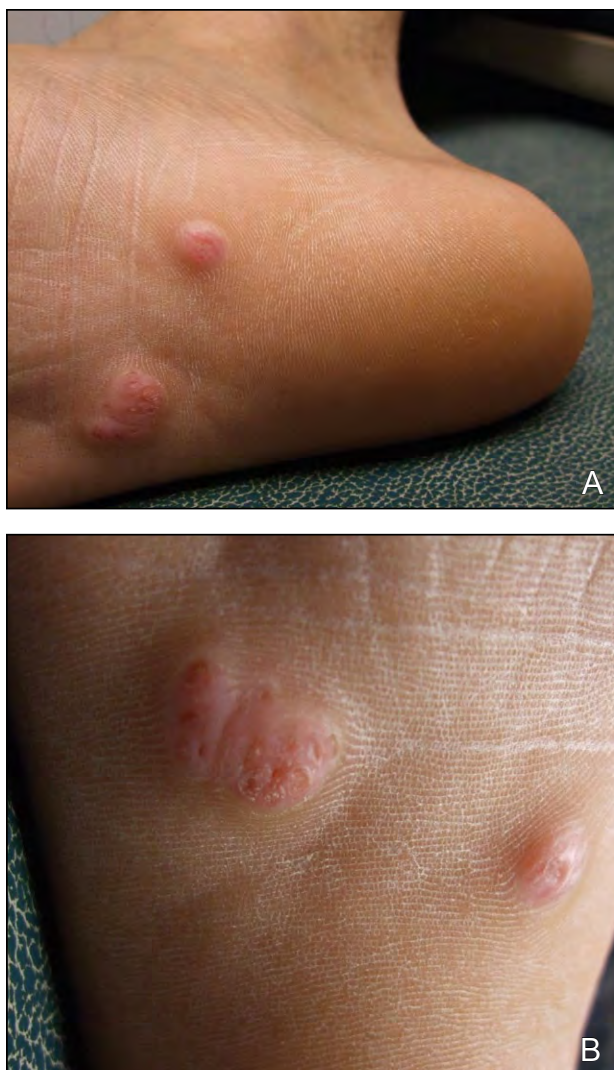


Figure 2. Plantar molluscum contagiosum on the right heel and sole presented as 3 flesh-colored nodules (A and B). The surface had 1 or more well-circumscribed areas of depressed epidermis that extruded small amorphous-appearing material (consistent with molluscum bodies) from the epithelium.

on the medial aspect of the right dorsal foot proximal to the great toe, and measured 5×3 mm (Figure 3).

The clinical impression of the dorsal papule was plantar MC. There were no similar-appearing lesions on the body. A diagnosis of plantar verruca or eccrine poroma was suspected of the nodular lesions on the sole of the foot; however, the lesions were larger and more exophytic than typical warts on the foot and the characteristic peripheral collarette of the epithelium that would suggest poroma was not present.

Using a razor blade, shave biopsies were performed of the dorsal papule on his right foot and of one of the lateral plantar nodules. The dorsal papule was completely removed in the tissue specimen. The plantar nodule was partially removed; the residual epithelium of the lesion that extended into the underlying dermis was easily extracted with forceps.

Both tissue specimens showed similar pathologic changes. There was compact orthokeratosis. In the dermis acanthotic lobules of the epidermis were present. The keratinocyte nuclei were displaced and compressed by the large cytoplasmic viral inclusion bodies

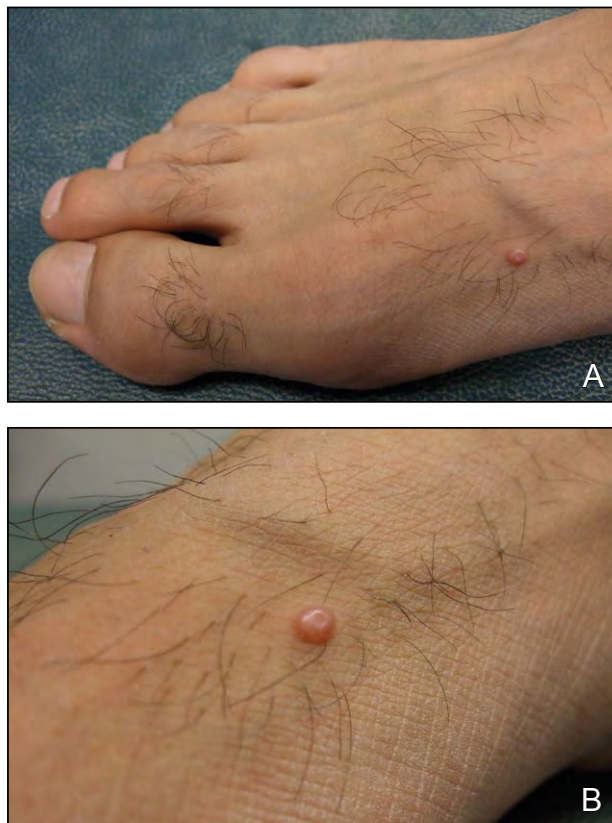

Figure 3. An asymptomatic lesion of plantar molluscum contagiosum presented as a flesh-colored, dome-shaped, umbilicated papule on the medial aspect of the right dorsal foot proximal to the great toe that measured 5×3 mm (A and B).

(molluscum bodies or Henderson-Patterson bodies), and both lesions were diagnosed as MC.

The remaining plantar nodules were treated with occluded imiquimod cream 5% applied every other day for 1 week, then daily for 3 weeks, and then twice daily for 4 weeks. After 4 weeks of treatment, another papule appeared on his dorsal right foot. After 8 weeks of treatment, white particles (consistent with molluscum bodies) had extruded from the surface of the plantar nodules and both of the nodules had increased in size to 1×1 cm.

Shave excision was performed on both of the residual plantar nodules and to the new 4×4-mm umbilicated papule on his dorsal right foot. Microscopic examination of all of the specimens demonstrated plantar MC. The 5 lesion sites healed and there was no recurrence or new nodules after 13 months.

Comment

Molluscum contagiosum usually presents as asymptomatic, umbilicated, flesh-colored papules that are often located on the face, trunk, and extremities in children, and on the lower abdominal wall, inner thighs, pubic area, and genitalia in adults. The mucosa of the conjunctiva or mouth as well as the ventral surfaces of the hands and feet are uncommon sites for MC.¹ According to a PubMed search of articles indexed for MEDLINE using the term *plantar molluscum contagiosum*, biopsy-confirmed plantar MC only has been described in 35 children or adult cases including our case. In addition to cases 1 to 11, we summarize cases 12 to 35 in the footnotes of the Table.²⁻¹³

The first description of plantar MC was published in 1957.¹¹ The case was illustrated with a photograph taken at close range of the sole of a patient with 6 adjacent umbilicated papules and nodules. However, the authors did not provide additional information about the patient or the unique site of the lesions.¹¹

The first report of a patient with MC was published in 1964 in the *Journal of the American Podiatry Association* by Perry⁴ who described a 31-year-old woman with “a wart or something on . . . the lateral periphery of the medial longitudinal arch of the right foot” that had recurred following desiccation and was successfully treated 6 months later by excision with subsequent curettage and fulguration of the base of the lesion. Microscopic examination of the excised lesion showed numerous molluscum bodies.⁴ Two months later in March 1964 in the *Archives of Dermatology* Baxter and Carson⁹ reported a 21-year-old man with palmoplantar hyperhidrosis who had developed “an elevated, faintly erythematous, translucent, dome-shaped nodule which measured 6 mm in diameter” on his left sole and also

had 50 to 60 moist, white, macular lesions approximately 1 mm in diameter on the weight-bearing area of his foot. The larger lesion was excised and 2 months later the smaller macules had developed into umbilicated papules and were successfully treated with topical bichloroacetic acid.⁹

Subsequently, additional case reports that described either 1^{2,3,5,7,8,10,12} or 2⁶ patients with plantar MC were recorded. Nearly 30 years ago, one of the current authors (J.A.T.)⁸ reported a case of a 21-year-old paraplegic man with a plantar lesion on the sole of his right foot (1-cm nodule), a 3×3-mm papule on the base of the second toe on his left foot, and additional 3×3-mm papules on the dorsum of both feet; the larger lesion was excised and the smaller lesions were treated with liquid nitrogen cryotherapy.⁸ Additionally, a large retrospective study of 22 children with plantar MC was published.¹³

The Table²⁻¹³ summarizes cases of plantar MC in 5 women and 6 men; the gender was not provided for the other 24 patients. The age of onset for cases 1 through 11 ranged from 5 to 75 years with a median age of 21 years. Less than 10% (3/35) of the individuals were older than 30 years when their plantar MC appeared.

Eighty-six percent of patients with MC of the sole including our patient were either German (22/35) or white Americans (8/35). The remaining patients were Italian (2/35), Indian (1/35), Korean (1/35), or Turkish (1/35).

Several factors were postulated to be associated with the occurrence of plantar MC. A 5-year-old boy was described who had experienced “minor trauma to his sole 7 months before.”⁷ However, most patients including our patient did not recall any history of trauma on the sole of the foot. The development of a giant MC on the sole of a 21-year-old paraplegic man was thought to be secondary to his handicap.⁸ Plantar hyperhidrosis of a moderate degree was considered to contribute to the development of plantar MC in an additional case of a 21-year-old man who was working as a US Navy hospital corpsman.⁹ A 21-year-old woman from Scotland who was a computer operator with plantar MC also was recorded in a report by Bunney et al.³ She reported that she had not used public swimming pools or showers.³ However, all 22 children from Germany had visited an indoor swimming pool at least once.¹³

Pain was a presenting concern in more than 50% (7/13) of the individually reported patients with plantar MC. The pain was described as a stabbing sensation, particularly while walking. In addition, some of the German children had pain while walking; however, MC was an incidental finding for several of these children.¹³ Similarly, the plantar MC was

Characteristics of 35 Patients With Plantar Molluscum Contagiosum^{a-c}

Case No.	Reference	Age/Race/ Gender	No. of Lesions	Size, cm	Site	Pain	Treatment
1	Campanelli and DiCenso ² (1978)	17 y/white/F	1	1.2×1.2	R lateral fifth toe at PIP	Present	Debridement, then salicylic acid 20% weekly for 4 wk; hyfrecation to residual lesion 2 wk later; excise recurrent lesion 3 mo later
2	Bunney et al ³ (1969)	21 y/white/F	>5 lesions ^d	Not stated	L sole	Not described ^e	Incise and drain small abscess beneath "wart" lesion; 3 mo later incise and drain new "wart" and pare satellite lesions for EM; express "seeds" and apply phenol
3	Perry ⁴ (1964)	31 y/white/F	1	Pinhead; 5× larger ^f	Lateral edge of R medial arch	Not known	Desiccate; 6 mo later excise recurrent lesion and curettage and fulgurate base
4	Köse and Seçkin ⁵ (2009)	35 y/Turkish/F	1	0.5×0.5	Curve of L sole	Present	Excise
5	Strani ⁶ (1967) (case 1)	75 y/Italian/F	1	Not stated	Tip of L third toe	Present	Operative lesional biopsy/removal
6	Ha et al ⁷ (1998)	5 y/Korean/M	1	1.5×1.2	L midplantar	Present	Biopsy for pathology and EM; then curettage and desiccation
7	Strani ⁶ (1967) (case 2)	7 y/Italian/M	1	Not stated	R heel	Present	Excise
8	Dickinson ⁸ (1983)	21 y/white/M	2 ^g	1.0×1.0; 0.3×0.3	R sole; L second toe	Not known	Excise (larger lesion); liquid nitrogen cryotherapy to all smaller lesions

Case No.	Reference	Age/Race/ Gender	No. of Lesions	Size, cm	Site	Pain	Treatment
9	Baxter and Carson ⁹ (1964)	21 y/white/M	50–60 ^h	0.6×0.6	L instep, 5 cm proximal to L great toe MTP	Absent	Excise (larger lesion); application of BCA to each of the smaller lesions
10	Zichichi ¹⁰ (1969)	23 y/white/M	1	1.5×1.5	R fourth metatarsal head	Present	RRHT; then apply MCA 80% and salicylic acid; bulla roof containing lesion excise on day 4; AgNO ₃ 50% to base
11	Current report	23 y/Indian/M	3 ⁱ	0.8×0.6; 0.8×0.6; 0.8×0.8 ^j	R lateral arch; R lateral arch; R medial arch	Present	Excise (1 large and 1 small lesion); iniquimod cream 5% for 2 mo; excise residual 2 large lesions and 1 new lesion

Abbreviations: F, female; R, right; PIP, proximal interphalangeal joint; L, left; EM, electron microscopy; M, male; MTP, metatarsophalangeal joint; BCA, bichloroacetic acid; RRHT, routine reduction of hyperkeratotic tissue; MCA, monochloroacetic acid; AgNO₃, silver nitrate.

^hCase No. 12: photograph shows the arch of the plantar foot of a white patient with 6 adjacent umbilicated papules of variable sizes. The figure legend reads: "molluscum contagiosum of the sole (Institute of Dermatology)." ¹¹

ⁱCase No 13; photograph shows a single lesion on the plantar surface of the left third toe of a white patient. The figure legend reads: "molluscum contagiosum of the toe, plantar surface, in a tennis player (biopsy proven); clinically this appeared to be a pyogenic granuloma." ¹²

⁹Case No. 14–35: A retrospective study (November 1974 to February 1975) of 22 German children with biopsy-confirmed molluscum contagiosum on the plantar foot and/or heel. ¹³ Some of the patients presented with pain while walking, whereas the lesions were asymptomatic and incidentally observed for many of the patients. One lesion (15/22 patients), 2 lesions (4/22 patients), or 3 lesions (3/22 patients) were noted. The lesions mostly were 1 cm in diameter; however, sometimes they were as large as 2 cm. ¹³

⁹Initially there was 1 lesion that presented as a small abscess beneath a "wart" and "some satellite lesions." Three months later, single lesion recurred appearing as an infected wart "with surrounding satellites." ¹³

⁶"This patient . . . with an infected 'plantar wart' . . . [and] . . . 3 weeks later . . . returned with a further infected lesion . . . on a different site." The woman's symptoms were not described. ³

¹Initially "the mass at that time was the size of a pinhead." "Six months later the patient presented herself again complaining of the same problem" and "examination revealed the growth to be approximately 5 times the size it had previously been." ¹⁴

⁹Initially there were 2 plantar lesions and "multiple smaller papules on his [dorsal] left foot." One week later, "2 additional lesions (each 3 mm in size) were noted, 1 on each [dorsal] foot." ¹⁵

¹Initially there was 1 larger raised lesion. However, "over the weight-bearing area of the foot beneath the metatarsal head there were from 50 to 60 moist, white, macular lesions approximately 1 mm in diameter"; subsequently these lesions "developed into umbilicated papules with central keratinous plugs." ¹⁶

¹Initially there were 3 plantar lesions and one 0.5×0.3-cm umbilicated papule on the medial aspect of the dorsal foot. After 10 weeks, a second 0.5×0.4-cm umbilicated papule appeared on the proximal dorsal medial foot (current report). ¹⁷

¹The 2 smaller lesions located on the right medial arch had each increased to 1×1 cm 10 weeks after presentation (which was after 8 weeks of treatment)(current report).

asymptomatic on the left sole of the 21-year-old US Navy hospital corpsman who sought dermatologic evaluation because his lesion had gradually increased in size during the 2 months prior to presentation.⁹

Of the cases summarized in the Table,²⁻¹³ plantar MC was located on the right foot (5/11), left foot (5/11), or both feet (1/11); the specific location was not described for the remaining 24 patients. Two-thirds (23/35) of the individuals with plantar MC had only 1 lesion. Multiple plantar MC was described in 12 patients: 2 lesions in 5 patients^{8,13}; 3 lesions in 4 patients including the current report¹³; and more than 5 lesions in 3 patients.^{3,9,11}

The diagnosis of plantar MC was not initially suspected because the clinical appearance of the lesions rarely was pathognomonic. The morphologic descriptions ranged from wart,³ clavus,¹⁰ and neoplasm,⁴ to circumscribed hemispheric lesion⁶ and circular hyperkeratotic lesion.² Most of the reports described the lesions as either nodules^{5,8,9} or papules⁸ that were either flesh colored as in the current report, erythematous,⁹ brown,⁶ translucent,⁹ or waxy yellow.¹³ Their surface was described as either dome shaped,⁹ well-circumscribed areas of depressed epidermis that extruded small amorphous-appearing material (consistent with molluscum bodies) from the epithelium as in the current report, irregular and hyperkeratotic,⁶ vegetative and crusted,⁶ or verrucous with a rolled margin.⁷ Accompanying photographs without any description of MC showed a papillomatous nodule that “appeared to be a pyogenic granuloma”¹² and a group of umbilicated papules and nodules.¹¹ Only 1 report commented that the lesions developed into umbilicated papules with central keratinous plugs.⁹

The size of plantar MC ranged from “pinhead”⁴ and 3 mm⁸ in diameter to 1.5 cm¹⁰ and 2.0 cm¹³ in diameter. Giant MC lesions are greater than or equal to 1 cm in diameter. They usually are observed in individuals who are immunosuppressed, such as organ transplant recipients and human immunodeficiency virus–infected patients. They often appear as solitary lesions at unusual sites, such as the eyelid, scalp, and sole.^{7,14} None of the patients with plantar MC were immunocompromised. However, more than 75% of these patients (a minimum of 27/35) had giant plantar MC as in the current report.^{2,7,8,10,13}

The clinical differential diagnosis of plantar MC includes adenomas,⁷ basal cell carcinoma,^{7,9} cryptococcal infection,⁷ eccrine poroma,^{5,7,9} epidermoid cyst,^{5,7} fibroma (pleomorphic),¹⁵ foreign body granuloma,^{5,7,9} keratoacanthoma,^{2,7,9,13} plantar verruca,^{2,7,9,10,13} and pyogenic granuloma.^{2,5,7,13} The diagnosis of MC of the sole was confirmed by evaluating the lesion using light microscopy as in the current report,^{2,4-6,8-10,12,14} electron microscopy,³ or both.⁷

Although the morphologic presentation of the lesion often was not suggestive of MC, the pathologic changes were diagnostic and large cytoplasmic viral inclusion bodies (molluscum bodies) were observed within the epidermis.

The treatment of plantar MC involves either removal or destruction of the infectious viral lesion. Diagnostic or therapeutic excision of the plantar lesion was uniformly successful as in our patient.^{2,4-6,8-10} Alternatively, usually after the diagnosis was established with a biopsy of the lesion, the residual MC was eradicated with curettage and either fulguration or desiccation of the site.^{4,7} Other successful modalities, often preceded by removal of part or all of the MC, included liquid nitrogen cryotherapy⁸; desiccation or hyfrecation^{2,4}; expression of the molluscum bodies³; incision and drainage³; paring or “routine reduction of hyperkeratotic tissue”^{9,10}; or topical application of bichloroacetic acid,⁹ monochloroacetic acid,¹⁰ phenol,³ salicylic acid,^{2,10} or silver nitrate.¹⁰ Prompted by the successful treatment of chronic giant MC in a patient with advanced human immunodeficiency virus,¹⁶ we attempted to treat our patient’s giant plantar MC with topical immunotherapy with little success.

Conclusion

Molluscum contagiosum located on the plantar surface of the foot is uncommon and has only been reported in 35 individuals. The patients’ ages ranged from 5 to 75 years and the median age was 21 years. The patients were from several different countries and none of them were immunosuppressed. Pain, particularly when walking, was a common presenting symptom. However, viral skin infection also was discovered in several patients as an incidental finding. Most patients with MC of the sole (23/35) only had 1 plantar lesion. However, patients with multiple plantar MC also were observed: 2 lesions (5/35), 3 lesions (4/35), and more than 5 lesions (3/35). At least 75% (a minimum of 27/35) of the patients had giant MC (diameter ≥ 1 cm). A plantar verruca usually was suspected at the initial patient evaluation because the morphology of the lesions was rarely pathognomonic. The correct diagnosis subsequently was established using light and/or electron microscopy of the lesion. Removal or destruction of the lesion resulted in definitive treatment of the plantar MC.

REFERENCES

1. Cohen PR. Molluscum contagiosum. In: Leshner JL Jr, ed. *An Atlas of Microbiology of the Skin—(The Encyclopedia of Visual Medicine Series)*. Pearl River, NY: Parthenon Publishers; 1999:120-124.
2. Campanelli M, DiCenso FA. Molluscum contagiosum: a case report. *J Am Podiatry Assoc*. 1978;68:566-567.

3. Bunney MH, Hunter JA, Ogilvie MM. Molluscum contagiosum of the sole. a rare diagnosis or a rare condition? *Br J Dermatol*. 1969;81:623-625.
4. Perry GM. Molluscum contagiosum, a case report. *J Am Podiatry Assoc*. 1964;54:32-33.
5. Köse OK, Seçkin D. Molluscum contagiosum of the sole [published online ahead of print April 21, 2008]. *J Eur Acad Dermatol Venereol*. 2009;23:109-110.
6. Strani GF. Clinical and histological aspects of molluscum contagiosum with palmo-plantar localization [in Italian]. *Minerva Dermatol*. 1967;42:437.
7. Ha SJ, Park YM, Cho SH, et al. Solitary giant molluscum contagiosum of the sole. *Pediatr Dermatol*. 1998;15:222-224.
8. Dickinson A, Tschen JA, Wolf JE Jr. Giant molluscum contagiosum of the sole. *Cutis*. 1983;32:239-240, 243.
9. Baxter DL, Carson WE. Molluscum contagiosum of the sole. *Arch Dermatol*. 1964;89:471-472.
10. Zichichi D. Molluscum contagiosum. a case report. *J Am Podiatry Assoc*. 1969;59:274-275.
11. Ingram JT, Brain RT. Viral and rickettsial diseases. In: Ingram JT, Brain RT, eds. *Sequeira's Diseases of the Skin*. 6th ed. London, England: Churchill; 1957:662-703.
12. Resnik SS, Lewis LA, Cohen BH. The athlete's foot. *Cutis*. 1977;20:351-353, 355.
13. Pfreundschuh M, Fuck J, Schredl L. Epidemiologic appearance of molluscum contagiosum in a rare form and localization [in German]. *MMW Munch Med Wochenschr*. 1975;117:1175-1176.
14. Matsuda M, Bloch LD, Arnone M, et al. Giant molluscum contagiosum: does it affect truly immunocompetent individuals? *Acta Derm Venereol*. 2005; 85:88-89.
15. Cohen PR, Schulze KE, Cohen SA, et al. Pleomorphic fibroma of the skin. *Skinned*. 2010;8:113-115.
16. Buckley R, Smith K. Topical imiquimod therapy for chronic giant molluscum contagiosum in a patient with advanced human immunodeficiency virus 1 disease. *Arch Dermatol*. 1999;135:1167-1169.