

Generalized Pustular Psoriasis of Zambusch: Case Report of Successful Disease Control With Cyclosporine and Etanercept

Kathleen Vine, MD; Henry J. Votava, MD; Barry L. Smith, MD

Generalized pustular psoriasis of Zambusch is a unique and challenging skin condition to successfully manage. Patients often encounter potentially high recurrence rates of pustular eruptions despite multidrug treatment regimens with high morbidity as a consequence. We report a case of generalized pustular psoriasis of Zambusch in a patient whose disease initially flared following early treatment with the anti-tumor necrosis factor α (anti-TNF- α) inhibitor etanercept but was later successfully managed with cyclosporine and reintroduction of etanercept. We also discuss therapeutic management options for generalized pustular psoriasis.

Cutis. 2012;90:132-136.

Generalized pustular psoriasis of Zambusch is a rare and unique skin condition that often is a therapeutic challenge to successfully manage. Despite multidrug treatment regimens with methotrexate sodium, cyclosporine, systemic retinoids, and biologic agents, patients often encounter high recurrence rates of pustular eruptions with high morbidity as a consequence. We report a case of generalized pustular psoriasis of Zambusch that initially flared during introduction of therapy with the anti-tumor necrosis factor α (anti-TNF- α) inhibitor etanercept that later was successfully managed with combination

cyclosporine and readministration of etanercept. We discuss the clinical and histologic appearance of generalized pustular psoriasis of Zambusch, potential exacerbating factors associated with the development of disease, and the issue of new onset or exacerbation of preexisting pustular psoriasis following initiation of the anti-TNF- α inhibitor etanercept.

Case Report

A 23-year-old healthy woman with no notable medical history presented with a pruritic rash of 1 month's duration that started on her neck and generalized to the rest of her body. The only precipitating event she recalled was a history of an arthropod assault the day before the development of her skin lesions. The patient made 2 separate visits to a local emergency department and was given 2 separate weeklong

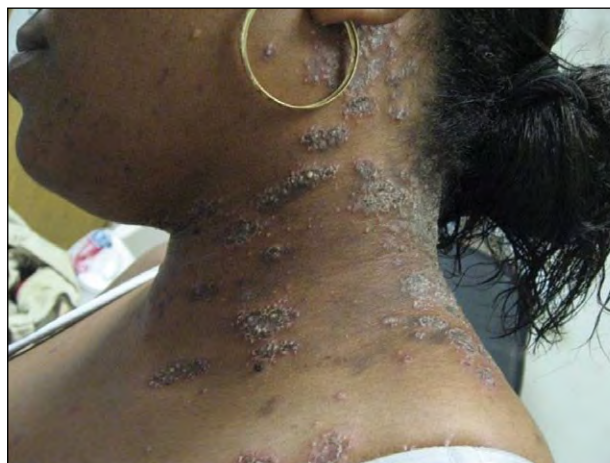

Figure 1. Initial presentation of scattered vesiculopustules on a scaly erythematous base on the left lateral neck.

From the Department of Dermatology, St. Luke's-Roosevelt Hospital Center, New York, New York.

The authors report no conflict of interest.

Correspondence: Kathleen Vine, MD, 155 Spring St, 4th Floor, New York, NY 10012 (khardick@hotmail.com).

courses of oral prednisone 40 mg daily; however, she noticed considerable worsening of her skin lesions.

She presented with scattered vesiculopustules on a scaly erythematous base on her scalp, neck (Figure 1), retroauricular folds, axillae, and inframammary creases. Several of the lesions had coalesced into crusted erythematous plaques. No oral or ocular mucosal involvement or lymphadenopathy was appreciated. Two skin biopsies were performed, along with bacterial, fungal, and viral cultures. Biopsy results were consistent with pustular psoriasis (Figure 2). Direct immunofluorescence was negative, as were bacterial, fungal, and viral cultures.

After reviewing the available therapeutic options, we decided to initiate subcutaneous injections of etanercept 50 mg twice weekly. Purified protein derivative (tuberculin) and laboratory evaluation were within reference range. Four days after the first injection of etanercept, the patient returned with worsening of her skin condition. Scattered pustules coalesced into plaques overlying an erythematous base over her face, neck, trunk (Figure 3), and bilateral upper and lower extremities. Given the exacerbation of her symptoms, etanercept was discontinued and she was admitted to the hospital for further management. Repeat skin biopsies were performed and revealed large confluent subcorneal pustules filled with neutrophils, evenly elongated rete ridges, and an absent granular layer (Figure 4), consistent with generalized pustular psoriasis of Zambusch. Direct immunofluorescence was negative, as were repeat bacterial, fungal, and viral cultures. Over the next 2 days, the patient became erythrodermic and pustules coalesced into large lakes of pus over the face and neck (Figure 5), trunk, and bilateral upper and lower extremities. She was started on oral cyclosporine (unmodified) 200 mg each morning and 300 mg at bedtime (5.2 mg/kg daily based on actual body weight) with rapid clinical improvement (Figure 6).

The erythroderma and pustules resolved in the ensuing week, and the patient was discharged from the hospital on oral cyclosporine (modified) 200 mg twice daily (4.2 mg/kg daily based on actual body weight). Over the following month her skin lesions were well controlled with cyclosporine monotherapy. The only complication reported while on cyclosporine therapy was 2 episodes of varicella-zoster virus. After a year of adequate symptom control with modified cyclosporine (4.2 mg/kg daily based on actual body weight), successful addition and eventual transition to monotherapy with etanercept was achieved. After 3 months of subcutaneous etanercept 50 mg twice weekly, she was transitioned to subcutaneous etanercept 50 mg weekly; her skin has been well controlled on this regimen alone.

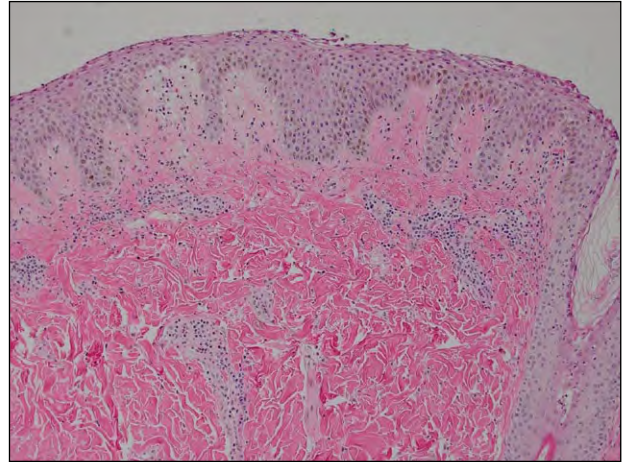


Figure 2. Histology of the patient on initial presentation revealed a thin layer of confluent parakeratosis with neutrophils admixed with necrotic corneocytes thinly covering a spongiotic stratum spinosum, an absent granular layer, pallor of the upper spongiotic epidermal layers containing neutrophils, regular epidermal hyperplasia with evenly elongated rete ridges, thin suprapapillary plates, marked edema of the dermal papillae containing dilated tortuous blood vessels closely approximating the basal layer of the papillary dermis, and a superficial and mid-dermal perivascular infiltrate of lymphocytes and neutrophils (H&E, original magnification $\times 20$).

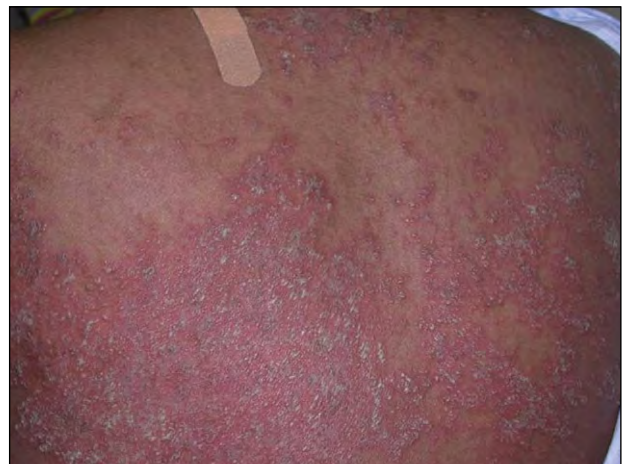

Figure 3. Exacerbated skin lesions with scattered pustules that coalesced into large plaques of pus overlying erythematous patches on the upper and mid back 4 days after the first subcutaneous injection of etanercept.

Comment

Generalized pustular psoriasis of Zambusch is a severe and often recalcitrant form of psoriasis. Patients often experience acute onset of painful erythematous skin lesions to full-blown erythroderma that quickly can progress to scattered pustules and coalesce into lakes of pus. Eruptions of pustules often wax and

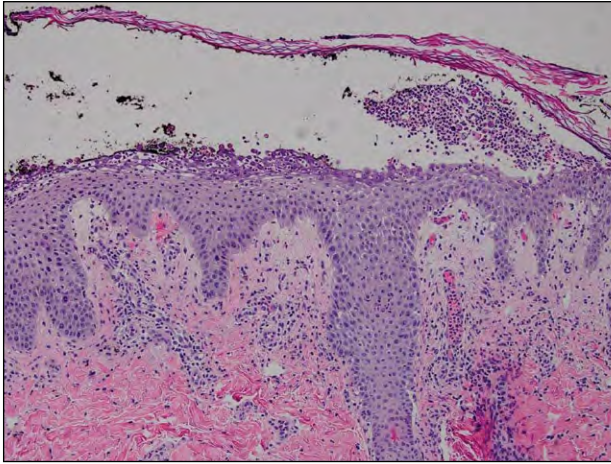


Figure 4. Skin biopsy after exacerbation of skin lesions following 1 injection of etanercept revealed epidermal hyperplasia with pallor and spongiosis; large confluent subcorneal pustules filled with neutrophils; evenly elongated rete ridges; absent granular layer; thin suprapapillary plates; proliferative basal layer with mitotic figures; dermal papillae containing marked edema and dilated tortuous blood vessels closely approximating the basal layer; and a papillary dermis with a perivascular and interstitial infiltrate of lymphocytes, neutrophils, and occasional melanophages (H&E, original magnification $\times 20$).

wane over time and may last days to weeks.¹ Patients may experience associated findings of fever, chills, pruritus, dehydration, tachycardia, anemia, weight loss, arthralgia, and weakness.¹ Histologic evaluation of skin biopsy often reveals a parakeratotic stratum corneum with hypogranulosis overlying a psoriasiform epidermis. The papillary dermis reveals a superficial perivascular mononuclear infiltrate and dilated capillaries. Numerous neutrophilic collections may be seen in the stratum corneum (Munro microabscess) or epidermis (spongiform pustule of Kogoj).² Although the etiology of generalized pustular psoriasis of Zambusch is not fully clear, predisposing factors have been associated with the disease including infection, pregnancy, hypocalcemia, rapid withdrawal of topical or systemic corticosteroids, and medications (ie, lithium carbonate, propranolol hydrochloride, iodides, penicillin, and indomethacin).^{1,2} Tobin et al³ reported 2 cases of generalized pustular psoriasis of Zambusch that developed following the use of calcipotriol and betamethasone dipropionate ointment. Brenner et al⁴ described 4 cases of generalized pustular psoriasis that were triggered following cessation of systemic glucocorticosteroids. Although the mechanism that triggers generalized pustular psoriasis is not fully understood,

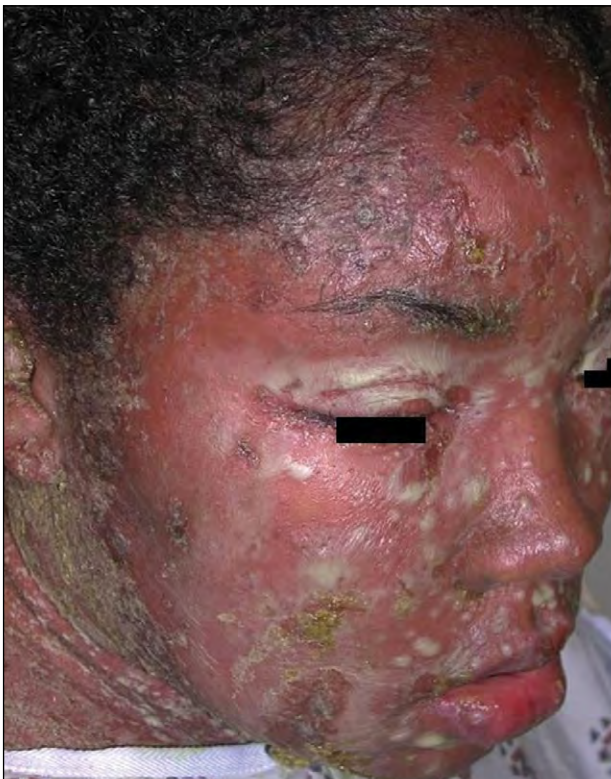

Figure 5. Six days following first injection of etanercept the patient developed large lakes of pus overlying the bilateral eyelids, cheeks, and neck with scattered pustules and crusted hyperpigmented plaques.

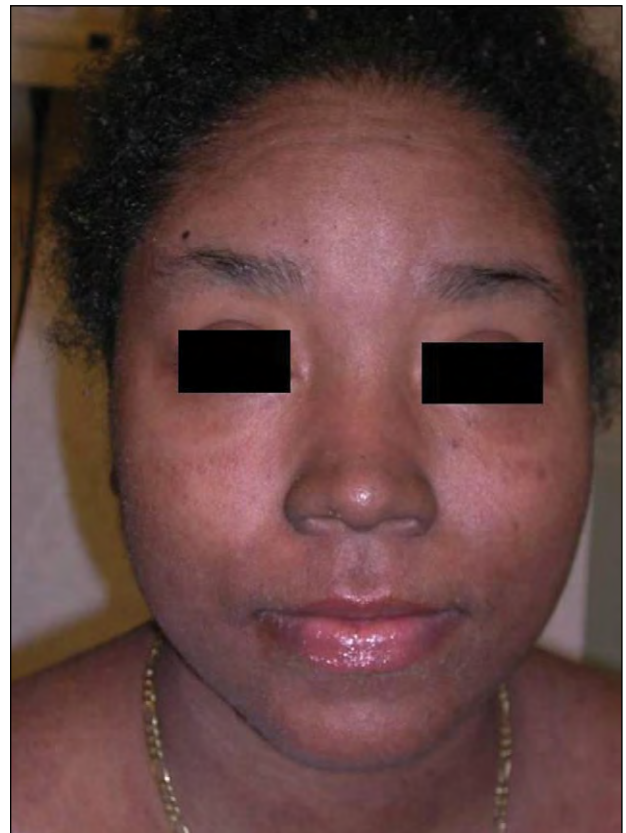

Figure 6. Rapid clinical improvement of skin lesions occurred 8 days after initiation of cyclosporine monotherapy.

Kato and Yamamoto⁵ demonstrated increased levels of growth-related oncogene α in the sera of patients with generalized pustular psoriasis. They postulated that growth-related oncogene α may recruit and activate neutrophils in the skin and contribute to disease severity.⁵

Effective therapy for generalized pustular psoriasis of Zambusch often is a challenge, as the condition can be recalcitrant to treatment.⁶ Combination therapies may be needed to achieve stable remission. Tobin et al³ published 2 cases that were successfully controlled with combination therapies: acitretin with hydroxyurea, and methotrexate sodium with cyclosporine. Jaime et al⁷ discussed a case of generalized pustular psoriasis that required acitretin and intravenous antibiotics. Weisenseel and Prinz⁸ reported a case of generalized pustular psoriasis controlled with sequential administration of infliximab and etanercept. Other cases have been reported in which successful control of disease was achieved with combination infliximab and acitretin⁶; infliximab and methotrexate sodium⁹; adalimumab with acitretin and methotrexate sodium⁴; and acitretin and etanercept.⁴ Children also may be affected by generalized pustular psoriasis and require combination therapy for adequate disease control. Mazzatenta et al¹⁰ published a case of a 2-year-old girl with generalized pustular psoriasis of Zambusch who was treated with acitretin followed by dapsone and narrowband UVB therapy. The patient experienced several relapses of disease and was treated with several short cycles of narrowband UVB therapy.¹⁰ A case was presented by de Oliveira et al¹¹ involving 7 children with generalized pustular psoriasis who were treated with acitretin, infliximab, or a combination of acitretin with methotrexate sodium.

Cases also have been reported in which a single treatment regimen successfully controlled cutaneous disease. For instance, each of the anti-TNF- α biologic agents has been reported to successfully control generalized pustular psoriasis. Infliximab,¹² etanercept,¹³ adalimumab,^{14,15} and recently ustekinumab¹⁶ have achieved successful remission of generalized pustular psoriasis as monotherapy. Viguier et al¹⁷ reported 2 cases of generalized pustular psoriasis that vastly improved following monotherapy with IL-1ra anakinra. Prior treatment with infliximab, adalimumab, and etanercept failed in one patient, and the second patient did not respond to prior treatment with isotretinoin, cyclosporine, and adalimumab.¹⁷

Although anti-TNF- α agents have been reported to successfully control generalized pustular psoriasis, cases of new onset or exacerbation of preexisting psoriasis have been published, with a prevalence of 1.5% to 5% of those patients using TNF- α antagonists (ie, infliximab, etanercept, adalimumab).¹⁸⁻²¹ Wendling

et al¹⁸ retrospectively reviewed 12 patients with psoriasis onset or exacerbation while on anti-TNF- α therapy; they found that skin lesions often developed within the first few months of treatment and were more common in patients with a history of psoriasis. Palmoplantar pustular psoriasis was a commonly featured subtype of the new onset or exacerbated underlying psoriasis; however, guttate, plaque, and pustular psoriasis also were seen in patients treated with the 3 TNF- α antagonists.¹⁸ Because of our patient's history of only a single injection and early onset of her pustular psoriasis following etanercept, it is unlikely that this initial injection caused her pustular flare.

Etanercept is a recombinant human-soluble fusion protein that competitively inhibits the interaction of TNF- α with its cell-surface receptor. This inhibition prevents TNF- α -mediated cellular responses and modulates the activity of other proinflammatory cytokines mediated by TNF- α .²² The drug currently is approved by the US Food and Drug Administration for moderate to severe plaque psoriasis and psoriatic arthritis. Ahmad and Rogers²² conducted a retrospective study of 49 patients treated with etanercept for severe psoriasis that was resistant to other systemic agents. They found that etanercept was effective in treating severe psoriasis recalcitrant to other systemic medications and was well tolerated.²² Esposito et al¹³ evaluated the efficacy and safety of etanercept at different dosages (25 and 50 mg subcutaneously biweekly) in 6 patients with generalized pustular psoriasis that was unresponsive to prior therapy. They found that etanercept provided safe, effective, and durable results, and suggested that it should be considered for the management of patients with severe treatment-resistant pustular psoriasis.¹³

Unlike etanercept, cyclosporine is a T-cell inhibitor that primarily acts by inhibiting T cell function and IL-2. At doses of 2.5 to 5 mg/kg daily, it is effective in rapidly improving psoriasis in 80% to 90% of patients. Findings published in 2009 from the National Psoriasis Foundation Consensus Conference indicated that cyclosporine has a role in managing psoriatic conditions, treating psoriasis unresponsive to other modalities, and bridging to other therapies.²³ Hazarika²⁴ reported 2 cases of generalized pustular psoriasis during pregnancy that were quickly and successfully treated with cyclosporine monotherapy with no harm to the mothers or newborn infants. In our patient, cyclosporine monotherapy similarly exhibited rapid control of disease and was well tolerated.

Conclusion

We present a case of a 23-year-old woman with generalized pustular psoriasis of Zambusch that was rapidly and effectively controlled with cyclosporine

monotherapy, with eventual transition to etanercept and continued disease remission.

Acknowledgment—The authors would like to thank Ivelisse Carmona, RMA, New York, New York, for her help and assistance with our case.

REFERENCES

- Types of pustular psoriasis. National Psoriasis Foundation Web site. http://www.psoriasis.org/netcommunity/sublearn01_types_pustular. Accessed July 24, 2012.
- Ricotti C, Cockerell CJ, Groysman V, et al. Overview of pustular psoriasis. *Medscape Reference*. <http://medicine.medscape.com/article/1108220-overview>. Updated September 2, 2011. Accessed July 24, 2012.
- Tobin AM, Langan SM, Collins P, et al. Generalized pustular psoriasis (von Zumbusch) following the use of calcipotriol and betamethasone dipropionate ointment: a report of two cases. *Clin Exp Dermatol*. 2009;34:629-630.
- Brenner M, Molin S, Ruebsam K, et al. Generalized pustular psoriasis induced by systemic glucocorticosteroids: four cases and recommendations for treatment [published online ahead of print June 11, 2009]. *Br J Dermatol*. 2009;161:964-966.
- Kato Y, Yamamoto T. Increased serum levels of growth-related oncogene- α in patients with generalized pustular psoriasis [published online ahead of print November 12, 2009]. *Dermatology*. 2010;220:46-48.
- Chandran NS, Chong WS. A dramatic response to a single dose of infliximab as rescue therapy in acute generalized pustular psoriasis of von Zumbusch associated with neutrophilic cholangitis. *Australas J Dermatol*. 2010;51:29-31.
- Jaime TJ, Rodrigues BA, Jaime TJ, et al. Psoriasis of von Zumbusch [in English, Portuguese]. *An Bras Dermatol*. 2009;84:299-301.
- Weisenseel P, Prinz JC. Sequential use of infliximab and etanercept in generalized pustular psoriasis. *Cutis*. 2006;78:197-199.
- Routhouska SB, Sheth PB, Korman NJ. Long-term management of generalized pustular psoriasis with infliximab: case series. *J Cutan Med Surg*. 2008;12:184-188.
- Mazzatenta C, Martini P, Luti L, et al. Diffuse sterile pustular eruption with changing clinical features in a 2-year old. *Pediatr Dermatol*. 2005;22:250-253.
- de Oliveira ST, Maragno L, Arnone M, et al. Generalized pustular psoriasis in childhood [published online ahead of print April 9, 2010]. *Pediatr Dermatol*. 2010;27:349-354.
- Sheth N, Greenblatt DT, Acland K, et al. Generalized pustular psoriasis of pregnancy treated with infliximab [published online ahead of print January 13, 2009]. *Clin Exp Dermatol*. 2009;34:521-522.
- Espósito M, Mazzotta A, Casciello C, et al. Etanercept at different dosages in the treatment of generalized pustular psoriasis: a case series [published online ahead of print February 20, 2008]. *Dermatology*. 2008;216:355-360.
- Callen JP, Jackson JH. Adalimumab effectively controlled recalcitrant generalized pustular psoriasis in an adolescent. *J Dermatolog Treat*. 2005;16:350-352.
- Zangrilli A, Papoutsaki M, Talamonti M, et al. Long-term efficacy of adalimumab in generalized pustular psoriasis. *J Dermatolog Treat*. 2008;19:185-187.
- Daudén E, Santiago-et-Sánchez-Mateos D, Sotomayor-López E, et al. Ustekinumab: effective in a patient with severe recalcitrant generalized pustular psoriasis [published online ahead of print November 4, 2010]. *Br J Dermatol*. 2010;163:1346-1347.
- Viguier M, Guigüe P, Pagès C, et al. Successful treatment of generalized pustular psoriasis with the interleukin-1-receptor antagonist anakinra: lack of correlation with IL1RN mutations. *Ann Intern Med*. 2010;153:66-67.
- Wendling D, Balblanc JC, Briançon D, et al. Onset or exacerbation of cutaneous psoriasis during TNF α antagonist therapy [published online ahead of print February 11, 2008]. *Joint Bone Spine*. 2008;75:315-318.
- Cohen JD, Bournerias I, Buffard V, et al. Psoriasis induced by tumor necrosis factor- α antagonist therapy: a case series [published online ahead of print October 1, 2006]. *J Rheumatol*. 2007;34:380-385.
- Wollina U, Hansel G, Koch A, et al. Tumor necrosis factor- α inhibitor-induced psoriasis or psoriasiform exanthemata: first 120 cases from the literature including a series of six new patients. *Am J Clin Dermatol*. 2008;9:1-14.
- Goiriz R, Daudén E, Pérez-Gala S, et al. Flare and change of psoriasis morphology during the course of treatment with tumour necrosis factor blockers [published online ahead of print December 14, 2006]. *Clin Exp Dermatol*. 2006;32:176-179.
- Ahmad K, Rogers S. Two years of experience with etanercept in recalcitrant psoriasis [published online ahead of print April 4, 2007]. *Br J Dermatol*. 2007;156:1010-1014.
- Rosmarin DM, Lebwohl M, Elewski BE, et al; National Psoriasis Foundation. Cyclosporine and psoriasis: 2008 National Psoriasis Foundation Consensus Conference [published online ahead of print November 24, 2009]. *J Am Acad Dermatol*. 2010;62:838-853.
- Hazarika D. Generalized pustular psoriasis of pregnancy successfully treated with cyclosporine. *Indian J Dermatol Venereol Leprol*. 2009;75:638.