

Adalimumab for the Treatment of Pityriasis Rubra Pilaris: A Case Report

Cindy Wassef, BA; Adriana Lombardi, MD; Babar K. Rao, MD

Pityriasis rubra pilaris (PRP) is a chronic papulosquamous eruption of the skin characterized by follicular hyperkeratosis, salmon pink scaly plaques with islands of unaffected skin, and palmoplantar keratoderma. Widely used oral systemic and topical treatments are not greatly effective. We present a 62-year-old man with PRP of 2 years' duration who used routine topical treatments, oral retinoids, and UV therapy without improvement, but his symptoms greatly improved with the initiation of adalimumab.

Cutis. 2012;90:244-247.

Pityriasis rubra pilaris (PRP) is a skin eruption characterized by waxy keratoderma of the palms and soles, follicular hyperkeratosis, and salmon pink scaly plaques with islands of unaffected skin. Patients also may experience thickened nail plates with a yellowish brown discoloration and subungual debris.^{1,2} A classification system was developed to characterize PRP based on the patient's age, duration of disease, and extent of cutaneous involvement (Table).³⁻⁵ Pityriasis rubra pilaris may mimic psoriasis with psoriasiform hyperplasia, but PRP lacks neutrophilic abscesses in the epidermis and presents with follicular hyperkeratosis and alternating vertical and horizontal parakeratosis (Figure 1). Acantholysis and focal acantholytic dyskeratosis are helpful in pathologically differentiating between PRP and psoriasis.^{3,5}

Methods for PRP treatment are inconsistent and often unsuccessful.^{6,7} The first therapies for PRP were oral doses of vitamin A; however, large dosage requirements rendered the treatment toxic. Isotretinoin

1 to 1.5 mg/kg daily showed notable clearance 3 to 6 months following the initiation of treatment. Methotrexate 10 to 25 mg weekly showed remarkable improvements in patients with PRP within 3 to 6 months of initiating therapy; however, side effects included hepatotoxicity and myelosuppression. Severe cases of PRP have shown improvement with combination therapies of methotrexate 5 to 30 mg weekly and an oral retinoid.^{1,3,8} Other treatments used are vitamin D analogues, immunosuppressive agents, and anabolic steroids. Although UV light therapies

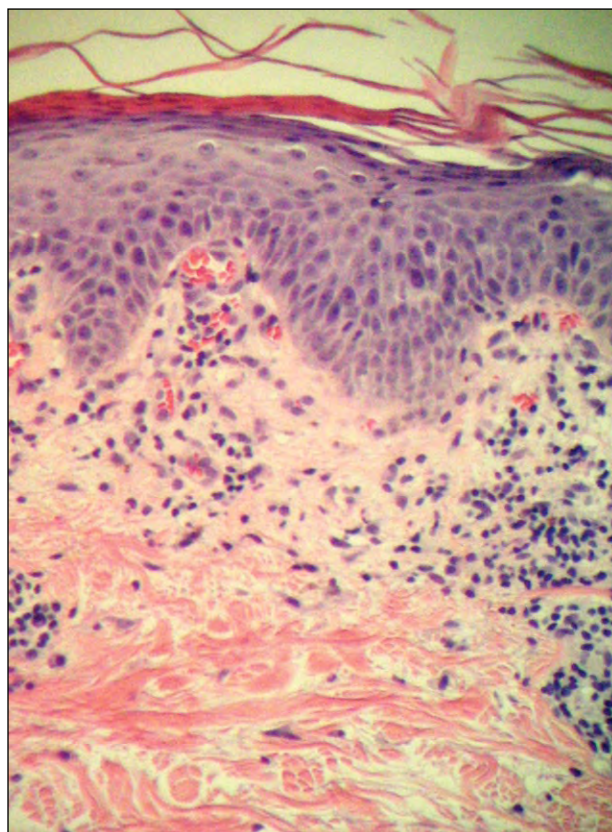


Figure 1. Psoriasiform hyperplasia, orthokeratosis, and parakeratosis consistent with pityriasis rubra pilaris (H&E, original magnification $\times 20$).

Ms. Wassef is from UMDNJ New Jersey Medical School, Newark. Dr. Lombardi is from the Department of Dermatology, New York Medical College, New York. Dr. Rao is from the Department of Dermatology, Robert Wood Johnson Medical School, Somerset, New Jersey.

Ms. Wassef and Dr. Lombardi report no conflict of interest. Dr. Rao is a speaker for and has received honoraria from Abbott Laboratories. Correspondence: Cindy Wassef, BA, PO Box 14, Towaco, NJ 07082.

Classification of Pityriasis Rubra Pilaris³⁻⁵

Type	Description
Type I (classic adult)	Affects >50% of PRP patients; red-orange plaques with islands of unaffected skin; follicular hyperkeratosis; waxy palmoplantar keratoderma; often resolves within 3 years
Type II (atypical adult)	Follicular keratosis; ichthyosiform lesions on legs; eczematous dermatitis; keratoderma with coarse lamellated scale; generally lasts for >20 years
Type III (classic juvenile)	Characteristically similar to type I; onset at 1–2 years of age; resolves in 1–3 years
Type IV (circumscribed juvenile)	Seen in prepubertal children; islands of erythematous plaques on elbows and knees; erythema; sometimes with palmoplantar keratoderma
Type V (atypical juvenile)	Familial PRP attributed to this type; follicular hyperkeratosis; erythema; sclerodermalike hands and feet
Type VI (HIV associated)	Characteristically similar to type I but more severe; also may see acne conglobata, hidradenitis suppurativa, and lichen spinulosus

Abbreviations: PRP, pityriasis rubra pilaris; HIV, human immunodeficiency virus.

may exacerbate PRP at times, narrowband UVB, UVA1, or psoralen plus UVA in conjunction with oral steroids have shown improvement.^{3,5,8}

Case Report

A 62-year-old man presented with a persistent rash on his trunk, extremities, palms, and soles of 2 years' duration. His medical history was notable for hypercholesterolemia, which was being treated with fluvastatin sodium. On examination, several scaly salmon pink plaques on his back (Figure 2A); thick keratosis on the dorsal aspect of the hands (Figure 2B), palms, and soles; and dystrophic nails were observed. The differential diagnosis based on examination was psoriasis versus PRP. Skin biopsy results were suggestive but not specific for PRP. There was psoriasiform hyperplasia and follicular hyperkeratosis but no classic alternating vertical and horizontal parakeratosis; additionally, epidermal neutrophilic abscesses were minimal.

Based on clinical presentation, especially the presence of islands of sparing, salmon pink plaques,

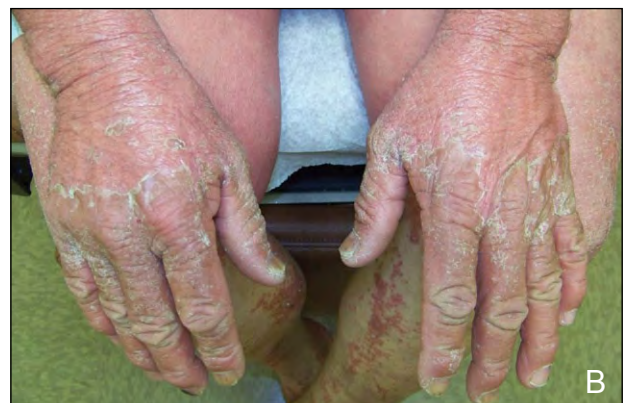
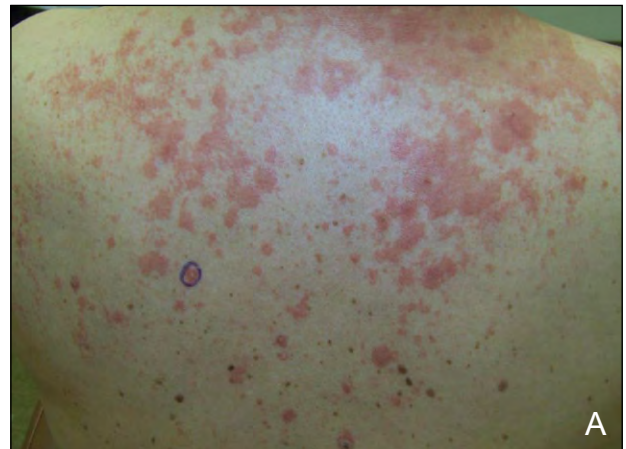
Figure 2. Salmon pink plaques on the back (A) and thick keratosis on the dorsal aspect of the hands before treatment (B).

and waxy keratoderma, as well as histologic findings, type I PRP was favored over psoriasis. He was treated with potent topical steroids, UVB, psoralen plus UVA, methotrexate, and vitamin D creams, which were all minimally effective. He was especially bothered by the foul smell of his hands and feet. Finger webs became macerated and caused secondary infection, requiring treatment with topical and oral antibiotics. Finally, the patient was treated with adalimumab 40 mg subcutaneous injections biweekly. Within 3 months, his condition had substantially resolved (Figure 3).

Comment

Although biologic treatments currently are not approved by the US Food and Drug Administration for the treatment of PRP, favorable results have been documented, particularly by Garcovich et al.⁹ Prior case reports also have shown responses in patients who were administered infliximab, etanercept, adalimumab, and efalizumab.^{1,2,7} Many patients have

shown complete resolution of PRP.⁶ Adalimumab specifically has demonstrated efficacy in the treatment of PRP.¹ Adalimumab currently is approved by the US Food and Drug Administration for the treatment of rheumatoid arthritis, polyarticular juvenile idiopathic arthritis, psoriatic arthritis, ankylosing spondylitis, Crohn disease, ulcerative colitis, and plaque psoriasis. Although no long-term research has been performed on the biologics and their effect on PRP, primarily due to a lack of patient population, the continued individual success rates in patients warrant further research.^{5,6}

Tumor necrosis factor (TNF) inhibitors are a class of biologic response modifiers that target TNF, a pro-inflammatory cytokine known to play a role in much of the inflammation associated with dermatologic diseases.¹⁰ Although individual TNF inhibitors are known to overlap in their ability to treat certain conditions, all TNF inhibitors therapeutically are not the same. Because of their different structures, binding profiles, and activity at the site of impact, switching patients to different TNF inhibitors has proved effective in the treatment of specific symptoms when other TNF inhibitors have not been successful.^{10,11}

Adalimumab is a recombinant human IgG1 monoclonal antibody that is subcutaneously injected, usually in increments of 40 mg biweekly. Human monoclonal antibodies such as adalimumab have been shown to form large complexes with TNF- α , which has the possibility to lead to antibody and complementary dependent cellular toxicity. Because human monoclonal antibodies are much slower in dissociating from TNF- α than etanercept (a human soluble TNF receptor), it has been hypothesized that human monoclonal antibodies such as adalimumab may have a greater chance of neutralizing TNF. Adalimumab also can lead to cellular lysis, which is not possible with the use of etanercept.^{10,11}

Based on our literature search using Google Scholar and Wiley Online Library with the search term *pityriasis rubra pilaris biologics*, there currently are at least 2 reported cases of treatment of PRP with adalimumab, 3 reported cases of treatment with infliximab, and additional reports of treatment with etanercept.^{1,6,7,10,12,13} Considering its similar mechanism of action to infliximab with respect to chemistry and binding, adalimumab would be expected to have similar effects on PRP as infliximab; however, few off-label uses for adalimumab have been reported.¹⁰

Conclusion

Although adalimumab would have been effective if our patient had been diagnosed with psoriasis, adalimumab has not been widely tested for the treatment

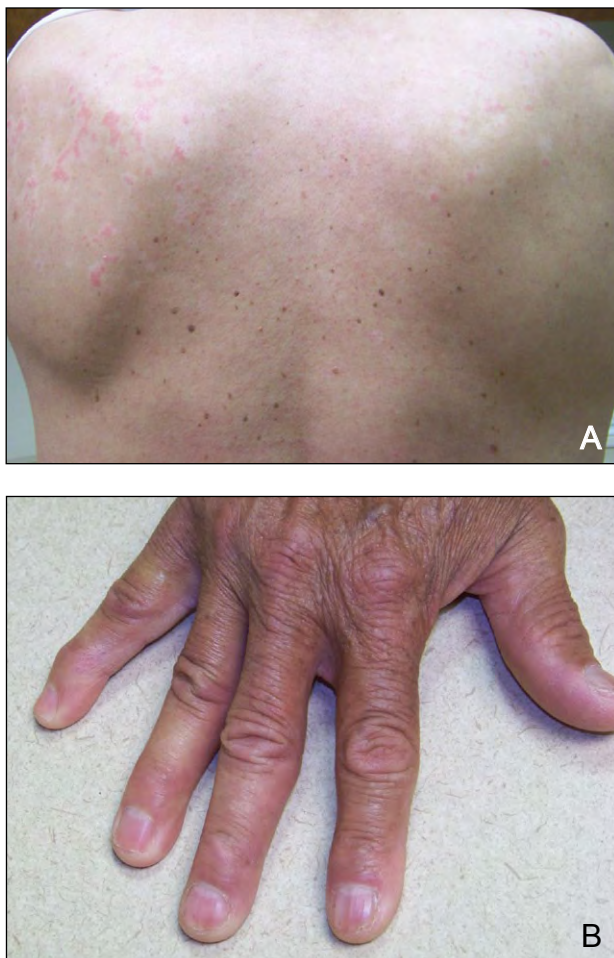

Figure 3. The back (A) and dorsal aspect of the hand after 3 months of treatment with adalimumab (B).

of PRP. Therefore, further evaluation of the efficacy of adalimumab in the treatment of PRP is essential to provide patients with an additional biologic treatment.

REFERENCES

1. Walling HW, Swick BL. Pityriasis rubra pilaris responding rapidly to adalimumab. *Arch Dermatol*. 2009;145:99-101.
2. Davis KF, Wu JJ, Murase JE, et al. Clinical improvement of pityriasis rubra pilaris with combination etanercept and acitretin therapy. *Arch Dermatol*. 2007;143:1597-1599.
3. Wood GS, Reizner G. Other papulosquamous disorders. In: Bologna JL, Jorizzo JL, Rapini RP, eds. *Dermatology*. London, England: Mosby; 2003:155-158.
4. Wolff K, Goldsmith LA, Katz SI, et al, eds. *Fitzpatrick's Dermatology in General Medicine*. 7th ed. New York, NY: McGraw Hill; 2007.
5. Lu R, George SJ, Hsu S. Pityriasis rubra pilaris: failure of combination treatment with acitretin and infliximab. *Dermatol Online J*. 2006;12:18.
6. Liao WC, Mutasim DF. Infliximab for the treatment of adult-onset pityriasis rubra pilaris. *Arch Dermatol*. 2005;141:423-425.
7. Müller H, Gattringer C, Zelger B, et al. Infliximab monotherapy as first-line treatment for adult-onset pityriasis rubra pilaris: case report and review of the literature on biologic therapy. *J Am Acad Dermatol*. 2008;59(suppl 5):S65-S70.
8. Manoharan S, White S, Gumparthy K. Successful treatment of type I adult-onset pityriasis rubra pilaris with infliximab. *Australas J Dermatol*. 2006;47:124-129.
9. Garcovich S, Di Giampetruzzi AR, Antonelli G, et al. Treatment of refractory adult-onset pityriasis rubra pilaris with TNF- α antagonists: a case series [published online ahead of print November 30, 2009]. *J Eur Acad Dermatol Venereol*. 2010;24:881-884.
10. Alexis AF, Strober BE. Off-label dermatologic uses of anti-TNF- α therapies. *J Cutan Med Surg*. 2005;9:296-302.
11. Flood J. Tumor necrosis factor (TNF) inhibitors—a review of structure, function, and mechanism of action. *Managed Care*. 2008;17(5, suppl 4):S2-S4.
12. Cox V, Lesesky EB, Garcia BD, et al. Treatment of juvenile pityriasis rubra pilaris with etanercept. *J Am Acad Dermatol*. 2008;59(suppl 5):S113-S114.
13. Schreml S, Zeller V, Babilas P, et al. Pityriasis rubra pilaris successfully treated with adalimumab. *Clin Exp Dermatol*. 2010;35:792-793.



NEED MORE INFORMATION?

Access these related articles in our online archives at www.cutis.com

- ▾ Circumscribed Juvenile-Onset Pityriasis Rubra Pilaris With Hypoparathyroidism and Brachyonychia
- ▾ Tinea Versicolor Mimicking Pityriasis Rubra Pilaris
- ▾ What Is Your Diagnosis? Juvenile Pityriasis Rubra Pilaris

Use our Advanced Search to find these articles and more online!