

Series Editor: Camila K. Janniger, MD

# Congenital Dermatofibrosarcoma Protuberans

Orlando Oliveira de Moraes, MD; Lislely Calixto de Araújo, MD; Ciro Martins Gomes, MD; Anglya Samara Silva Leite Coutinho, MD; Fábio Augusto Albanez Souza, MD; Izelda Maria Carvalho Costa, PhD

*Congenital dermatofibrosarcoma protuberans (DFSP) is a rare dermal and subcutaneous neoplasm of low-grade malignant behavior that is characterized by a low frequency of metastases with locally invasive growth. Its occurrence at birth and during childhood is rare. We present a case of a patient who was born with a light brown macule on his right buttock that was misdiagnosed as localized scleroderma. The lesion progressed into reddish atrophic plaques and nodules extending to the iliac region and the gluteal fold. At 5 years of age, a diagnosis of congenital DFSP was made based on clinical and immunohistochemical characteristics (CD34 positivity and spindle cell proliferation). Although there was a delay in diagnosis, a 3-step excision was proposed with a final step of Mohs micrographic surgery (MMS).*

*Cutis.* 2012;90:285-288.

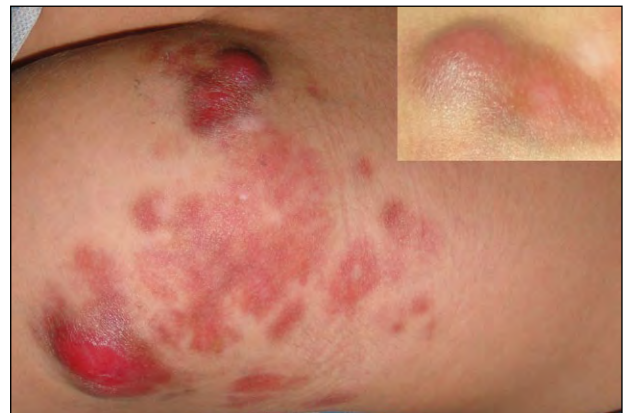## Case Report

A 5-year-old boy with a clinical history of a light brown macule on his right buttock that was present since birth was initially diagnosed with

localized scleroderma after the lesion had steadily grown into an atrophic plaque during his first year of life. He was treated with calcipotriene–betamethasone dipropionate ointment and disease regression appeared to have been established until he was 4 years of age. At that time, new nodules started to arise on the lesion surface, leading the child's guardians to seek medical attention.

Clinical examination revealed reddish plaques with irregular borders that were atrophic on palpation and extended from his right buttock to the iliac region and gluteal fold. Two reddish, painful, large, round nodules were seen on the lesion surface (Figure 1). A family history was not remarkable.

An incision biopsy showed a proliferation of spindle cells organized in a storiform pattern,

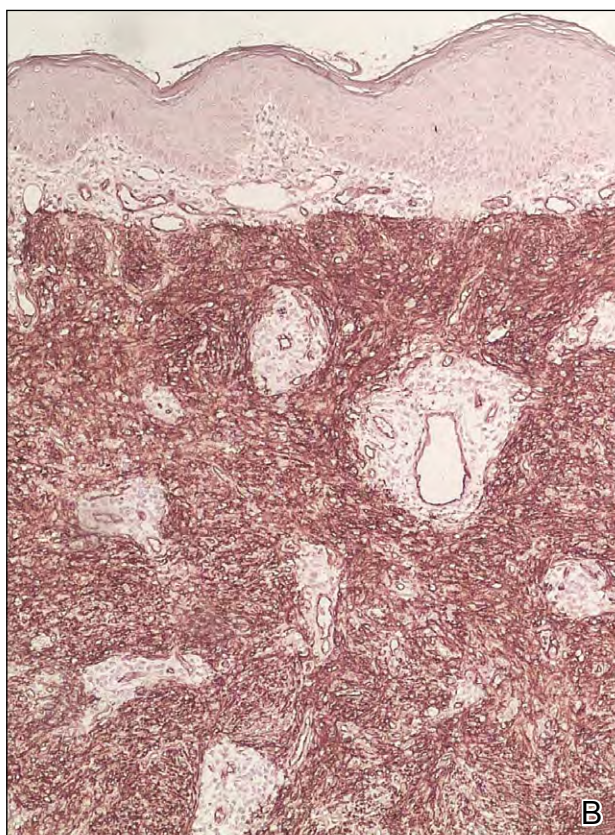
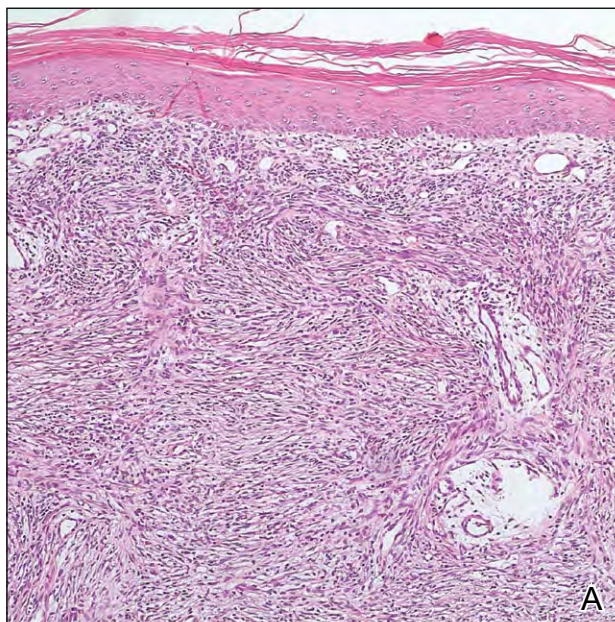


**Figure 1.** Erythematous reddish macules and confluent plaques on the right buttock extending to the iliac region and gluteal fold with a close-up of one of the larger lesions (inset).

Drs. Moraes, Calixto de Araújo, Gomes, Coutinho, and Costa are from the Hospital Universitário de Brasília, Universidade de Brasília, Brasil. Drs. Moraes, Gomes, Coutinho, and Costa are from the Department of Dermatology, and Dr. Calixto de Araújo is from the Department of Anatomic Pathology. Dr. Souza is from the Department of Pediatric Surgery, Hospital Regional da Asa Norte, Brasília.

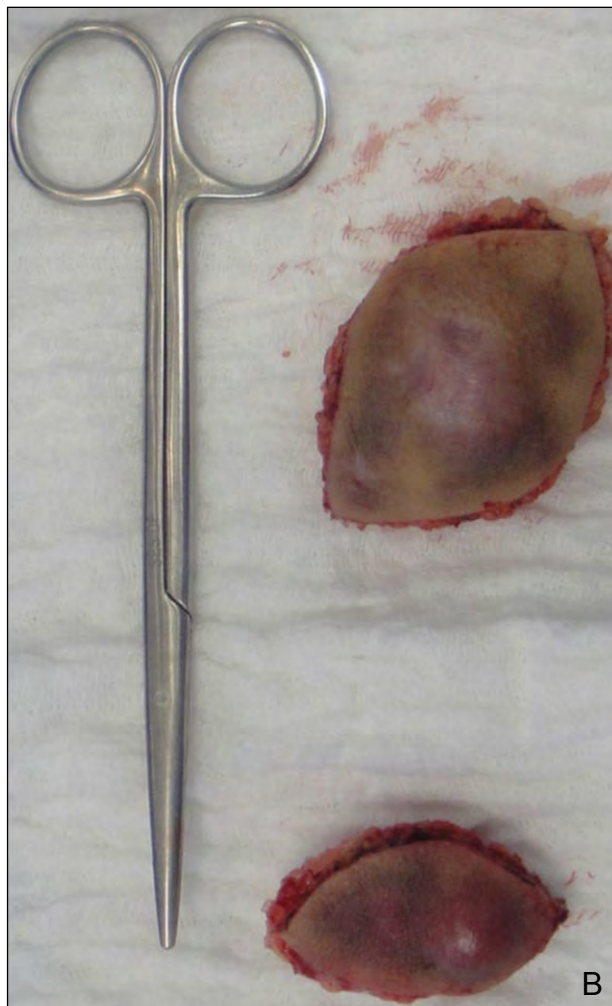
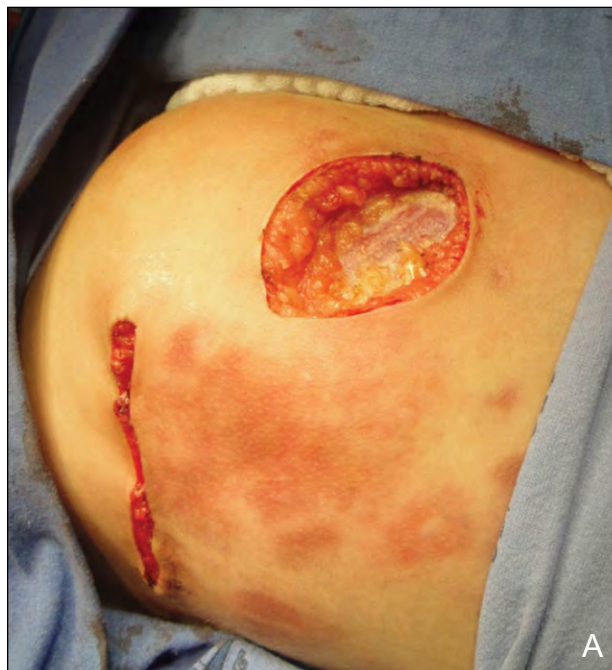The authors report no conflict of interest.

Correspondence: Izelda Maria Carvalho Costa, PhD, SHIS QI 17 Cj 08 Cs 02, Lago Sul, Brasília, Distrito Federal, Brasil CEP 71645-080 (izelda@unb.br).



**Figure 2.** Histologic examination revealed a monomorphous proliferation of spindle cells with elongated nuclei and slight variation in size and shape that were organized in a storiform pattern (A)(H&E, original magnification  $\times 40$ ). Immunohistochemistry showed CD34 positivity (B)(original magnification  $\times 40$ ).

extending from the papillary dermis to the hypodermis (Figure 2A). Immunohistochemistry was positive for CD34 (Figure 2B) and Ki-67 markers



**Figure 3.** Surgical excision (A and B) was completed before Mohs micrographic surgery.

and negative for S-100, desmin, pan-cytokeratin, neuron-specific enolase, and  $\alpha$  smooth muscle actin.

Based on clinical, histologic, and immunohistochemical data, a diagnosis of congenital dermatofibrosarcoma protuberans (DFSP) was made. Because of the wide extension of the lesion, a 3-step excision was proposed with a final step of Mohs micrographic surgery (MMS)(Figure 3).

### Comment

Dermatofibrosarcoma protuberans is a rare dermal and subcutaneous neoplasm that can be acquired or congenital in origin.<sup>1,2</sup> Its occurrence at birth and during childhood is rare with approximately 60 congenital cases reported. In adults, its incidence is 0.8 to 5 cases per million, occurring mainly during the third and fourth decades of life with an equal gender distribution.<sup>1,2</sup>

The dermatologic presentation of DFSP is heterogeneous. The lesion usually begins as a pink-, red-, yellow-, or flesh-colored plaque that indurates on palpation. It grows slowly but steadily, and it ultimately develops into an isolated or multilobular surface nodularity as the tumor growth progresses.<sup>1,3,4</sup> The trunk (42%–72%) and proximal extremities (16%–30%) are the main sites involved in patients with congenital DFSP or in adults.<sup>1,3</sup>

The clinical diagnosis of congenital or infantile DFSP may be difficult, as it sometimes resembles a vascular malformation or a birthmark. Other differential diagnoses may include scleroderma, lymphoma, sarcoidosis, melanoma, cutaneous metastases, keloids, a desmoid tumor, fibrosarcoma, appendage tumors, and dermatofibromas.<sup>3,4</sup>

Histologically, DFSP consists of a proliferation of monomorphic spindle cells organized in a storiform pattern. More frequently the tumor adopts an asymmetric fashion with microscopic tentaclelike projections emanating from the center of the tumor at random, enabling it to extend between healthy collagen, adipose tissue, fascia, and muscle.<sup>5</sup> Some of these characteristics were observed in our patient, with the lesion presenting several morphologic components and showing uninvolved skin tissue between patches and tumor nodules.

Although the histogenesis of DFSP is uncertain, histologic distinction between DFSP and dermatofibroma is important because their biologic behavior differs greatly. Immunohistochemical studies have been widely used to make the distinction. Dermatofibrosarcoma protuberans usually shows positivity for CD34 antigen and negativity for desmin, S-100, insulinlike growth factor-binding protein 7, and factor XIIIa.<sup>5</sup> Nevertheless, the fibrosarcomatous transformation of DFSP usually increases the tumor

proliferation index and leads to the loss of CD34 membrane expression, thereby worsening the prognosis, especially by its faster local progression and increased likelihood of lung metastasis.<sup>5</sup>

Tissue samples also may be used to establish the molecular diagnosis of DFSP using reverse transcriptase polymerase chain reaction or the fluorescence in situ hybridization assay. A translocation involving chromosomes 17 and 22 (t[17;22][q22;q13]) will lead to the fusion of the collagen type 1  $\alpha$  1 gene, *COL1A1* and the platelet-derived growth factor  $\beta$  polypeptide gene, *PDGFB*, determining the production of an anomalous fusion protein that is detected by diagnostic tests.<sup>6</sup> The protein activates the PDGF receptor protein tyrosine kinase of tumor cells, acting continuously as an autocrine or paracrine growth factor.<sup>6</sup>

Treatment of DFSP usually is wide local excision (WLE) with margins of 3 cm or more of clinically uninvolved skin and underlying fascia to avoid local recurrence. However, MMS has been proposed to be the gold standard given its capacity of detecting subclinical projections of neoplastic cells in the surrounding tissue as well as its observed ability to preserve more tissue and lower recurrence rates.<sup>1,2,7-9</sup> A review by Love et al<sup>2</sup> of 61 cases of congenital DFSP showed a clearance rate of 75% in patients who were treated with WLE (46/61; average follow-up of 1.9 years) compared to a 100% clearance rate in patients who were treated with MMS (11/11; average follow-up of 4.3 years). Another review of patients with congenital DFSP (n=5) and acquired infantile-type DFSP (n=20) showed no relapse following treatment with MMS.<sup>1</sup> Paradisi et al<sup>7</sup> reported an average local recurrence rate of 20.7% (288/1394) for WLE compared with 1.3% (6/463) for MMS (relative risk, 15.9; 95% confidence interval, 7.2-35.5). To date, MMS seems to be the most effective treatment of DFSP, and whenever possible, the use of paraffin-embedded sections may be preferred versus frozen sections.<sup>1,2,7-9</sup> A 3-step excision was proposed for our patient because of the lesion width. Because we aimed for a lower recurrence rate, we opted to perform the final step with MMS.

Imatinib mesylate, an orally active selective protein tyrosine kinase inhibitor against the PDGF receptor, has been approved by the US Food and Drug Administration for the treatment of unresectable, recurrent, and/or metastatic DFSP in adults. A study of 15 patients with locally advanced or initially inoperable and/or metastatic DFSP who were treated with imatinib mesylate for an average of 3.3 months before surgical excision showed a 2-year progression-free survival rate of 60% (9/15).<sup>10</sup>

Currently, imatinib mesylate has not been approved for use in patients younger than 18 years, though successful treatment in pediatric patients has been observed in case studies. Gooskens et al<sup>1</sup> reported 3 patients (aged 14 years, 3 years, and 12 months) with recurrent and/or locally advanced or initially inoperable tumors who received imatinib mesylate; the aim was complete resectability. All 3 patients had a positive response with a tumor size reduction that allowed surgical resection with histologically tumor-free margins. Imatinib mesylate was maintained in patients who showed molecular screening that was positive for *COL1A1-PDGFB* gene transcripts in resection margins. A follow-up ranging from 6 months to 3.5 years showed no relapse.<sup>1</sup>

### Conclusion

We emphasize the value of using histologic and immunohistochemical correlation as an auxiliary tool, especially with clinical presentation that encompasses differential diagnoses, to determine different treatments and a distinct prognosis. Furthermore, the surgical aspects of our patient with congenital DFSP highlight the knowledge of disease management and enhance the index of suspicion in the pediatric population.

### REFERENCES

1. Gooskens SL, Oranje AP, van Adrichem LN, et al. Imatinib mesylate for children with dermatofibrosarcoma protuberans (DFSP). *Pediatr Blood Cancer*. 2010;55:369-373.
2. Love WE, Keiler SA, Tamburro JE, et al. Surgical management of congenital dermatofibrosarcoma protuberans. *J Am Acad Dermatol*. 2009;61:1014-1023.
3. Jafarian F, McCuaig C, Kokta V, et al. Dermatofibrosarcoma protuberans in childhood and adolescence: report of eight patients. *Pediatr Dermatol*. 2008;25:317-325.
4. Weinstein JM, Drolet BA, Esterly NB, et al. Congenital dermatofibrosarcoma protuberans: variability in presentation. *Arch Dermatol*. 2003;139:207-211.
5. Patrizi A, Vespignani F, Fraternali GO, et al. A pediatric case of dermatofibrosarcoma protuberans: an immunohistochemical study. *Pediatr Dermatol*. 2000;17:29-33.
6. Simon MP, Pedeutour F, Sirvent N, et al. Deregulation of the platelet-derived growth factor B-chain gene via fusion with collagen gene *COL1A1* in dermatofibrosarcoma protuberans and giant-cell fibroblastoma. *Nat Genet*. 1997;15:95-98.
7. Paradisi A, Abeni D, Rusciani A, et al. Dermatofibrosarcoma protuberans: wide local excision vs. Mohs micrographic surgery [published online ahead of print August 5, 2008]. *Cancer Treat Rev*. 2008;34:728-736.
8. Tan WP, Barlow RJ, Robson A, et al. Dermatofibrosarcoma protuberans: 35 patients treated with Mohs micrographic surgery using paraffin sections. *Br J Dermatol*. 2011;164:363-366.
9. Roh MR, Bae B, Chung KY. Mohs' micrographic surgery for dermatofibrosarcoma protuberans. *Clin Exp Dermatol*. 2010;35:849-852.
10. Rutkowski P, Dębiec-Rychter M, Nowecki Z, et al. Treatment of advanced dermatofibrosarcoma protuberans with imatinib mesylate with or without surgical resection. *J Eur Acad Dermatol Venereol*. 2011;25:264-270.



### NEED MORE INFORMATION?

Access articles in our Pediatric Dermatology department online at [www.cutis.com](http://www.cutis.com)

- ▼ Lichen Planus: An Update and Review
- ▼ Menkes Syndrome Presenting as Possible Child Abuse
- ▼ Premature Hair Graying
- ▼ Varicella-Zoster Virus in Children Immunized With the Varicella Vaccine

Use our Advanced Search to find these recent articles and more online!