

Cutaneous Mastocytosis: A Case of Bullous Urticaria Pigmentosa

Ermira Vasili, MD; Irena Savo, MD; Xhiliola Doci, MD; Entela Shkodrani, MD; Asimo Ntemoy, MD

Mastocytosis is characterized by an increased number of mast cells with abnormal growth and accumulation in 1 or more organs. In children, mastocytosis is commonly cutaneous and patients present with a spectrum of findings, ranging from solitary or multiple mastocytomas to urticaria pigmentosa (UP) or diffuse cutaneous mastocytosis (CM). We present a case of a 4-month-old infant with bullous UP.

Cutis. 2013;91:70-72.

The term *mastocytosis* includes a heterogeneous group of disorders characterized by excessive mast cell proliferation and accumulation in tissues. These diseases can be limited to the skin (cutaneous mastocytosis [CM]) or involve extracutaneous tissues (systemic mastocytosis). Cutaneous mastocytosis is more common and approximately 75% of cases occur before 2 years of age.¹ Children with CM typically present with a spectrum of findings, ranging from solitary or multiple mastocytomas to urticaria pigmentosa (UP) or diffuse CM. Blistering may occur in infants, particularly those with UP or diffuse CM. We present the case of a 4-month-old male infant who was diagnosed with bullous UP, an aggressive form of UP that overlaps with bullous mastocytosis. Bullous UP primarily affects infants, and despite its alarming appearance, its resolution typically is spontaneous.¹

Case Report

A 4-month-old male infant was referred to the dermatology clinic for evaluation of a generalized bullous eruption of 3 months' duration that was associated with erythematous and hyperpigmented macules, urticarial elements, and itching localized on the trunk, extremities, and buttocks. The condition gradually became aggravated with the appearance of bullous elements that began increasing in number in the 2 weeks prior to presentation. The patient previously had been treated by a pediatrician who administered topical and oral antihistamines, which led to transient improvements.

Clinical examination revealed multiple tense bullae on the bilateral upper and lower extremities and trunk, some surrounded by erythema, multiple crusts, hyperpigmented macules, and hives (Figure 1). Scratch tests revealed immediate marked dermographism. The Darier sign also was observed. There was no family history of dermatologic disease. The patient's physical and psychomotor development was unaffected. Laboratory evaluation revealed a complete blood cell count within reference range. A radiologic skeletal survey also was performed; no abnormal findings were present. Abdominal ultrasonography did not show any hepatosplenomegaly or lymphadenopathy. The fluid from the bullae was sterile.

Histopathologic examination of lesional skin showed subepidermal bullae and infiltration of numerous mast cells in the papillary and reticular dermis (Figure 2). Metachromatic stain demonstrated mast cell granules that were bluish purple. Anti-*c-kit* (CD117) staining, which has a high specificity and sensitivity for mast cells, also was performed (Figure 3). A few eosinophils and neutrophils also were present in the dermis.

Based on the clinical and histologic findings, positive Darier sign, and absence of systemic involvement, the diagnosis of CM in the form of bullous UP was made. Symptomatic treatment with topical and oral antihistamines (H1 blockers) was effective.

Drs. Vasili, Savo, and Shkodrani are from the Department of Dermatovenerology, University Hospital Center Mother Theresa, Tirana, Albania. Dr. Doci is from the Department of Dermatovenerology, Durrës Regional Hospital, Albania. Dr. Ntemoy is from the Department of Anatomopathology, General Hospital of Ioannina G. Hatzikosta, Ioannina, Greece.

The authors report no conflict of interest.

Correspondence: Xhiliola Doci, MD, Spitali Rajonal Durrës, L: 8, RR: A. Goga, Durrës, Albania (xhilioladocimedecine@yahoo.com).

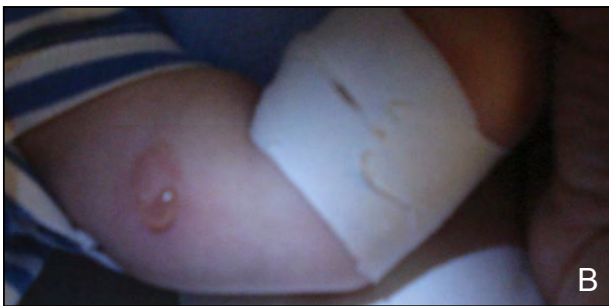
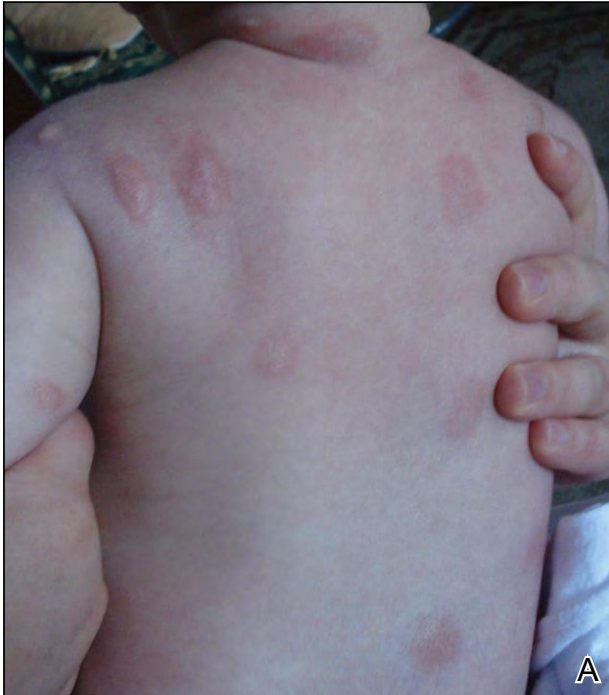

Figure 1. Hyperpigmented macules, bullae, and urticarial elements localized on the trunk (A) and upper extremity (B).

Improvement was noted during follow-up examination at 6 and 12 months with regression of bullous elements but persistence of hyperpigmented macules and positive Darier sign.

Comment

Mastocytosis is characterized by an increased number of mast cells with abnormal growth and accumulation in 1 or more organs. An excessive number of mast cells can be found in the skin, bone marrow, liver, spleen, lymph nodes, and/or gastrointestinal tract. The fundamental pathogenesis of mastocytosis is largely unknown. Mast cells express the receptor for stem cell factor, the receptor tyrosine kinase *c-kit* (CD117). Activated mutations of *c-kit* have been implicated in the pathogenesis of both CM and systemic mastocytosis.² Symptoms in patients with

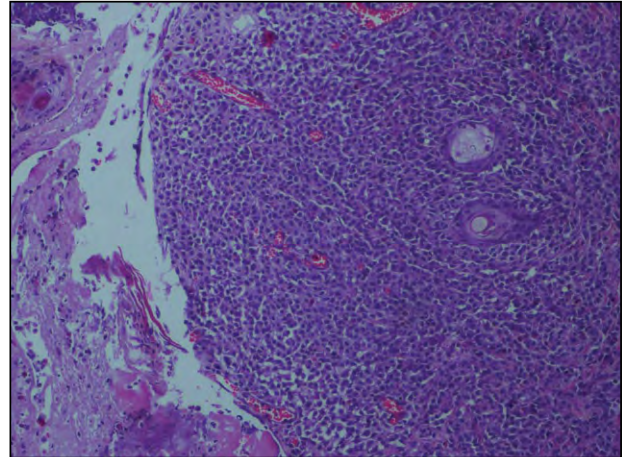


Figure 2. Skin biopsy specimen from the lesion on the patient's left forearm showed infiltration of mast cells in the dermis (H&E, original magnification $\times 10$).

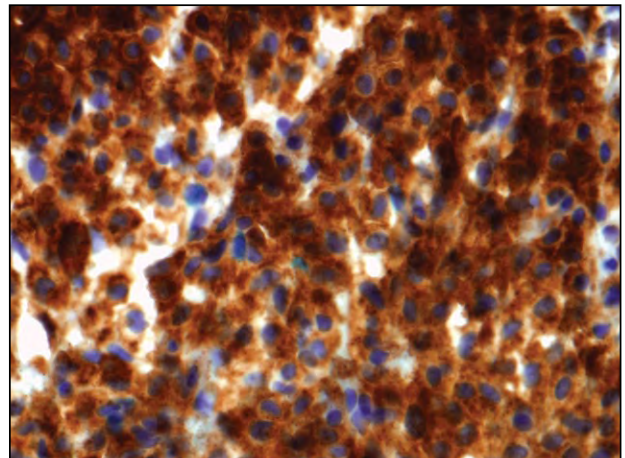


Figure 3. CD117 stain with a high specificity and sensitivity for mast cells (original magnification $\times 20$).

mastocytosis are caused by induced or spontaneous activation of mast cells, resulting in the release of vasoactive mediators such as histamine, arachidonic acid metabolites (eg, prostaglandin D₂, leukotriene C₄), proteases, and cytokines. Therefore, patients with mastocytosis often report recurrent flushing, anaphylaxis, and gastrointestinal tract symptoms such as cramping and diarrhea. In children, mastocytosis is commonly cutaneous and often transient when compared to adults who usually present with progressive and systemic disease.³ Almost all patients with CM belong in the indolent category of mastocytosis and thus have a good prognosis.⁴ Cutaneous mastocytosis of infancy and childhood frequently involutes spontaneously, which is not the case with CM in adults.⁵

Generally, there are 3 more common forms of CM in children: maculopapular CM (UP),

mastocytoma of skin, and diffuse CM.⁴ Urticaria pigmentosa may be present at birth and has been reported to appear in infancy and childhood at a median age of 2.5 months. By adolescence, symptoms gradually improve and resolve in approximately 50% of patients.⁶ Lesions are well-demarcated, red-brown, slightly elevated plaques averaging 0.5 to 1.5 cm in diameter and localized on any surface except for the palms and soles.⁵ Itching, flushing, and dermographism typically occur. Darier sign, the wheal and flare reaction observed following brisk stroking of the lesions, can be elicited. Infants may develop bullae and vesicles until 2 years of age; bullae rarely are observed in older patients. Bullous UP is best classified as an extreme form of UP that is difficult to distinguish from bullous mastocytosis, which is a form of diffuse CM. Marked mediator release leads to recurrent blister formation.¹ Blistered areas usually heal without scar formation, unless the lesions become secondarily infected. Extensive bullae can cause confusion and the development of other bullous diseases, such as scalded skin syndrome and bullous erythema multiforme.⁷ Bullous UP also might be differentiated from bullous genodermatosis, epidermolysis bullosa, epidermolytic hyperkeratosis, incontinentia pigmenti, and congenital syphilis.^{8,9}

The diagnosis of UP was made in our patient based on the clinical and histopathologic findings. Elevated plasma histamine levels are demonstrated in most children with mastocytosis, especially in those with diffuse CM. Histamine levels may be useful for identifying children at risk for gastrointestinal tract ulceration. Urinary histamine metabolites are more sensitive than plasma histamine and also correlate with bone marrow involvement. Serum tryptase levels are useful in the follow-up of patients with systemic mastocytosis.¹⁰

Management of the disease is symptomatic, as it is not possible to eradicate the disease.¹¹ Symptomatic therapies include H1 receptor blockers (eg, antihistamines, clemastine, ketotifen, cromoglicic acid); H2 receptor blockers (eg, ranitidine); aspirin for flushes, tachycardia, or fainting; and adequate calcium and vitamin D intake. Aspirin should be used with caution to avoid a hypotensive crisis.¹²

Preventative measures in systemic and extensive cases of CM in children are strongly recommended, including prevention of anaphylactic or anaphylactoid reactions in general; elimination of provoking factors; and avoidance of aspirin, nonsteroidal anti-inflammatory drugs, codeine, and polymyxin B. In patients with isolated cases of CM, regular 6- to 12-month follow-up is recommended.¹²

Conclusion

Bullous UP and bullous CM should be considered in the differential diagnosis in patients presenting with a bullous eruption of the skin. Our case helps to document the diagnosis of CM in the pediatric patient population.

REFERENCES

1. Braun-Falco O, Plewig G, Burgdorf WHC, et al. Mastocytoses. In: Braun-Falco O, Plewig G, Burgdorf WHC, et al. *Dermatology*. 2nd ed. New York, NY: Springer-Verlag; 2000:1649-1656.
2. Castells MC, Akin C. Clinical manifestations, pathogenesis, and classification of mastocytosis (cutaneous and systemic). *UpToDate*. <http://www.uptodate.com/contents/clinical-manifestations-pathogenesis-and-classification-of-mastocytosis-cutaneous-and-systemic>. Updated May 11, 2012. Accessed January 17, 2013.
3. Middelkamp Hup MA, Heide R, Tank B, et al. Comparison of mastocytosis with onset in children and adults. *J Eur Acad Dermatol Venereol*. 2002;16:115-120.
4. Valent P, Horny HP, Escribano L, et al. Diagnostic criteria and classification of mastocytosis: a consensus proposal. *Leuk Res*. 2001;25:603-625.
5. Wolff K, Komar M, Petzelbauer P. Clinical and histopathological aspects of cutaneous mastocytosis. *Leuk Res*. 2001;25:519-528.
6. Habif TP. Mastocytosis. In: Habif TP, ed. *Clinical Dermatology: A Color Guide to Diagnosis and Therapy*. 4th ed. London, England: Mosby; 2004:156-161.
7. Golitz LE, Weston WL, Lane AT. Bullous mastocytosis: diffuse cutaneous mastocytosis with extensive blisters mimicking scalded skin syndrome or erythema multiforme. *Pediatr Dermatol*. 1984;1:288-294.
8. Pielop JA. Vesiculobullous and pustular lesions in the newborn. *UpToDate*. http://www.uptodate.com/contents/vesiculobullous-and-pustular-lesions-in-the-newborn?source=search_result&search=vesiculobullous+and+pustular+lesions&selectedTitle=1%7E150. Updated January 24, 2012. Accessed January 17, 2013.
9. Chandra P, Velazquez E. Differential diagnosis of bullous skin lesions in the pediatric population [published online ahead of print June 28, 2008]. *J Cutan Pathol*. 2005;32:80.
10. Kiszewski AE, Durán-Mckinster C, Orozco-Covarrubias L, et al. Cutaneous mastocytosis in children: a clinical analysis of 71 cases. *J Eur Acad Dermatol Venereol*. 2004;18:285-290.
11. Katsamba AD, Karpouzis AJ, Koumantaki-Mathiodaki E, et al. Mastocytosis with skin manifestations: current status. *J Eur Acad Dermatol Venereol*. 1999;13:155-165.
12. Heide R, Beishuizen A, De Groot H, et al; Dutch National Mastocytosis Work Group. Mastocytosis in children: a protocol for management. *Pediatr Dermatol*. 2008;25:493-500.