

# Vitiliginous Lesions Induced by Amyl Nitrite Exposure

Kathleen Vine, MD; Marc Meulener, MD, PhD; Sherry Shieh, MD; Nanette B. Silverberg, MD

*Chemical (or contact) leukoderma is a condition induced by local cutaneous exposure to chemicals or medicaments that are toxic to melanocytes and/or koebnerize preexisting vitiligo vulgaris. Chemicals known to induce leukoderma include phenol/catechol derivatives (eg, hydroquinone), sulfhydryls, contact sensitizing agents (eg, squaric acid dibutylester), and more recently imiquimod, among others. We report the case of a 37-year-old black man with human immunodeficiency virus who developed chemical leukoderma in the nasal and perioral areas within 4 weeks of spilling liquid amyl nitrite, which he had been inhaling as a recreational drug, on his lower face. The depigmented regions were treated with a biweekly regimen of 308-nm excimer laser treatment for a total of 78 sessions. More than 90% cutaneous repigmentation was achieved. Amyl nitrite-induced vitiliginous lesions are rare. We also discuss potential mechanisms of hypopigmentation from chemical agents and therapeutic options for chemical leukoderma.*

*Cutis.* 2013;91:129-136.

**C**hemical (or contact) leukoderma is the physical lightening or depigmentation of skin or hair following exposure to an exogenous chemical. The clinical appearance of chemical leukoderma may resemble a localized area of vitiligo but differs from contact/occupational vitiligo in that the depigmentation is confined to the area(s) of initial

chemical exposure rather than spreading beyond the directly exposed skin.<sup>1</sup>

Many exogenous agents are used to lighten the skin and hair. The most commonly prescribed medications used to lighten or bleach the skin are hydroquinone and its derivatives (ie, monobenzyl ether, monomethyl ether, monoethyl ether).<sup>2,3</sup> Chemical leukoderma primarily has been described in vitiligo patients who use ammonia-based hair dyes, which have been found to be toxic to melanocytes, resulting in decreased or absent cutaneous pigmentation.<sup>4</sup> Other agents have been shown to induce leukoderma or vitiligo in patients following topical application, intralesional injection, or oral ingestion (Table).<sup>5,9</sup> Treatment of chemical leukoderma involves discontinued application of the offending agent(s) and use of topical vitiligo therapies. We report a case of facial chemical leukoderma following exposure to liquid amyl nitrite. The patient was successfully treated with an excimer laser.

## Case Report

A 37-year-old black man with human immunodeficiency virus (CD4 lymphocyte count, 924 cells/mm<sup>3</sup>; undetectable viral load) and seasonal allergies presented with acute-onset facial depigmentation of 3 months' duration. The patient did not have a history of vitiligo or other pigmentation disorders; he had no family history of vitiligo. He reported twice weekly recreational inhalation of amyl nitrite fumes for the last 3 to 4 years. Two months prior to presentation, the patient had accidentally spilled liquid amyl nitrite on the skin of the nasal and maxillary regions as well as the right nasolabial fold. Over 4 weeks the affected area began to peel, exposing "red, cracking skin" that was "sore, painful, itchy, and dry," according to the patient. Following localized facial skin peeling, the affected areas healed with depigmentation. The patient presented to the dermatology department seeking therapies for repigmentation.

Physical examination revealed well-demarcated depigmented patches along the distal nasal tip, nasal

---

From the Department of Dermatology, St. Luke's-Roosevelt Hospital Center, New York, New York, and Beth Israel Medical Center, New York.

The authors report no conflict of interest.

Correspondence: Nanette B. Silverberg, MD, Department of Dermatology, St. Luke's-Roosevelt Hospital Center, 1090 Amsterdam Ave, Ste 11D, New York, NY 10025 (nsilverb@chpnet.org).

### Mechanisms of Depigmentation for Known Select Compounds

Category	Specific Mechanism of Action	Topical Compound/Trauma	Other Pertinent Effects
Pre-melanin synthesis pathway	Decreased tyrosinase transcription	Tretinoin <sup>5</sup>	Unknown
	MITF downregulation	Lysophosphatidic acid <sup>6</sup> ; C2 ceramides <sup>7</sup> ; vitamin E <sup>8</sup>	Unknown
	Increased destruction of tyrosinase	Phospholipase D <sub>2</sub> <sup>9</sup> ; fatty acids <sup>10</sup>	Unknown
	Inhibition of tyrosinase maturation	Glycosphingolipids <sup>11</sup>	Unknown
Inhibition of melanin synthesis	Inhibition of tyrosinase via alternative substrate	Phenol/catechol derivatives (hydroquinone, <sup>12</sup> 4-hydroxyanisole, <sup>13</sup> monobenzone <sup>14</sup> )	Oxidative stress–mediated melanocytotoxic effect
		4-S-cysteaminyphenol and 4-S-cysteinylphenol <sup>15</sup>	Melanocytotoxicity via alkylation of cell proteins
		Resveratrol <sup>16</sup>	ROS scavenger; COX-2 inhibitor; anticancer activity
		Aloesin <sup>17</sup>	Noncompetitive inhibition of tyrosine hydroxylase
		Azelaic acid <sup>18</sup>	Unknown
	Copper chelation (required for tyrosinase activity)	Kojic acid <sup>19</sup> ; methyl gentisate <sup>20</sup>	Antioxidant activity; iron chelator; NF-κB inhibition
	Peroxidase inhibition	Ellagic acid <sup>21</sup> ; ascorbic acid (vitamin C) <sup>22</sup>	Scavenger activity
Glucocorticoids <sup>22</sup>		Unknown	
Inhibition of melanosome transfer	Koebnerization of vitiligo due to irritant reaction or trauma	Serine protease inhibitors <sup>23,24</sup> ; niacinamide (vitamin B <sub>3</sub> ) <sup>25</sup> ; lectins <sup>26</sup> ; neoglycoproteins <sup>26</sup>	Unknown
Melanocyte loss (vitiligo or complete chemical leukoderma)	Irritation/traumatic (koebnerization)	Tazarotene <sup>27</sup> ; eyebrow plucking <sup>28</sup> ; striae <sup>29-31</sup> ; radiotherapy <sup>32</sup> ; laser resurfacing <sup>33</sup> ; scratching <sup>34</sup>	Unknown

Category	Specific Mechanism of Action	Topical Compound/Trauma	Other Pertinent Effects
Melanocyte loss (vitiligo or complete chemical leukoderma) (continued)	Autoimmune activation of TLR-7/TLR-8 pathway	Imiquimod <sup>35,36</sup>	Unknown
	Allergic contact dermatitis	Phenols/catechols <sup>1,37</sup> (paratertiary-amyl-phenol, <sup>38</sup> <i>p-tert</i> -butylphenol, <sup>39</sup> monomethyl/monobenzyl ether <sup>40</sup> ); sulfhydryls <sup>1</sup> ; cinnamic aldehyde <sup>41</sup> ; alstroemeria <sup>42</sup> ; squaric acid dibutylester <sup>43</sup> ; carbyne <sup>44</sup> ; cerium oxide <sup>45</sup> ; diphencyprone <sup>46</sup> ; nickel <sup>47</sup> ; paraphenylenediamine <sup>48</sup> ; primula <sup>49</sup> ; arsenic <sup>50</sup> ; chloroquine <sup>51</sup> ; thiotepa <sup>52</sup> ; physostigmine <sup>53</sup> ; prolixin <sup>54</sup>	Unknown
Unknown		Imatinib <sup>55-58</sup>	Unknown

Abbreviations: MITF, microphthalmia-associated transcription factor; ROS, reactive oxygen species; COX-2, cyclooxygenase 2; NF-κB, nuclear factor κB; TLR, toll-like receptor.

alae, philtrum, and right nasolabial fold and maxilla following a splash pattern of amyl nitrite exposure (Figure, A and B). No nasopharyngeal mucosal lesions or ulcerations were present. No cervical lymphadenopathy was palpated. The patient was unwilling to undergo amyl nitrite patch testing or laboratory screening for glucose-6-phosphate dehydrogenase (G6PD) deficiency.

After topical treatments with tacrolimus ointment 0.1% and moisturizers were unsuccessful, a biweekly regimen of 308-nm excimer laser (XTRAC, PhotoMedex) treatments was started. The initial laser setting was 100 mJ/cm<sup>2</sup> with a treatment area of 100 cm<sup>2</sup>; dose strength was increased by 10% to 15% per session until session 20, at which point a fixed dose of 320 mJ/cm<sup>2</sup> was administered at each subsequent session. The treatments were well tolerated by the patient. Evidence of perifollicular repigmentation was observed following the third treatment; with each successive treatment, repigmentation increased and the remaining areas of facial depigmentation decreased (Figure, C–F). Following roughly 42 treatment sessions, the depigmentation was almost completely resolved and the patient was satisfied with the cosmetic results. He continued the excimer laser

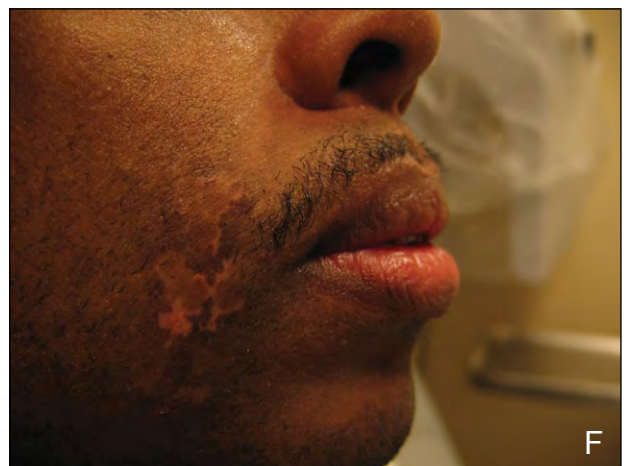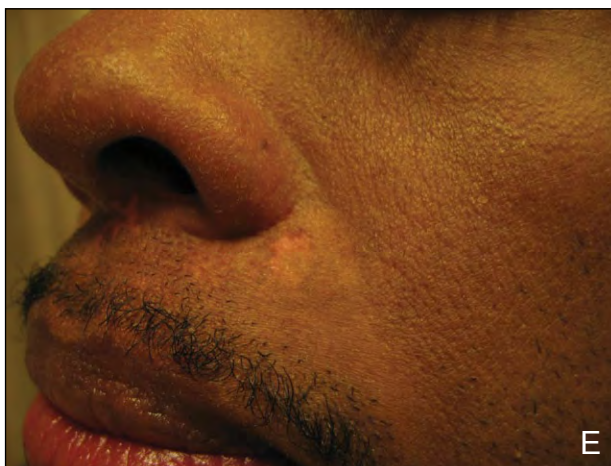
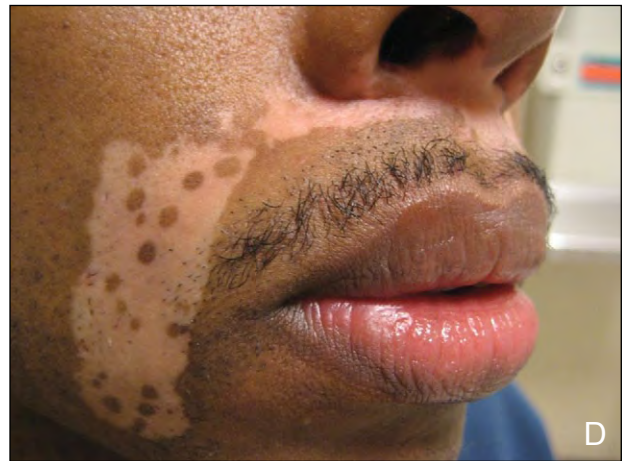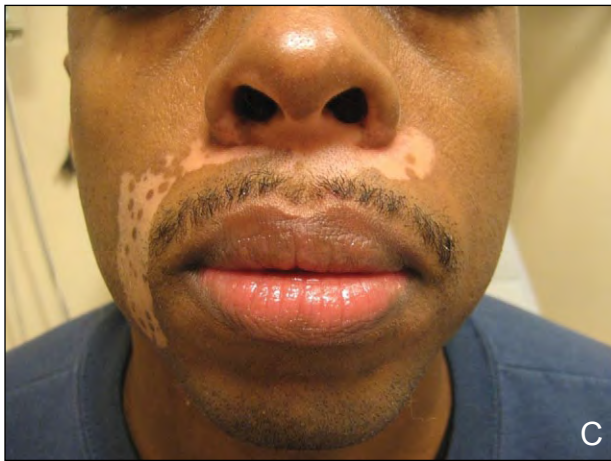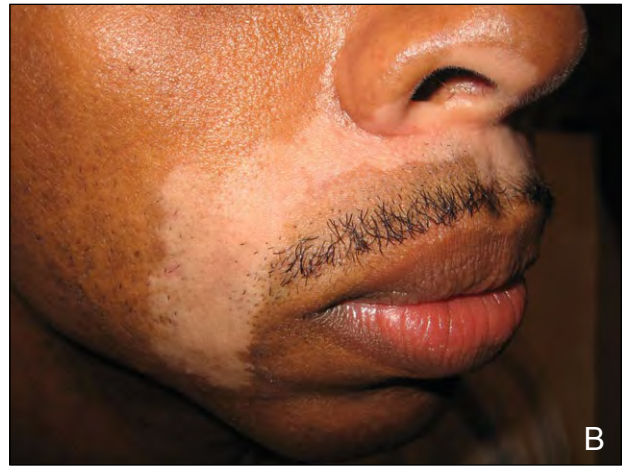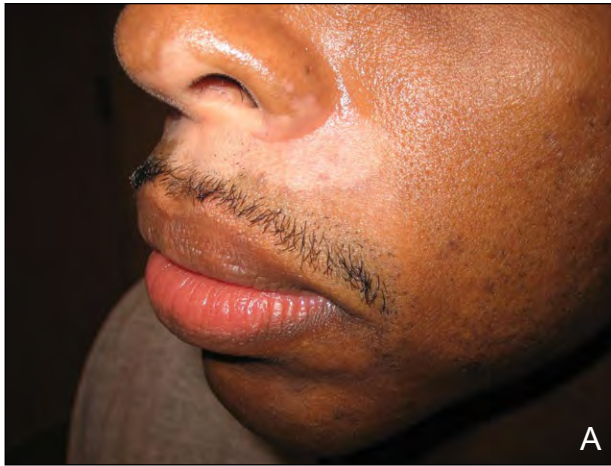therapy for a total of 78 sessions and achieved complete facial repigmentation.

### Comment

Vitiligo is the loss of cutaneous pigment caused by reduced melanin production, inactivity of pigment cells, and/or melanocyte destruction. Pigmentary disorders can cause substantial psychological impairment in patients.<sup>60</sup>

Unlike vitiligo, chemical leukoderma is an acquired hypomelanosis caused by chemical exposure, especially to phenol derivatives and sulfhydryls, which inhibit or interfere with melanin biosynthesis and dispersal.<sup>2</sup> Several potential mechanisms of hypopigmentation for a number of chemical agents have been proposed (Table); based on our case, we add chemical destruction of melanocytes and koebnerization of vitiligo within areas of chemically damaged skin. The latter mechanism is the primary cause of complete leukoderma, as opposed to the partial leukoderma induced by topical hydroquinones in the absence of vitiligo.

Alkyl nitrites such as amyl nitrite (CH<sub>3</sub>[CH<sub>2</sub>]<sub>4</sub>ONO<sub>2</sub>), butyl nitrite, and isopropyl nitrite are illegal recreational drugs (referred to as “poppers” or



Depigmented patches involving the nasolabial folds, philtrum, columella, and nasal alae after exposure to liquid amyl nitrite (A and B). After 12 treatments with an excimer laser, follicular repigmentation was observed (C and D); notable repigmentation was observed after 42 treatment sessions (E and F).

“liquid gold”<sup>61</sup> whose vapors are inhaled intranasally or orally. Because of their vasodilatory and methemoglobin-inducing effects, these compounds often are abused for enhanced sexual arousal and relaxation of the sphincter muscles.<sup>61</sup> Common side effects associated

with inhalation of alkyl nitrites include facial flushing, headache, dizziness, nausea, vomiting, decreased blood pressure, and an elevated pulse rate. Serious side effects including hypotension, tachycardia, syncope, and methemoglobinemia have been reported.<sup>62,63</sup>

Amyl nitrite-induced chemical leukoderma is rare. A possible mechanism of action is allergic contact dermatitis leading to melanocyte toxicity, similar to reactions caused by other known depigmenting contact allergens (Table). Cases of allergic contact dermatitis from alkyl nitrites have been reported in the literature.<sup>64-66</sup> Another potential mechanism of action is irritant contact dermatitis following exposure to liquid amyl nitrite, as koebnerization of vitiligo by irritants or physical trauma to the skin has been reported (Table). Additional possibilities include amyl nitrite-induced cytotoxicity of melanocytes as well as preexisting undiagnosed vitiligo that is either unmasked or exacerbated by amyl nitrite exposure.

The most likely mechanism of amyl nitrite-induced depigmentation is increased oxidative stress to the skin. Abuse of amyl nitrites can cause potentially fatal methemoglobinemia, especially in patients who are G6PD deficient.<sup>67-78</sup> Methemoglobinemia, a disorder in which increased levels of methemoglobin (an oxidized form of hemoglobin) cause tissue hypoxemia and increased oxidative stress,<sup>79</sup> is a mechanism strongly implicated in the pathogenesis of vitiligo.<sup>80-96</sup> Therefore, it is reasonable to hypothesize that cutaneous exposure to amyl nitrite may result in localized increases in oxidative stress from methemoglobinemia, resulting in melanocyte toxicity or death as well as the emergence of vitiligo in genetically susceptible individuals. Unfortunately, our patient declined G6PD testing.

Standard treatments of vitiliginous pigmentary disorders include topical preparations, phototherapy, surgical therapies, tattooing or cosmetic camouflage, and laser therapy. The 308-nm excimer laser has been found to be effective in the treatment of vitiligo<sup>97</sup>; efficacy in treating koebnerized vitiligo also has been demonstrated.<sup>98</sup> In our patient, treatment with an excimer laser was highly effective, and near-complete repigmentation of the affected area was achieved following roughly 42 treatment sessions.

## Conclusion

We present a rare case of amyl nitrite-induced chemical leukoderma that was successfully treated with an excimer laser. The likely mechanisms of our patient's facial depigmentation include chemical melanocyte destruction through hypoxemia and increased oxidative stress as well as koebnerization of vitiligo within areas of chemically damaged skin. Amyl nitrite should be added to the list of agents that can potentially induce chemical leukoderma, and caution is advised for those individuals who may be exposed to this potentially depigmenting substance.

**Acknowledgment**—The authors would like to thank Raymond E. Boissy, PhD, of the National Vitiligo Foundation for his thoughts and discussion in the development of this article.

## REFERENCES

1. Boissy RE, Manga P. On the etiology of contact/occupational vitiligo. *Pigment Cell Res.* 2004;17:208-214.
2. Solano F, Briganti S, Picardo M, et al. Hypopigmenting agents: an updated review on biological, chemical and clinical aspects. *Pigment Cell Res.* 2006;19:550-571.
3. Bleehen SS, Pathak MA, Hori Y, et al. Depigmentation of skin with 4-isopropylcatechol, mercaptoamines, and other compounds. *J Invest Dermatol.* 1968;50:103-117.
4. Roeleveld CG, van Ketel WG. Allergic reaction to a hair dye elicited by an ointment containing DMSO. *Contact Dermatitis.* 1975;1:331.
5. Sato K, Morita M, Ichikawa C, et al. Depigmenting mechanisms of all-trans retinoic acid and retinol on B16 melanoma cells [published online ahead of print October 7, 2008]. *Biosci Biotechnol Biochem.* 2008;72:2589-2597.
6. Kim DS, Park SH, Kwon SB, et al. Effects of lysophosphatidic acid on melanogenesis. *Chem Phys Lipids.* 2004;127:199-206.
7. Kim DS, Park SH, Park KC. Transforming growth factor- $\beta$ 1 decreases melanin synthesis via delayed extracellular signal-regulated kinase activation. *Int J Biochem Cell Biol.* 2004;36:1482-1491.
8. Funasaka Y, Chakraborty AK, Komoto M, et al. The depigmenting effect of  $\alpha$ -tocopheryl ferulate on human melanoma cells. *Br J Dermatol.* 1999;141:20-29.
9. Kageyama A, Oka M, Okada T, et al. Down-regulation of melanogenesis by phospholipase D2 through ubiquitin proteasome-mediated degradation of tyrosinase [published online ahead of print April 5, 2004]. *J Biol Chem.* 2004;279:27774-27780.
10. Ando H, Watabe H, Valencia JC, et al. Fatty acids regulate pigmentation via proteasomal degradation of tyrosinase: a new aspect of ubiquitin-proteasome function [published online ahead of print January 22, 2004]. *J Biol Chem.* 2004;279:15427-15433.
11. Sprong H, Degroote S, Claessens T, et al. Glycosphingolipids are required for sorting melanosomal proteins in the Golgi complex [published online ahead of print October 22, 2001]. *J Cell Biol.* 2001;155:369-380.
12. Jimbow K, Obata H, Pathak MA, et al. Mechanism of depigmentation by hydroquinone. *J Invest Dermatol.* 1974;62:436-449.
13. Riley PA, Sawyer B, Wolf MA. The melanocytotoxic action of 4-hydroxyanisole. *J Invest Dermatol.* 1975;64:86-89.
14. Grojean MF, Thivolet J, Perrot H. Acquired leukomelanoderma caused by topical depigmenting agents [in French]. *Ann Dermatol Venerol.* 1982;109:641-647.

15. Ito Y, Jimbow K, Ito S. Depigmentation of black guinea pig skin by topical application of cysteaminyphenol, cysteinylphenol, and related compounds. *J Invest Dermatol.* 1987;88:77-82.
16. Ohguchi K, Tanaka T, Kido T, et al. Effects of hydroxy-stilbene derivatives on tyrosinase activity. *Biochem Biophys Res Commun.* 2003;307:861-863.
17. Jones K, Hughes J, Hong M, et al. Modulation of melanogenesis by aloesin: a competitive inhibitor of tyrosinase. *Pigment Cell Res.* 2002;15:335-340.
18. Schallreuter KU, Wood JW. A possible mechanism of action for azelaic acid in the human epidermis. *Arch Dermatol Res.* 1990;282:168-171.
19. Noh JM, Kwak SY, Seo HS, et al. Kojic acid-amino acid conjugates as tyrosinase inhibitors [published online ahead of print August 14, 2009]. *Bioorg Med Chem Lett.* 2009;19:5586-5589.
20. Curto EV, Kwong C, Hermersdörfer H, et al. Inhibitors of mammalian melanocyte tyrosinase: in vitro comparisons of alkyl esters of gentisic acid with other putative inhibitors. *Biochem Pharmacol.* 1999;57:663-672.
21. Yoshimura M, Watanabe Y, Kasai K, et al. Inhibitory effect of an ellagic acid-rich pomegranate extract on tyrosinase activity and ultraviolet-induced pigmentation. *Biosci Biotechnol Biochem.* 2005;69:2368-2373.
22. Kasraee B. Peroxidase-mediated mechanisms are involved in the melanocytotoxic and melanogenesis-inhibiting effects of chemical agents. *Dermatology.* 2002;205:329-339.
23. Seiberg M, Paine C, Sharlow E, et al. Inhibition of melanosome transfer results in skin lightening. *J Invest Dermatol.* 2000;115:162-167.
24. Seiberg M, Paine C, Sharlow E, et al. The protease-activated receptor 2 regulates pigmentation via keratinocyte-melanocyte interactions. *Exp Cell Res.* 2000;254:25-32.
25. Hakozaiki T, Minwalla L, Zhuang J, et al. The effect of niacinamide on reducing cutaneous pigmentation and suppression of melanosome transfer. *Br J Dermatol.* 2002;147:20-31.
26. Minwalla L, Zhao Y, Cornelius J, et al. Inhibition of melanosome transfer from melanocytes to keratinocytes by lectins and neoglycoproteins in an in vitro model system. *Pigment Cell Res.* 2001;14:185-194.
27. Narang T, Dogra S, Kumar U, et al. Tazarotene-induced irritation causing vitiligo by Koebnerization. *J Eur Acad Dermatol Venereol.* 2007;21:988-989.
28. Verma SB. Vitiligo koebnerized by eyebrow plucking by threading. *J Cosmet Dermatol.* 2002;1:214-215.
29. Iftikhar N, Rahman A, Janjua SA. Vitiligo appearing in striae distensae as a Koebner phenomenon. *J Coll Physicians Surg Pak.* 2009;19:796-797.
30. Verma SB. Striae: stretching the long list of precipitating factors for 'true koebnerization' of vitiligo, lichen planus and psoriasis [published online ahead of print June 1, 2009]. *Clin Exp Dermatol.* 2009;34:880-883.
31. Verma SB. Vitiligo precipitated by striae: a little known entity [published online ahead of print June 11, 2008]. *J Eur Acad Dermatol Venereol.* 2009;23:357-358.
32. Polat M, Yalçın B, Alli N. Vitiligo at the site of radiotherapy for nasopharyngeal carcinoma. *Am J Clin Dermatol.* 2007;8:247-249.
33. Bernstein LJ, Kauvar AN, Grossman MC, et al. The short- and long-term side effects of carbon dioxide laser resurfacing. *Dermatol Surg.* 1997;23:519-525.
34. Levai M. The relationship of pruritus and local skin conditions to the development of vitiligo. *AMA Arch Dermatol.* 1958;78:372-377.
35. Brown T, Zirvi M, Cotsarelis G, et al. Vitiligo-like hypopigmentation associated with imiquimod treatment of genital warts. *J Am Acad Dermatol.* 2005;52:715-716.
36. Fleming CJ, Bryden AM, Evans A, et al. A pilot study of treatment of lentigo maligna with 5% imiquimod cream. *Br J Dermatol.* 2004;151:485-488.
37. Briganti S, Camera E, Picardo M. Chemical and instrumental approaches to treat hyperpigmentation. *Pigment Cell Res.* 2003;16:101-110.
38. Chumakov NN, Babanov GP, Smirnov AG. On vitiligo-like dermatoses in workers in the phenol-formaldehyde resin works [in Russian]. *Vestn Dermatol Venerol.* 1962;36:3-8.
39. James O, Mayes RW, Stevenson CJ. Occupational vitiligo induced by p-tert-butylphenol, a systemic disease? *Lancet.* 1977;2:1217-1219.
40. Denton CR, Lerner AB, Fitzpatrick TB. Inhibition of melanin formation by chemical agents. *J Invest Dermatol.* 1952;18:119-135.
41. Mathias CG, Maibach HI, Conant MA. Perioral leukoderma simulating vitiligo from use of a toothpaste containing cinnamic aldehyde. *Arch Dermatol.* 1980;116:1172-1173.
42. Björkner BE. Contact allergy and depigmentation from alstroemeria. *Contact Dermatitis.* 1982;8:178-184.
43. Valsecchi R, Cainelli T. Depigmentation from squaric acid dibutylester. *Contact Dermatitis.* 1984;10:109.
44. Brancaccio RR, Chamales MH. Contact dermatitis and depigmentation produced by the herbicide Carbyne. *Contact Dermatitis.* 1977;3:108-109.
45. Rapaport MJ. Depigmentation with cerium oxide. *Contact Dermatitis.* 1982;8:282-283.
46. Hatzis J, Gourgiotou K, Tosca A, et al. Vitiligo as a reaction to topical treatment with diphenylprone. *Dermatologica.* 1988;177:146-148.
47. Silvestre JF, Botella R, Ramón R, et al. Periumbilical contact vitiligo appearing after allergic contact dermatitis to nickel. *Am J Contact Dermat.* 2001;12:43-44.
48. Jappe U, Hausen BM, Petzoldt D. Erythema-multiforme-like eruption and depigmentation following allergic contact dermatitis from a paint-on henna tattoo, due to para-phenylenediamine contact hypersensitivity. *Contact Dermatitis.* 2001;45:249-250.

49. Bhushan M, Beck MH. Allergic contact dermatitis from primula presenting as vitiligo. *Contact Dermatitis*. 1999;41:292-293.
50. Bickley LK, Papa CM. Chronic arsenicism with vitiligo, hyperthyroidism, and cancer. *NJ Med*. 1989;86:377-380.
51. Gonggryp LA, Kalla AA. Chloroquine-induced vitiligo in a patient with juvenile onset rheumatoid arthritis. *Br J Rheumatol*. 1992;31:790-791.
52. Harben DJ, Cooper PH, Rodman OG. Thiotepe-induced leukoderma. *Arch Dermatol*. 1979;115:973-974.
53. Jacklin HN. Depigmentation of the eyelids in eserine allergy. *Am J Ophthalmol*. 1965;59:89-92.
54. Rampertaap MP. Vitiligo-like syndrome following the use of fluphenazine enanthate. *Mo Med*. 1985;82:24-26.
55. Cerchione C, Fabbri R, Pane F, et al. Vitiligo-like lesions in an adult patient treated with Imatinib mesylate [published online ahead of print February 20, 2009]. *Leuk Res*. 2009;33:e104-e105.
56. Cario-André M, Ardilouze L, Pain C, et al. Imatinib mesilate inhibits melanogenesis in vitro. *Br J Dermatol*. 2006;155:493-494.
57. Brazzelli V, Roveda E, Prestinari F, et al. Vitiligo-like lesions and diffuse lightening of the skin in a pediatric patient treated with imatinib mesylate: a noninvasive colorimetric assessment. *Pediatr Dermatol*. 2006;23:175-178.
58. Legros L, Cassuto JP, Ortonne JP. Imatinib mesilate (Glivec): a systemic depigmenting agent for extensive vitiligo? *Br J Dermatol*. 2005;153:691-692.
59. Whitton ME, Pinart M, Batchelor J, et al. Interventions for vitiligo. *Cochrane Database Syst Rev*. 2010;20:CD003263 .doi:10.1002/14651858.CD003263.pub4.
60. Kostopoulou P, Jouary T, Quintard B, et al. Objective vs. subjective factors in the psychological impact of vitiligo: the experience from a French referral centre [published online ahead of print March 9, 2009]. *Br J Dermatol*. 2009;161:128-133.
61. Carey JW, Mejia R, Bingham T, et al. Drug use, high-risk sex behaviors, and increased risk for recent HIV infection among men who have sex with men in Chicago and Los Angeles [published online ahead of print March 23, 2008]. *AIDS Behav*. 2009;13:1084-1096.
62. Mason DT, Braunwald E. The effects of nitroglycerin and amyl nitrite on arteriolar and venous tone in the human forearm. *Circulation*. 1965;32:755-766.
63. Edwards RJ, Ujma J. Extreme methaemoglobinaemia secondary to recreational use of amyl nitrite. *J Accid Emerg Med*. 1995;12:138-142.
64. Romaguera C, Grimalt F. Contact dermatitis from nasal sprays and amyl nitrite. *Contact Dermatitis*. 1982;8:266-267.
65. Fisher AA, Brancaccio RR, Jelinek JE. Facial dermatitis in men due to inhalation of butyl nitrite. *Cutis*. 1981;27:146, 152-153.
66. Fisher AA. "Poppers" or "snappers" dermatitis in homosexual men. *Cutis*. 1984;34:118-122.
67. Lindenmann J, Matzi V, Kaufmann P, et al. Hyperbaric oxygenation in the treatment of life-threatening isobutyl nitrite-induced methemoglobinemia—a case report. *Inhal Toxicol*. 2006;18:1047-1049.
68. Jansen T, Barnung S, Mortensen CR, et al. Isobutyl-nitrite-induced methemoglobinemia; treatment with an exchange blood transfusion during hyperbaric oxygenation. *Acta Anaesthesiol Scand*. 2003;47:1300-1301.
69. Zijlstra WG. Methemoglobinemia due to ingestion of isobutyl nitrite ('poppers') [in Dutch][letter]. *Ned Tijdschr Geneesk*. 2003;147:1144.
70. Zijlstra WG. Methemoglobinemia due to ingestion of isobutyl nitrite ('poppers') [in Dutch] [letter]. *Ned Tijdschr Geneesk*. 2003;147:522-523.
71. Wolfhagen FH. Methemoglobinemia due to ingestion of isobutyl nitrite ('poppers') [in Dutch][letter]. *Ned Tijdschr Geneesk*. 2003;147:468-469.
72. Pruijm MT, de Meijer PH. Methemoglobinemia due to ingestion of isobutyl nitrite ('poppers') [in Dutch][letter]. *Ned Tijdschr Geneesk*. 2002;146:2370-2373.
73. Goulle JP, Rigaud JP, Nouveau J, et al. Severe methemoglobinemia after inhalation of "poppers" [in French]. *Presse Med*. 1994;23:1833.
74. Bradberry SM, Whittington RM, Parry DA, et al. Fatal methemoglobinemia due to inhalation of isobutyl nitrite. *J Toxicol Clin Toxicol*. 1994;32:179-184.
75. O'Toole JB 3rd, Robbins GB, Dixon DS. Ingestion of isobutyl nitrite, a recreational chemical of abuse, causing fatal methemoglobinemia. *J Forensic Sci*. 1987;32:1811-1812.
76. Guss DA, Normann SA, Manoguerra AS. Clinically significant methemoglobinemia from inhalation of isobutyl nitrite. *Am J Emerg Med*. 1985;3:46-47.
77. Dixon DS, Reisch RF, Santinga PH. Fatal methemoglobinemia resulting from ingestion of isobutyl nitrite, a "room odorizer" widely used for recreational purposes. *J Forensic Sci*. 1981;26:587-593.
78. Shesser R, Mitchell J, Edelstein S. Methemoglobinemia from isobutyl nitrite preparations. *Ann Emerg Med*. 1981;10:262-264.
79. Prabhakar NR, Kumar GK. Oxidative stress in the systemic and cellular responses to intermittent hypoxia. *Biol Chem*. 2004;385:217-221.
80. Liu Y, Meng XW, Zhou LY, et al. Genetic polymorphism and mRNA levels of cytochrome P450IIE1 and glutathione S-transferase P1 in patients with alcoholic liver disease in different nationalities. *Hepatobiliary Pancreat Dis Int*. 2009;8:162-167.
81. Jalel A, Yassine M, Hamdaoui MH. Oxidative stress in experimental vitiligo C57BL/6 mice. *Indian J Dermatol*. 2009;54:221-224.
82. Zhou Z, Li CY, Li K, et al. Decreased methionine sulphoxide reductase A expression renders melanocytes more sensitive to oxidative stress: a possible cause for melanocyte loss in vitiligo [published online ahead of print May 5, 2009]. *Br J Dermatol*. 2009;161:504-509.

83. Sravani PV, Babu NK, Gopal KV, et al. Determination of oxidative stress in vitiligo by measuring superoxide dismutase and catalase levels in vitiliginous and non-vitiliginous skin. *Indian J Dermatol Venereol Leprol.* 2009;75:268-271.
84. Arican O, Kurutas EB. Oxidative stress in the blood of patients with active localized vitiligo. *Acta Dermatovenerol Alp Pannonica Adriat.* 2008;17:12-16.
85. Shalhaf M, Gibbons NC, Wood JM, et al. Presence of epidermal allantoin further supports oxidative stress in vitiligo [published online ahead of print March 4, 2008]. *Exp Dermatol.* 2008;17:761-770.
86. Em S, Laddha NC, Chatterjee S, et al. Association of catalase T/C exon 9 and glutathione peroxidase codon 200 polymorphisms in relation to their activities and oxidative stress with vitiligo susceptibility in Gujarat population. *Pigment Cell Res.* 2007;20:405-407.
87. Namazi MR. Neurogenic dysregulation, oxidative stress, autoimmunity, and melanocytorrhagy in vitiligo: can they be interconnected? *Pigment Cell Res.* 2007;20:360-363.
88. Schallreuter KU, Gibbons NC, Zothner C, et al. Hydrogen peroxide-mediated oxidative stress disrupts calcium binding on calmodulin: more evidence for oxidative stress in vitiligo [published online ahead of print June 11, 2007]. *Biochem Biophys Res Commun.* 2007;360:70-75.
89. Schallreuter KU, Gibbons NC, Zothner C, et al. Butyrylcholinesterase is present in the human epidermis and is regulated by H<sub>2</sub>O<sub>2</sub>: more evidence for oxidative stress in vitiligo [published online ahead of print August 31, 2006]. *Biochem Biophys Res Commun.* 2006;349:931-938.
90. Spencer JD, Gibbons NC, Rokos H, et al. Oxidative stress via hydrogen peroxide affects proopiomelanocortin peptides directly in the epidermis of patients with vitiligo [published online ahead of print August 31, 2006]. *J Invest Dermatol.* 2007;127:411-420.
91. Schallreuter KU, Rokos H. Turmeric (curcumin): a widely used curry ingredient, can contribute to oxidative stress in Asian patients with acute vitiligo. *Indian J Dermatol Venereol Leprol.* 2006;72:57-59.
92. Schallreuter KU, Elwary SM, Gibbons NC, et al. Activation/deactivation of acetylcholinesterase by H<sub>2</sub>O<sub>2</sub>: more evidence for oxidative stress in vitiligo. *Biochem Biophys Res Commun.* 2004;315:502-508.
93. Rokos H, Beazley WD, Schallreuter KU. Oxidative stress in vitiligo: photo-oxidation of pterins produces H(2)O(2) and pterin-6-carboxylic acid. *Biochem Biophys Res Commun.* 2002;292:805-811.
94. Jimbow K, Chen H, Park JS, et al. Increased sensitivity of melanocytes to oxidative stress and abnormal expression of tyrosinase-related protein in vitiligo. *Br J Dermatol.* 2001;144:55-65.
95. Schallreuter KU. Successful treatment of oxidative stress in vitiligo. *Skin Pharmacol Appl Skin Physiol.* 1999;12:132-138.
96. Passi S, Grandinetti M, Maggio F, et al. Epidermal oxidative stress in vitiligo. *Pigment Cell Res.* 1998;11:81-85.
97. Passeron T, Ortonne JP. Use of the 308-nm excimer laser for psoriasis and vitiligo. *Clin Dermatol.* 2006;24:33-42.
98. Friedman PM, Geronemus RG. Use of the 308-nm excimer laser for postresurfacing leukoderma. *Arch Dermatol.* 2001;137:824-825.