

# Incidental (Malignancy) and Coincidental (Idiopathic Polydactylous Longitudinal Erythronychia) Conditions in Patients With Segmental Neurofibromatosis

Philip R. Cohen, MD

## Practice Points

- Segmental neurofibromatosis is a rare variant of neurofibromatosis type 1.
- Idiopathic polydactylous longitudinal erythronychia presents as single or multiple linear red bands on the nails.
- Tumors derived from neural crest cells may be observed in patients with segmental neurofibromatosis.
- Idiopathic polydactylous longitudinal erythronychia in a patient with segmental neurofibromatosis may be a coincidental finding.

*Segmental neurofibromatosis (SNF) is an uncommon presentation of neurofibromatosis type 1 (NF-1). Although patients with SNF are at a lower risk for developing NF-1-associated complications, the estimated occurrence of related malignancies may be approaching the frequency observed in patients with NF-1. Idiopathic polydactylous longitudinal erythronychia also may be associated with SNF, though the frequency of this association remains to be determined.*

*Cutis.* 2013;91:179-180.

Segmental neurofibromatosis (SNF) is an uncommon variant of neurofibromatosis type 1 (NF-1).<sup>1</sup> Evidence suggests that the incidence of cancer in patients with SNF may approach the lifetime risk for malignancy in patients with NF-1.<sup>2</sup> In addition to this incidental association regarding the development of SNF-associated visceral neoplasms, the

coincidental finding of idiopathic polydactylous longitudinal erythronychia in a patient with SNF also has been observed.<sup>3</sup>

Neurofibromatosis type 1 is a genodermatosis with malignant potential.<sup>4,5</sup> Segmental neurofibromatosis currently is considered to be a rare variant of NF-1.<sup>1,2,6,7</sup> Several genodermatosis-associated malignancies have been observed in patients with NF-1 (Table).<sup>2</sup> A man with SNF who developed Hodgkin lymphoma also has been reported.<sup>6</sup> In a related article, the incidence and types of cancers in patients with SNF were reviewed, with half (5/10) of the patients having tumors derived from neural crest cells (ie, malignant peripheral nerve sheath tumor, malignant melanoma)(Table).<sup>2</sup>

Idiopathic polydactylous longitudinal erythronychia initially was reported by Baran et al<sup>8</sup>; 5 individuals with this rare condition were described. Another patient with this nail dyschromia was subsequently mentioned by Baran<sup>9</sup> in a more recently published report on the red nail. Idiopathic polydactylous longitudinal erythronychia presents as single or multiple linear red bands that extend from either the proximal nail fold or the distal lunula and reach the distal free edge of the nail; the pathogenesis of this uncommon benign variant of longitudinal erythronychia has yet to be established.<sup>10</sup>

From the Department of Dermatology, University of Texas MD Anderson Cancer Center, Houston; the Department of Dermatology, University of Texas Medical School at Houston; and the Division of Dermatology, University of California, San Diego.

The author reports no conflict of interest.

Correspondence: Philip R. Cohen, MD (mitehead@gmail.com).

## Neurofibromatosis and Malignancy

### NF-1<sup>a</sup>

Malignant peripheral nerve sheath tumor  
 Carcinoid tumor  
 Juvenile chronic myelogenous leukemia  
 Lymphoma (mostly non-Hodgkin lymphoma)  
 Medullary thyroid carcinoma  
 Meningioma  
 Optic glioma  
 Pheochromocytoma  
 Rhabdomyosarcoma  
 Wilms tumor

### SNF<sup>b,c</sup>

Malignant peripheral nerve sheath tumor  
 Malignant melanoma  
 Breast cancer  
 Colon cancer  
 Gastric cancer  
 Lung cancer  
 Hodgkin lymphoma

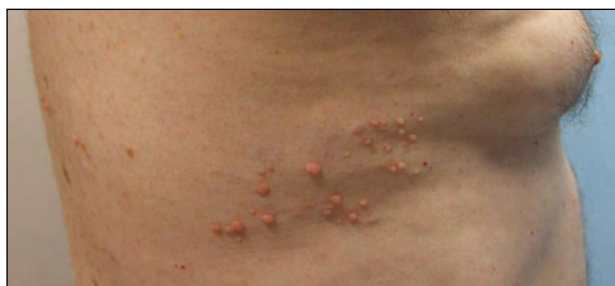Abbreviations: NF-1, neurofibromatosis type 1; SNF, segmental neurofibromatosis.

<sup>a</sup>Lifetime risk, 7%.

<sup>b</sup>Lifetime risk, 5.3%.

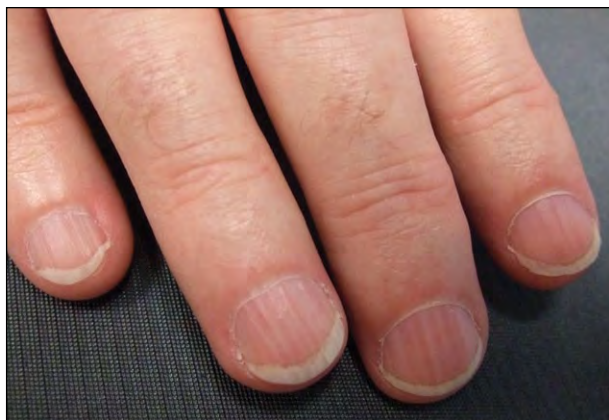
<sup>c</sup>Most commonly associated malignancies in decreasing order of frequency.

Data from Dang and Cohen.<sup>2</sup>



**Figure 1.** Flesh-colored, biopsy-confirmed neurofibromas located on the right lateral chest in a T5-T7 dermatomal distribution in a man with segmental neurofibromatosis.

Biopsy-confirmed SNF and idiopathic polydactylous longitudinal erythronychia were observed in a 56-year-old man.<sup>3</sup> The patient presented with more than 25 flesh-colored dermal papules and nodules in a T5-T7 dermatomal distribution on the right lateral chest (Figure 1); no café au lait macules were present, and there was no family history of neurofibromatosis. Single and multiple longitudinal red bands on all fingernails were coincidental findings (Figure 2).<sup>3</sup>



**Figure 2.** Idiopathic polydactylous longitudinal erythronychia on the fingernails of the right hand of a 56-year-old man with segmental neurofibromatosis. Multiple narrow linear red bands extended from the proximal nail fold to the free end of the nail plate.

Segmental neurofibromatosis is an uncommon presentation of NF-1. Although patients with SNF are at a lower risk for developing NF-1–associated complications, the estimated occurrence of related malignancies in these patients may be approaching the frequency observed in patients with NF-1. The importance of idiopathic polydactylous longitudinal erythronychia in a patient with SNF remains to be determined, and the observation of this rare nail finding may be merely coincidental.

## REFERENCES

1. Mansur AT, Göktay F, Akkaya AD, et al. Segmental neurofibromatosis: report of 3 cases. *Cutis*. 2011;87:45-50.
2. Dang JD, Cohen PR. Segmental neurofibromatosis and malignancy. *Skinmed*. 2010;8:156-159.
3. Cohen PR. Idiopathic polydactylous longitudinal erythronychia. *J Clin Aesthet Dermatol*. 2011;4(4):22-28.
4. Cohen PR. Genodermatoses with malignant potential. *Am Fam Physician*. 1992;46:1479-1486.
5. Cohen PR. Images in clinical medicine. neurofibromatosis type I. *N Engl J Med*. 1993;329:1549.
6. Dang JD, Cohen PR. Segmental neurofibromatosis of the distal arm in a man who developed Hodgkin lymphoma. *Int J Dermatol*. 2009;48:1105-1109.
7. Hager CM, Cohen PR, Tschien JA. Segmental neurofibromatosis: case reports and review. *J Am Acad Dermatol*. 1997;37(5, pt 2):864-869.
8. Baran R, Dawber RP, Perrin C, et al. Idiopathic polydactylous longitudinal erythronychia: a newly described entity. *Br J Dermatol*. 2006;155:219-221.
9. Baran R. The red nail—always benign? *Actas Dermasifiliogr*. 2009;100(suppl 1):106-113.
10. Cohen PR. Longitudinal erythronychia: individual or multiple linear red bands of the nail plate: a review of clinical features and associated conditions. *Am J Clin Dermatol*. 2011;12:217-231.