

What you should know about heterotopic pregnancy

↘ With increasing use of ART and a rising incidence of ectopic pregnancy, the phenomenon of coexisting intrauterine and extra-uterine gestations is becoming much less rare

CASE 1

Pelvic pain and few signs of intrauterine pregnancy

A 24-year-old woman, para 1-0-0-1, visits the hospital emergency department complaining of pelvic pain. She says the pain arose suddenly and reports that she had a positive urine pregnancy test earlier in the week. When asked about her obstetric history, she reports vaginal delivery of an 8 lb, 8 oz infant at 38 weeks' gestation 2 years earlier. Her human chorionic gonadotropin (hCG) level is 3,000 mIU/mL, but ultrasonography (US) reveals no evidence of pregnancy. She is discharged with instructions to follow up with her physician in 2 days.

When her abdominal pain worsens, she returns to the emergency department. Physical examination reveals significant tenderness of the abdomen and moderate to severe tenderness of the cervix upon motion. Transvaginal US shows a uterus of normal size with a 5-mm endometrial lining and no gestational sac. The patient's abdomen is full of fluid, with large, hypodense areas adjacent to the uterus bilaterally but larger on the right. The preoperative diagnosis: ruptured ectopic pregnancy.

During the diagnostic laparoscopy that follows, approximately 500 mL of blood is discovered in the abdomen and pelvis, and a gestational sac is found to be densely adherent to the right pelvic sidewall, where the ureter nears the uterine vessels. The sac, which has partially separated from the sidewall, is bleeding.

The surgeon peels the sac off the sidewall and controls bleeding with electrocautery and liquid thrombin. The final pathology report describes the tissue as an organizing blood clot with trophoblasts, consistent with ectopic pregnancy.

IN THIS ARTICLE

Ovarian "cyst" turns out to be a gestation
page 32

When a pregnancy wanders, there are many possibilities for where
page 33

Hold off on curettage
page 34

Daniel M. Avery, MD

Dr. Avery is Associate Professor and Chair, Department of Obstetrics and Gynecology, University of Alabama School of Medicine, Tuscaloosa, Ala.

Marion D. Reed, MD

Dr. Reed is Assistant Professor, Department of Obstetrics and Gynecology, University of Alabama School of Medicine, Tuscaloosa, Ala.

William L. Lenahan, MD

Dr. Lenahan is Adjunct Assistant Professor of Obstetrics and Gynecology, University of Alabama School of Medicine, Tuscaloosa, Ala. He also practices ObGyn in Winfield, Ala.

The authors report no financial relationships relevant to this article.

»» SHARE YOUR EXPERIENCES

Have you diagnosed a heterotopic pregnancy?

E-MAIL obg@dowdenhealth.com
FAX 201-391-2778

At a follow-up visit 3 weeks later, the patient reports persistent symptoms of pregnancy. Repeat US reveals a twin intrauterine pregnancy with two sacs, only one of which has a heartbeat. One week later, US shows confluence of the sacs, with a single viable fetus at 8 weeks and 2 days of gestation.

Could heterotopic pregnancy have been diagnosed earlier?

This case illustrates challenges inherent in the diagnosis of heterotopic pregnancy, which is much more common today than it was when it was first described 300 years ago. Incidence has increased from approximately 1 in 30,000 pregnancies to 1 in 2,600 pregnancies annually. When assisted reproductive technologies (ART) are used, the incidence may be as high as 1 in 100 pregnancies.¹

The rising incidence suggests that the diagnosis of intrauterine pregnancy can no longer be used to exclude the presence of ectopic pregnancy, and vice versa. Instead, steps must be taken to rule out both when a woman exhibits pain and signs of pregnancy.

In this article, we discuss the causes, diagnosis, and treatment of heterotopic pregnancy, including the necessity of a high index of suspicion, the unreliability of US imaging in 50% of cases, and the need to avoid curettage in the treatment of ectopic pregnancy until an empty uterus can be confirmed.

Why is heterotopic pregnancy on the increase?

One reason may be the increase in ectopic pregnancy. Among the factors contributing to the rising incidence of ectopic pregnancy are:

- pelvic adhesive disease
- effects of diethylstilbestrol (DES) on the genital tract
- antibiotic-induced tubal disease
- use of an intrauterine device (IUD)
- voluntary restriction of family size
- iatrogenic curettage of intrauterine

The literature on heterotopic pregnancy is slight

Duverney was the first to report heterotopic pregnancy, in 1708, after finding an intrauterine pregnancy during the autopsy of a woman who had died from a ruptured ectopic pregnancy.¹ It was 165 years, however, before the first review of the phenomenon was written.² By 1970, only 479 such cases had been reported.²⁰

Determining incidence remains a challenge—except that it is rising

In 1948, DeVoe and Pratt calculated the incidence of heterotopic pregnancy by multiplying the incidence of two-ovum pregnancy by the incidence of ectopic pregnancy, reaching an estimate of 1 in 30,000 pregnancies annually.²

In 1965, Rothman and Shapiro found that only about 500 cases of heterotopic pregnancy had been reported cumulatively.⁷ They reasoned that, if the incidence of fraternal twins is 1 in 110 and the incidence of ectopic pregnancy is 1 in 250, heterotopic pregnancy should occur at a rate of 1 in 27,500 gestations.⁷ They also speculated that many heterotopic pregnancies go undiagnosed because of early pregnancy loss.⁷

In 1971, Payne and colleagues hypothesized that ovulation-induction agents increase the incidence of heterotopic pregnancy, and McLain and associates reached a similar conclusion in 1987.⁹ The incidence of multiple pregnancy after oral ovulation induction is 8% to 10%, and it is 20% to 50% with injectable agents.⁹ In 1994, Crabtree and associates reported that both abdominal and heterotopic pregnancies appear to be increasing in incidence.¹⁷

Today, the incidence of heterotopic pregnancy is thought to be about 1 in 2,600 pregnancies annually—primarily because of assisted reproduction.² The calculated risk of heterotopic pregnancy is 1 in 119, and it rises to 1 in 45 with embryo transfer.⁸

pregnancy during surgery for ectopic pregnancy

- pregnancy termination
- history of surgery to treat infertility, ectopic pregnancy, or tubal adhesions
- improvement in the assay used to measure gonadotropin
- improvement in ultrasonography.²⁻⁴

A previous ectopic pregnancy is a risk factor for ectopic pregnancy as well as for heterotopic pregnancy.⁵

Pelvic infection, antibiotic-induced tubal disease, previous ectopic pregnancy, pelvic adhesions, and tubal surgery with cauterization of the tubes and subsequent bowel adhesions distort the fallopian tubes and may render them unable to propel a

TABLE Signs and symptoms of heterotopic pregnancy

Pain after spontaneous or induced abortion
Two corpora lutea detected during ultrasonography or laparotomy
Persistent Hegar's sign or Chadwick's sign after laparotomy for ectopic pregnancy
Absence of vaginal bleeding after laparotomy for ectopic pregnancy
Lateral location of a gestational sac identified via ultrasonography
Fluid in the uterus
Discordant appearance of fetal cardiac activity
Unpredictable quantitative human chorionic gonadotropin levels

migrated embryo into the uterine cavity.^{2,6} Ectopic pregnancy may result from internal migration of a fertilized ovum or transperitoneal migration of sperm.⁷

DES exposure can distort the uterine cavity.⁸ Congenital and acquired uterine malformations increase the risk of ectopic pregnancy.³

In addition, ovulation-inducing drugs and ovarian stimulation increase the number of eggs available for conception, with a greater risk of multiple gestation and heterotopic pregnancy.^{3,9,10}

The greatest increase in heterotopic pregnancy has been seen with ART involving the transfer of multiple embryos into the uterus, as well as gamete intrafallopian transfer, also known as GIFT.^{10,11} When five or more embryos are transferred, the risk of heterotopic pregnancy increases to 1 in 45 pregnancies annually.¹¹ Inadvertent placement of the catheter tip near the tube, excessive force or volume during transfer, and retrograde migration of an embryo because of uterine contraction may also increase the risk of heterotopic pregnancy.⁸

A heterotopic pregnancy in spontaneous conceptual cycles without ART is relatively rare, even in a woman who has risk factors for ectopic pregnancy.¹²

How does heterotopic pregnancy develop?

Possibilities include the following, according to Wolf and colleagues:

- fertilization of two ova from a single coitus
- superimposition of an intrauterine pregnancy over an existing ectopic pregnancy (also known as superfetation).¹³

The appearance of cardiac activity may be discordant in heterotopic pregnancy, according to Hirsh and associates, suggesting that superfetation is indeed a mechanism in its development, with one pregnancy conceived earlier than the other.¹⁴

Diagnosis requires a high index of suspicion

The timely detection of heterotopic pregnancy necessitates vigilance.^{10,15} The **TABLE** lists signs and symptoms of this condition, which include abdominal pain, an adnexal mass, peritoneal irritation, an enlarged uterus, and absence of vaginal bleeding.⁶ In contrast to ectopic pregnancy, there is no vaginal bleeding with heterotopic pregnancy because an intact intrauterine pregnancy is present.⁸

CASE 2

Ovarian “cyst” turns out to be a gestation

A 28-year-old woman, para 2-0-0-2, visits the emergency department complaining of acute abdominal pain, and is given two diagnoses: urinary tract infection and incomplete abortion at 5 weeks' gestation. She is treated for the infection and discharged, to be followed up with treatment by her private ObGyn for the incomplete abortion.

Three days later she returns, reporting cramping and increased pain. Ultrasonography reveals intrauterine fetal demise at 8 weeks and 6 days of gestation, along with a hemorrhagic mass in the cul-de-sac—most likely a ruptured hemorrhagic ovarian cyst. Her history includes two cesarean deliveries and treatment with clonidine for hypertension. Her blood pressure is normal, and her abdomen is diffusely tender, with bowel sounds present. The preoperative



The greatest increase in the incidence of heterotopic pregnancy has been seen with GIFT and ART involving multiple embryos

diagnosis: incomplete abortion and a ruptured hemorrhagic cyst.

During exploratory laparotomy, left salpingo-oophorectomy is performed, and a hemorrhagic ovarian cyst is removed, with evacuation of hemoperitoneum, followed by suction curettage. Almost no tissue is present in the uterine cavity at the time of surgery. The final pathology report determines that the hemorrhagic cyst contained organizing clotted blood with trophoblasts, consistent with ectopic pregnancy. In addition, the uterine contents included scant tissue with hypersecretory endometrium. The physician theorizes that the collapsed gestational sac may have passed out of the patient's uterus after US or during preoperative preparation.

The patient does well postoperatively and is discharged home.

Should ectopic pregnancy have been suspected earlier?

When a patient experiences pain after spontaneous or induced abortion, ectopic pregnancy should be suspected.² In addition, women who exhibit signs or symptoms of ectopic pregnancy or continuing pregnancy after an inconclusive or negative US should be assessed thoroughly to exclude ectopic pregnancy.⁵

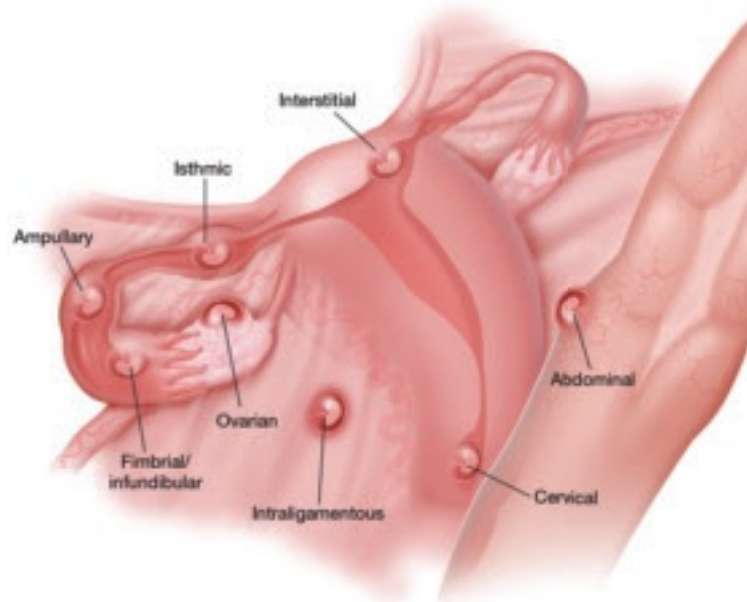
Conversely, if symptoms of pregnancy persist or worsen after laparotomy for ectopic pregnancy, the surgeon should suspect another pregnancy.⁷ Even when a patient who is being treated for infertility exhibits signs and symptoms of ectopic pregnancy, concurrent intrauterine pregnancy must be ruled out.⁹

A persistent Hegar's sign or Chadwick's sign means that a pregnancy is still present.⁷ In addition, the absence of vaginal bleeding after surgery for ectopic pregnancy may indicate the presence of gestation.⁶

Few heterotopic pregnancies are identified before surgery

Only 10% of heterotopic pregnancies are detected preoperatively.³ One third of intrauterine gestations in a heterotopic pregnancy spontaneously abort.¹¹

FIGURE When a pregnancy wanders, there are many possibilities for where



Ectopic pregnancy can arise as a result of internal migration of a fertilized ovum or transperitoneal migration of sperm. It may be observed at a number of possible sites within the pelvis.

ROB FLEWELL FOR OBG MANAGEMENT

Don't assume that the presence of an intrauterine gestation excludes the possibility of ectopic pregnancy when the patient experiences abdominal pain.¹⁶

Imaging is helpful but not foolproof

Identifying a heterotopic pregnancy before surgery is an imaging challenge. Even when US is employed, the diagnosis is missed in 50% of cases—and even transvaginal US has low sensitivity.^{17,18} One reason may be the discordant appearance of fetal cardiac activity in coexisting intrauterine and ectopic pregnancies. Alternatively, the gestational sac may be anembryonic.¹⁹

A gestational sac is a sonolucent structure with a double decidual sac sign—i.e., an echogenic ring surrounding the sac. A pseudogestational sac containing fluid or blood can mimic a gestational sac.⁵ One helpful diagnostic sign of heterotopic pregnancy during US examination is a lateral location of one of the gestational sacs.¹⁶

CONTINUED ON PAGE 34

If two corpora lutea are present on US—or even at laparotomy or laparoscopy—suspect heterotopic pregnancy.⁷

Obstetric imaging should include views of the adnexae


The adnexa and surrounding structures are usually not imaged during obstetric US because the focus is on the intrauterine gestation.⁵ In addition, ultrasonographers are frequently misled by the presence of fluid in the uterus.

It is important for the ultrasonographer to examine the entire pelvic region for pregnancy (FIGURE, page 33), especially in women who have been treated with ART or who have pelvic inflammatory disease or a history of pelvic surgery.¹¹ The adnexae should be assessed during every obstetric US, especially in women who are at risk of ectopic pregnancy.⁵

Serial beta-hCG levels aren't helpful

In heterotopic pregnancy, both gestations produce hCG, so the assessment of serial serum quantitative beta-hCG levels is not informative.¹¹

When treating ectopic pregnancy, hold off on curettage

Ectopic pregnancy and extrauterine gestation are life-threatening emergencies that require timely diagnosis and treatment.^{5,19} The traditional treatment for ectopic pregnancy is laparotomy or laparoscopy with removal of the ectopic pregnancy, followed by dilation and curettage (D&C). The curettage removes the decidual cast and clots and is intended to prevent postoperative bleeding. However, curettage could destroy any intrauterine pregnancy that is not yet diagnosed. Therefore, D&C should be withheld until the uterus is confirmed to be empty.¹⁰ 

References

- Childs AJ, Royek AB, Leigh TB, Gallup PG. Triplet heterotopic pregnancy after gonadotropin stimulation and intrauterine insemination diagnosed at laparoscopy: a case report. *South Med J*. 2005;98:833–835.
- Richards SR, Stempel LE, Carlton BD. Heterotopic pregnancy: reappraisal of incidence. *Am J Obstet Gynecol*. 1982;142:928–930.
- Laband SJ, Cherny WB, Finberg HJ. Heterotopic pregnancy: report of four cases. *Am J Obstet Gynecol*. 1988;158:437–438.
- Snyder T, delCastillo J, Graff J, Hoxsey R, Hefti M. Heterotopic pregnancy after in vitro fertilization and ovulatory drugs. *Ann Emerg Med*. 1988;17:846–849.
- DeFrancesch F, DiLeo L, Martinez J. Heterotopic pregnancy: discovery of ectopic pregnancy after elective abortion. *South Med J*. 1999;92:330–332.
- Rizk B, Tan SL, Morcos S, et al. Heterotopic pregnancies after in vitro fertilization and embryo transfer. *Am J Obstet Gynecol*. 1991;164(1 Pt 1):161–164.
- Rothman A, Shapiro J. Heterotopic pregnancy after homolateral salpingo-oophorectomy. Report of a case. *Obstet Gynecol*. 1965;26:718–720.
- Sherer DM, Scibetta JJ, Sanko SR. Heterotopic quadruplet gestation with laparoscopic resection of ruptured interstitial pregnancy and subsequent successful outcome of triplets. *Am J Obstet Gynecol*. 1995;172(1 Pt 1):216–217.
- Payne S, Duge J, Bradbury W. Ectopic pregnancy concomitant with twin intrauterine pregnancy. A case report. *Obstet Gynecol*. 1971;38:905–906.
- Gamberdella FR, Marrs RP. Heterotopic pregnancy associated with assisted reproductive technology. *Am J Obstet Gynecol*. 1989;160:1520–1524.
- Beyer DA, Dumesic DA. Heterotopic pregnancy: an emerging diagnostic challenge. *OBG Management*. 2002;14(10):36–46.
- Somers MP, Spears M, Maynard AS, Syverud SA. Ruptured heterotopic pregnancy presenting with relative bradycardia in a woman not receiving reproductive assistance. *Ann Emerg Med*. 2004;43:382–385.
- Wolf GC, Kritzer L, DeBold C. Heterotopic pregnancy: midtrimester management. *Obstet Gynecol*. 1979;54:756–758.
- Hirsch E, Cohen L, Hecht BR. Heterotopic pregnancy with discordant ultrasonic appearance of fetal cardiac activity. *Obstet Gynecol*. 1992;79(5 Pt 2):824–825.
- McLain PL, Kirkwood CR. Ovarian and intrauterine heterotopic pregnancy following clomiphene ovulation induction: report of a healthy live birth. *J Fam Pract*. 1987;24:76–79.
- Luckas MJM, Fishwick K, Martin-Hierro K, Shaw GC, Walkinshaw SA. Survival of intrauterine twins and an interstitial singleton fetus from a heterotopic in vitro fertilisation-embryo transfer pregnancy. *Br J Obstet Gynaecol*. 1997;104:751–752.
- Crabtree KE, Collet B, Kilpatrick SJ. Puerperal presentation of a living abdominal pregnancy. *Obstet Gynecol*. 1994;84(4 Pt 2):646–648.
- Cheng PJ, Chueh HY, Qiu JT. Heterotopic pregnancy in a natural conception cycle presenting as hematometra. *Obstet Gynecol*. 2004;104(5 Pt 2):1195–1198.
- Fa EM, Gerscovich EO. High resolution ultrasound in the diagnosis of heterotopic pregnancy: combined transabdominal and transvaginal approach. *Br J Obstet Gynaecol*. 1993;100:871–872.
- Smith DJ, Siddique FH. A case of heterotopic pregnancy. *Am J Obstet Gynecol*. 1970;108:1289–1290.



When treating ectopic pregnancy, postpone D&C until you've confirmed that the uterus is empty