

SECOND OF TWO PARTS

ENT complaints in pregnancy. Part 2: The ear and the throat

📌 Did you know that laryngopharyngeal reflux is distinct from GERD—and becomes worse during pregnancy? That the thyroid enlarges in half of gravidas? That some pregnant women experience changes to their voice?

Etai Funk, MD, and Alexander Gelbard, MD

Ear, nose, and throat complaints are common even before you superimpose the transformations and demands of pregnancy. Take gastroesophageal reflux disease (GERD), for example. Experts estimate that one third of the US population suffers from this condition.¹ In pregnancy, endocrine and anatomic factors converge to exacerbate acid reflux disorders in 30% to 50% of women.²

Other complaints, too, surface or worsen during gestation. In Part 1 of this series (August 2010, also available at obgmanagement.com), we discussed sinonasal disease in pregnancy: specifically, pregnancy rhinitis, allergic rhinitis, vasomotor rhinitis, rhinitis medicamentosa, sinusitis, epistaxis, and sleep-disordered breathing. In Part 2, our focus is:

- laryngologic complaints
 - GERD
 - laryngopharyngeal reflux
 - laryngopathia gravidarum
- otologic disorders
 - eustachian tube dysfunction
 - facial paralysis (Bell's palsy)
 - otosclerosis
 - sudden sensorineural hearing loss
- endocrine abnormalities
 - thyroid nodules
- dermatologic complaints
 - melasma
 - pyogenic granuloma.

Why does GERD increase in pregnancy?

The smooth muscle-relaxing effects of progesterone and estrogen are likely responsible for the decreased tone of both the upper esophageal and gastroesophageal sphincters. This reduced tone may lead to increased reflux of stomach contents into the esophagus, larynx, and pharynx. Decreased gastric emptying and increased intestinal transit time may also play a role. Reflux of gastric contents may also be exacerbated by compression from the gravid uterus.

Gastroesophageal reflux is physiologic, occurring in healthy people as often as 50 times

IN THIS ARTICLE

Mapping disease in the head and neck
page 29

When Bell's palsy strikes in pregnancy
page 30

Could that thyroid nodule be cancer?
page 32

Dr. Funk is a Facial Plastic Surgeon at the Bressler Center in Houston, Texas.

Dr. Gelbard is a Fifth-Year Resident in the Bobby R. Alford Department of Otolaryngology–Head and Neck Surgery at the Baylor College of Medicine in Houston, Texas.

The authors report no affiliation or financial arrangement relevant to this article.

» **SHARE YOUR EXPERIENCE!**
How do you manage GERD in pregnancy?

E-MAIL obg@qhc.com | FAX 973-206-9251

a day. It becomes GERD when reflux into the esophagus is excessive, causing tissue damage (esophagitis) and clinical symptoms (heartburn). Recent studies suggest that, in addition to the traditional symptoms, **GERD is associated with increased severity of nausea and vomiting in pregnancy.**³

Ultimately, refluxed gastric contents cause mucosal injury to the upper aerodigestive tract. The location of injury and subsequent clinical manifestations are believed to correspond to the pattern of reflux.⁴

Some refluxers do it in the daytime

Laryngopharyngeal reflux (LPR), widely viewed as a separate clinical entity from GERD, is backflow of stomach contents into the laryngopharynx (**FIGURE**).⁵ Fewer than 40% of patients who have LPR experience heartburn, and fewer than 25% have evidence of esophagitis.⁶ LPR patients are predominantly upright, daytime refluxers, whereas GERD patients are predominantly supine or nocturnal refluxers. The threshold for reflux-related injury of the laryngeal epithelium is significantly lower than the threshold for injury to epithelium of the esophagus.⁷ As a result, even brief reflux exposures can injure the laryngeal epithelium.⁸

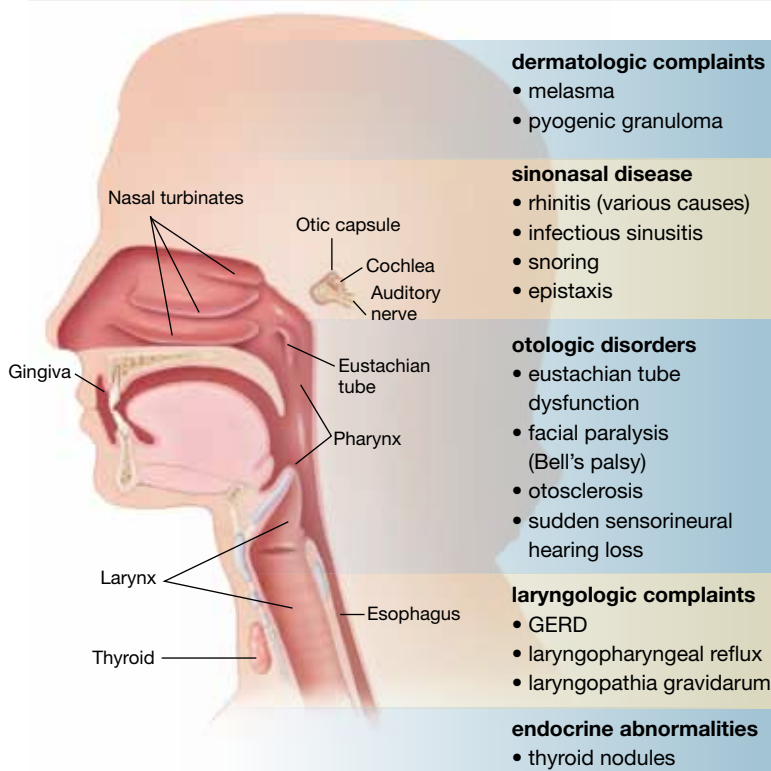
Injury in LPR manifests clinically as posterior laryngeal edema and erythema, obliteration of the laryngeal ventricles, and interarytenoid hypertrophy.⁵ These changes produce symptoms of chronic throat clearing, hoarseness, cough, and the sensation that something is caught in the throat (globus sensation). History and physical examination are typically sufficient to diagnose LPR.

Lifestyle changes can make a difference in GERD and LPR

Start with simple measures. Advise the patient to elevate the head of her bed 6 to 8 inches. Our patients report that it is usually easier to tolerate books under the legs of the head end of the bed than it is to sleep with extra pillows, especially when a side position is desired.

The patient also should be advised to avoid lying down within 3 hours after eating and to avoid smoking tobacco; drinking beer, wine,

Mapping the head and neck, and the spectrum of disease there in pregnancy



This list includes diseases and problems reviewed in the first part of this article, August 2010.

coffee, soda, caffeinated tea, and citrus juice; eating foods that are fried, high in fat, or spicy; and using drugs that promote reflux (i.e., calcium channel blockers, sedatives, and nitrates).

An interesting tip: Chewing gum increases salivary bicarbonate production and may neutralize acid.⁹

Pharmacologic options include H2 blockers and PPIs

Antacids, such as sucralfate, neutralize acid already in the stomach and may have a role in the treatment of acute symptoms.

Histamine 2 (H2) blockers such as cimetidine (Tagamet), ranitidine (Zantac), and famotidine (Pepcid) block the histamine receptor in the stomach and reduce acid secretion by as much as 50%. These medications are typically taken two to three times daily. They all fall into Pregnancy Category B, except

Doctor, will I ever sing again?

The human voice is extremely sensitive to the endocrinologic changes of pregnancy. Many of these changes manifest as alterations in fluid content of the lamina propria just beneath the laryngeal mucosa.²⁷ Collectively, the voice changes of pregnancy are known as laryngopathia gravidarum. Abdominal distension during pregnancy also interferes with abdominal muscle function, altering the mechanics of phonation and creating over-use injuries.

Symptoms include hoarseness and voice loss. Singers, in particular, notice a deeper voice and a diminished range of pitch.²⁸ Treatment is largely supportive, with hydration, and singers should be advised to refrain from singing until abdominal muscle function resolves.

Laryngopathia gravidarum typically resolves postpartum as endocrinologic alterations return to baseline and abdominal support returns.

for nizatidine (Axid), which is Category C.

Proton pump inhibitors (PPIs). Recently, utilization of H₂ blockers has given way to the newer class of PPIs, including lansoprazole (Prevacid), pantoprazole (Protonix), and esomeprazole (Nexium). These drugs target the parietal cell hydrogen potassium ATPase, reducing acid secretion by 80% to 90%. Treatment is typically once daily for uncomplicated GERD and twice daily for LPR. Patients who have LPR also require higher dosages to achieve complete acid suppression and heal the delicate laryngeal tissue. Tissue injury in LPR may take 6 months to reverse once adequate therapy has been initiated. Severe, complicated cases may require the addition of an H₂ blocker or even a third daily dose of the PPI.

Patients should not discontinue a PPI abruptly because of the risk of rebound hypersecretion of gastric acid. Rather, these drugs should be stopped gradually over several weeks. They are best taken 30 minutes before a meal, as that is when they reach maximum blood concentration.

PPIs are generally considered safe for use after the first trimester of pregnancy. All are Category B drugs, except for omeprazole (Prilosec), which is a Category C drug.

Eustachian tube dysfunction usually resolves postpartum

This disorder affects between 5% and 30% of

pregnant women. Symptoms usually begin after the first trimester and consist of tubal obstruction or patulous Eustachian tubes. Women who have tubal obstruction report a clogged or popping sensation in their ears, with muffling of sounds. In severe cases, serous effusion may develop.

Tubal obstruction is related to edema of the respiratory mucosa. In cases in which symptoms are more distressing to the patient, increased humidity, treatment of rhinitis, and frequent Valsalva maneuvers have had variable success in providing relief. For recalcitrant cases, pressure-equalization tubes can be placed (in an otolaryngology clinic).

Women who have patulous tubes usually report intermittent symptoms that consist of autophony and a roaring sensation in their ears that is synchronous with breathing and is worse when they are in an upright position or exercising (or both). The cause of patulous Eustachian tubes is not well defined. Weight loss and hormonal variables are believed to play a role.

This condition typically resolves postpartum.

Treatment is largely supportive, including humidification, reassurance, and instructions on how to perform a forceful inspiratory nasal sniff.

Incidence of Bell's palsy in pregnancy is uncertain

A possible association between pregnancy and idiopathic facial paralysis (Bell's palsy) was first noted by Sir Charles Bell in 1830. Retrospective literature at first suggested a 3.3-fold increased risk of Bell's palsy during pregnancy, with the incidence peaking during the third trimester of gestation.¹⁰ Subsequent re-analysis found no significant difference in the incidence of Bell's palsy between pregnant and nonpregnant women of childbearing age.¹¹ Prospective studies are sorely needed to definitively establish the incidence of Bell's palsy in pregnancy.

Bell's palsy typically appears during the third trimester

A unique aspect of Bell's palsy in pregnancy



Advise the patient not to discontinue a PPI abruptly because of the risk of rebound hypersecretion of gastric acid

Thyroid nodules are common in pregnancy; malignancy is a distinct possibility

Diffuse thyroid gland enlargement during pregnancy is common, occurring to varying degrees in nearly 50% of pregnant women. Pregnancy is also thought to promote the growth of existing thyroid nodules and induce the formation of new nodules.²⁹ In both pregnant and nonpregnant patients, the majority (more than 90%) of these nodules are benign, although pregnant women appear to have a slightly higher likelihood that a solitary nodule is malignant.³⁰

Diagnosis is straightforward

When a thyroid nodule is detected in a pregnant patient, the workup begins with a thorough history, noting age, family history of thyroid or endocrine disease, personal history of low-dosage head and neck radiation, and any recent hoarseness, dysphagia, and symptoms of hypermetabolism.

The physical exam should focus on the size and location of the thyroid abnormality, the degree of firmness of the nodule, the presence of any other nodules in the thyroid, any palpable cervical lymph nodes, and any vocal cord dysfunction.

US imaging is recommended

Because ultrasonography (US) of the thyroid is noninvasive, it is the initial imaging modality of choice. It can establish the size of any nodule (and serve as an objective baseline measurement) and identify any characteristics that suggest malignancy, such as microcalcifications, hypoechogenicity, and solid structure.

Consider fine-needle aspiration (FNA)

This technique, guided by US, is recommended when a nodule is discovered during the first trimester. However, when a nodule is discovered after 20 weeks' gestation, the FNA option is not required. FNA can be deferred until after delivery because, even with a histologically confirmed, well-differentiated thyroid cancer, we would not operate during the third trimester—the elevated risk of preterm labor precludes that option.

When the diagnosis is cancer

The nonpregnant patient has several therapeutic options for management of thyroid cancer, but pregnancy restricts these options to close observation and surgical resection. The optimal timing of surgical management (either the second trimester or postpartum) remains unresolved.

Thyroid cancer is somewhat unique among malignancies. The majority of cancers are well-differentiated and exhibit indolent tumor biology. In one prospective study

of nonpregnant patients who had small, papillary, thyroid cancers, more than 70% of those who bypassed surgical intervention had no tumor growth after 5 years of follow-up.³¹

Given that pregnancy is an independent risk factor for surgical complications, prolonged hospitalization, and higher hospital costs after thyroidectomy, it seems reasonable to carefully monitor, by serial US, pregnant women who have been given a diagnosis of small, well-differentiated thyroid cancer.³²

In general, if a nodule is discovered during the first trimester and is larger than 1.5 cm, and if the diagnosis is cytology-proven, differentiated thyroid cancer, we would consider surgery during the second trimester if the patient were adamant. Other authors recommend second-trimester surgery more strongly.³³ Regardless of the timing of resection, adjunctive treatment with radioactive iodine ablation (RIA) 3 to 6 months after delivery is an accepted component of complete oncologic therapy. Breastfeeding is prohibited with RIA, and patients are advised to wait 1 year after RIA before conceiving again.

If the patient chooses to undergo surgical resection of the thyroid during the second trimester, be aware of the transient hypothyroid state that immediately follows surgery (before the patient becomes euthyroid on replacement hormone). Because the fetus begins to synthesize its own thyroid hormone around the 18th week of gestation, we agree with the contention that the optimal time to operate is between week 19 and week 22 of gestation.³⁴ Operating before 24 weeks also reduces the concerns related to fetal viability.

If a nodule is cytology-proven to be differentiated thyroid cancer and is smaller than 1.5 cm or is discovered late in the second trimester or beyond, most authors recommend delaying surgery until after delivery.

Outcomes are not worse in pregnancy

Pregnant women who have well-differentiated thyroid cancer and their nonpregnant counterparts have statistically identical outcomes. Moosa and Mazzaferri demonstrated no significant differences in the rate of recurrence, distant spread, or mortality.³⁵ Their findings have been replicated in a larger, population-based study.³⁶ There also appears to be no significant differences in maternal survival or fetal outcome between women who undergo surgical intervention during the second trimester and those who delay surgery to the postpartum period.^{35,37,38} After treatment, the risk of recurrence does not increase in subsequent pregnancies.³⁵

is its tendency to manifest during the third trimester and postpartum. The most widely accepted theory for this phenomenon is the reactivation of latent herpes simplex virus within the geniculate ganglion.¹² A large body of scientific work supports this theory.

The maternal immune system undergoes complex alterations during pregnancy, although the mechanisms for these changes are not completely understood. The most pronounced change is a shift from cell-mediated immune responses toward humoral and innate immune responses as pregnancy progresses.¹³ Such a shift likely reduces the maternal cytotoxic potential against fetal antigens.¹⁴ Clinically, the decrease in cellular immunity manifests as an increased susceptibility to intracellular pathogens such as herpes simplex virus later in pregnancy.¹⁵

Sudden facial weakness is the usual presenting symptom

This weakness develops over 24 to 48 hours, progressing to complete or near-complete paralysis within 1 week. Associated symptoms often include pain, fever, dry eye, a change in taste and salivation, and sensitivity to noise.¹¹

Diagnosis of Bell's palsy requires the exclusion of other causes, accomplished primarily by taking a thorough history and performing a physical examination. Between 14% and 21% of pregnant patients who have acute facial paralysis have causes other than Bell's palsy.¹⁶

Among the other causes of facial paralysis are herpes zoster oticus (Ramsay Hunt syndrome), in which varicella zoster virus reactivates at the geniculate ganglion.¹⁰ The patient with this disorder experiences facial nerve paralysis, skin eruption in the auricular canal, and cochleovestibular symptoms. Ramsay Hunt syndrome generally has a worse prognosis than Bell's palsy for return of facial function.

Recurrent facial nerve paralysis can also be seen in Lyme disease, and prolonged paralysis may occur in Guillain-Barré syndrome.

When facial paralysis is accompanied by ear pain and purulent otorrhea, the cause

may be acute otitis media. Cholesteatoma, trauma, neoplasm, myasthenia gravis, arteriovenous malformation, and mumps can all produce facial paralysis.

Treatment in pregnancy resembles treatment in the general population

Topical eye care, oral corticosteroids, and antiviral medications are the standard of care for Bell's palsy. Surgical decompression may be utilized in the nonpregnant population, but reports of facial nerve decompression during pregnancy are extremely rare.

Eye care involves the use of preservative-free artificial tears, a viscous ocular ointment (Lacri-Lube) that must be applied at bedtime, with taping of the eyelids (shut) indicated at night for severe paralysis. Eye care plays a critical role in the prevention of ocular complications such as corneal abrasion.

Steroid treatment (i.e., prednisone at a dosage of 1 mg/kg for 5 days, followed by tapering) improves recovery in Bell's palsy when it is initiated within 14 days after the onset of facial paralysis.¹⁷ However, use of steroids during the first trimester of pregnancy has been associated with an increased risk of cleft palate, and infants born to mothers who received exogenous steroids during gestation should be watched for adrenal hypofunction.

Antiviral medications represent another adjunctive treatment for Bell's palsy. Nucleoside analogues, including valacyclovir (Valtrex) and famciclovir (Famvir) (both Category B), pose little risk to mother and fetus. In fact, these agents are commonly used to prevent outbreaks of herpes simplex virus late in pregnancy. Two double-blind, randomized, controlled trials in nonpregnant patients have demonstrated improved outcomes when Bell's palsy is treated with steroids and antiviral agents within 3 days after onset of the paralysis, compared with steroids alone.^{18,19}

Rapid diagnosis and treatment are critical for a good outcome. The potential benefits of treatment likely outweigh the limited fetal risks posed by these medications. Although there are conflicting reports, in general, pregnant patients who experience incomplete



It is important to initiate steroid treatment within 14 days after the onset of facial paralysis (Bell's palsy) to improve recovery

CONTINUED ON PAGE 39

paralysis do extremely well, recovering with minimal residual deficits. The prognosis is less optimistic for patients who have complete paralysis, with persistent deficits observed in as many as 50% of cases.

Otosclerosis may lead to hearing loss

The primary disease of the otic capsule, otosclerosis is characterized by alternating phases of absorption of compact bony tissue and replacement with spongy bone. The most common location of this disorder is the oval window, and it can lead to stapedial ankylosis and subsequent conductive hearing loss. The disease can eventually progress to cochlear otosclerosis with sensorineural hearing loss.

Otosclerosis is multifactorial in origin, with contributors that include genetics, fluoridated water, exposure to measles, and vitamin D deficiency.

Pregnancy probably does not accelerate otosclerosis

Early reports, based on subjective, self-reported hearing endpoints, suggested that pregnancy might cause or accelerate the process of otosclerosis.²⁰ In the 1950s, some authors even advocated termination of pregnancy and sterilization as treatment in progressive cases.²¹ The likely source of this idea was a paper written by Greifenstein in 1939, which stated the official policy of the German Reichsgutachterstelle (Agency of Expert Opinion of the German Reich) in regard to abortion and sterilization in women who had genetic disease.²² As a result of this guideline, in 1939, of 69 women who had otosclerosis in Germany, 43 underwent abortion and 23 were sterilized.²³

Recent research argues strongly against an association between pregnancy and accelerated otosclerosis. Rigorous audiometry found no adverse effect on hearing in otosclerotic women who had children, compared with women without children. Nor were air conduction, bone conduction, and discrimination worse in women who had

children, compared with childless women. No significant correlation was found between the number of children and hearing loss, or between lactation and hearing loss.²⁴

Treatment of otosclerosis entails amplification throughout the pregnancy. Postpartum, an elective stapedectomy, in which the sclerotic stapes bone is replaced with a micro-prosthesis, frequently provides a clinically significant increase in hearing.

Sudden sensorineural hearing loss is rare

Although it is uncommon during pregnancy, sudden sensorineural hearing loss has been associated with hypertension and toxemia of pregnancy, presumably due to microemboli-mediated vascular occlusion of the microcirculation of the cochlea and auditory nerve. Complete otologic and audiologic evaluation, as well as treatment of the toxemia, is the standard of care.

Melasma affects almost 75% of gravidas

The “mask of pregnancy” is one of the most frequently encountered changes of pregnancy. The condition is thought to be driven by sun exposure and concomitant increases in the levels of melanocyte-stimulating hormone, serum estrogen, and progesterone. Well-delineated areas of hypermelanosis affect the face and neck. These lesions can begin during pregnancy, or become worse if they were present before conception. The most frequently involved sites are the cheeks, nose, and chin.

Avoidance of sunlight is the treatment for melasma


Topical sunscreens are recommended. Melasma typically regresses after delivery but persists in fewer than 10% of cases. Persistent hyperpigmentation can be treated with a variety of topical agents, including hydroquinone, tretinoin, kojic acid, and vitamin C, among others.²⁵ Treatment is not always effective, however. Extensive pigmentary



Sudden sensorineural hearing loss has been associated with hypertension and toxemia of pregnancy

changes predict a poor response to topical therapy.

Pyogenic granuloma usually regresses postpartum

Granuloma gravidarum, or pyogenic granuloma of pregnancy, consists of soft, pedunculated, vascular proliferations, most commonly arising from the gingiva and nasal mucosa in 2% of pregnant women.²⁵ These proliferations are thought to be triggered by the myriad hormonal changes of pregnancy superimposed on local tissue trauma. These lesions rarely exceed 2 cm in size, but they can ulcerate and cause pain. They frequently regress 1 to 2 months postpartum. Surgical resection is utilized only to stanch recalcitrant bleeding. When lesions recur after surgical excision, inadequate resection is thought to be the cause. A recent report described the Nd:YAG laser as an effective tool for treatment of these lesions.²⁶ 

References

- American Gastroenterological Association. The burden of chronic gastrointestinal diseases study. Bethesda, Md: AGA; 2001.
- Cappell MS, Garcia A. Gastric and duodenal ulcers during pregnancy. *Gastroenterol Clin North Am*. 1998;27(1):169-195.
- Gill SK, Maltepe C, Koren G. The effect of heartburn and acid reflux on the severity of nausea and vomiting of pregnancy. *Can J Gastroenterol*. 2009;23(4):270-272.
- Wiener GJ, Koufman JA, Wu WC, Cooper JB, Richter JE, Castell DO. Chronic hoarseness secondary to gastroesophageal reflux disease: documentation with 24-h ambulatory pH monitoring. *Am J Gastroenterol*. 1989;84(12):1503-1508.
- Gupta R, Sataloff RT. Laryngopharyngeal reflux: current concepts and questions. *Curr Opin Otolaryngol Head Neck Surg*. 2009;17(3):143-148.
- Koufman JA, Belafsky PC, Bach KK, Daniel E, Postma GN. Prevalence of esophagitis in patients with pH-documented laryngopharyngeal reflux. *Laryngoscope*. 2002;112(9):1606-1609.
- Johnston N, Bulmer D, Gill GA, Panetti M, et al. Cell biology of laryngeal epithelial defenses in health and disease: further studies. *Ann Otol Rhinol Laryngol*. 2003;112(6):481-491.
- Gill GA, Johnston N, Buda A, et al. Laryngeal epithelial defenses against laryngopharyngeal reflux: investigations of E-cadherin, carbonic anhydrase isoenzyme III, and pepsin. *Ann Otol Rhinol Laryngol*. 2005;114(12):913-921.
- Smoak BR, Koufman JA. Effects of gum chewing on pharyngeal and esophageal pH. *Ann Otol Rhinol Laryngol*. 2001;110(12):1117-1119.
- Hilsinger RL Jr, Adour KK, Doty HE. Idiopathic facial paralysis, pregnancy, and the menstrual cycle. *Ann Otol Rhinol Laryngol*. 1975;84(4 Pt 1):433-442.
- Vrabec JT, Isaacson B, Van Hook JW. Bell's palsy and pregnancy. *Otolaryngol Head Neck Surg*. 2007;137(6):858-861.
- Murakami S, Mizobuchi M, Nakashiro Y, Doi T, Hato N, Yanagihara N. Bell palsy and herpes simplex virus: identification of viral DNA in endoneurial fluid and muscle. *Ann Intern Med*. 1996;124(1 Pt 1):27-30.

- Sacks G, Sargent I, Redman C. An innate view of human pregnancy. *Immunol Today*. 1999;20(3):114-118.
- Wegmann TG, Lin H, Guilbert L, Mosmann TR. Bidirectional cytokine interactions in the maternal-fetal relationship: is successful pregnancy a TH2 phenomenon? *Immunol Today*. 1993;14(7):353-356.
- Stirrat GM. Pregnancy and immunity. *BMJ*. 1994;308(6941):1385-1386.
- Gillman GS, Schaitkin BM, May M, Klein SR. Bell's palsy in pregnancy: a study of recovery outcomes. *Otolaryngol Head Neck Surg*. 2002;126(1):26-30.
- Ramsey MJ, DerSimonian R, Holtel MR, Burgess LP. Corticosteroid treatment for idiopathic facial nerve paralysis: a meta-analysis. *Laryngoscope*. 2000;110(3 Pt 1):335-341.
- Adour KK, Ruboyianes JM, Von Doersten PG, et al. Bell's palsy treatment with acyclovir and prednisone compared with prednisone alone: a double-blind, randomized, controlled trial. *Ann Otol Rhinol Laryngol*. 1996;105(5):371-378.
- Hato N, Yamada H, Kohno H, et al. Valacyclovir and prednisolone treatment for Bell's palsy: a multicenter, randomized, placebo-controlled study. *Otol Neurotol*. 2007;28(3):408-413.
- Gristwood RE, Venables WN. Pregnancy and otosclerosis. *Clin Otolaryngol Allied Sci*. 1983;8(3):205-210.
- Pearson E. The effect of pregnancy on otosclerosis. *Ann West Med Surg*. 1951;5(5):477-482.
- Greifenstein. Schwangerschaftsunterbrechung und unfruchtbarmachung aus gesundheitlichen Gründen bei Otosklerose. *Zeitschrift für Hals-, Nasen- und Ohrenheilkunde*. 1939;46:344-362.
- Markou K, Goudakos J. An overview of the etiology of otosclerosis. *Eur Arch Otorhinolaryngol*. 2009;266(1):25-35.
- Lippy WH, Berenholz LP, Schuring AG, et al. Does pregnancy affect otosclerosis? *Laryngoscope*. 2005;115(10):1833-1836.
- Muallem MM, Rubeiz NG. Physiological and biological skin changes in pregnancy. *Clin Dermatol*. 2006;24(2):80-83.
- Powell JL, Bailey CL, Coopland AT, Otis CN, Frank JL, Meyer I. Nd:YAG laser excision of a giant gingival pyogenic granuloma of pregnancy. *Lasers Surg Med*. 1994;14(2):178-183.
- Brodnitz FS. Hormones and the human voice. *Bull NY Acad Med*. 1971;47(2):183-191.
- Sataloff RT, Hoover CA. Endocrine dysfunction. In: Sataloff RT, ed. *Professional voice: the science and art of clinical care*. 2nd ed. San Diego, CA: Singular Publishing Group, Inc.; 1997:293-295.
- Kung AW, Chau MT, Lao TT, Tam SC, Low LC. The effect of pregnancy on thyroid nodule formation. *J Clin Endocrinol Metab*. 2002;87(3):1010-1014.
- Smith LH, Danielsen B, Allen ME, Cress R. Cancer associated with obstetric delivery: results of linkage with the California cancer registry. *Am J Obstet Gynecol*. 2003;189(4):1128-1135.
- Ito Y, Urano T, Nakano K, et al. An observation trial without surgical treatment in patients with papillary microcarcinoma of the thyroid. *Thyroid*. 2003;13(4):381-387.
- Kuy S, Roman SA, Desai R, Sosa JA. Outcomes following thyroid and parathyroid surgery in pregnant women. *Arch Surg*. 2009;144(5):399-406.
- Rosen IB, Korman M, Walfish PG. Thyroid nodular disease in pregnancy: current diagnosis and management. *Clin Obstet Gynecol*. 1997;40(1):81-89.
- Fanarjian N, Athavale SM, Herrero N, et al. Thyroid cancer in pregnancy. *Laryngoscope*. 2007;117(10):1777-1781.
- Moosa M, Mazzaferri EL. Outcome of differentiated thyroid cancer diagnosed in pregnant women. *J Clin Endocrinol Metab*. 1997;82(9):2862-2866.
- Yasmeen S, Cress R, Romano PS, et al. Thyroid cancer in pregnancy. *Int J Gynaecol Obstet*. 2005;91(1):15-20.
- Nam KH, Yoon JH, Chang HS, Park CS. Optimal timing of surgery in well-differentiated thyroid carcinoma detected during pregnancy. *J Surg Oncol*. 2005;91(3):199-203.
- Doherty CM, Shindo ML, et al. Management of thyroid nodules during pregnancy. *Laryngoscope*. 1995;105(3 Pt 1):251-255.



When melasma involves extensive pigmentary changes, the patient is likely to have a poor response to topical therapy