

APPLIED EVIDENCE

New research findings that are changing clinical practice

Otitis externa: Providing relief while avoiding complications

Treatment options may be equally effective, but risks of ototoxicity vary

Practice recommendations

- Topical antimicrobial otic drops, supplemented by oral analgesics, provide prompt and effective therapy (B).
- Fluoroquinolones and neomycin-polymyxin B combinations have shown equal efficacy (A), but the former are preferred when trying to guard against ototoxicity or hypersensitivity (C).
- For severely painful otitis externa, consider inserting an ear wick and giving oral narcotics (C).
- Localized cellulitis requires systemic antimicrobial therapy (C).
- No compelling evidence exists on the effectiveness of astringent topical treatments for otitis externa. Also, topical astringents are often painful, which may impede adherence (B).

Widespread use of neomycin combinations may have led to an increase in the incidence of patient hypersensitivity and promoted antibiotic resistance in *Staphylococcus aureus* and *Pseudomonas aeruginosa*, the 2 most common pathogens of otitis externa (see **Pathogens of otitis externa**).

Recent controlled clinical trials have shown the effectiveness of otic fluoroquinolones, ofloxacin (Floxin Otic) and ciprofloxacin (Ciprodex), which have several clinical, microbiologic, and dosing

advantages over older topical antibiotics. Fluoroquinolones are not ototoxic and are effective against *S aureus* and *P aeruginosa*.

The incidence of fluoroquinolone-resistant *Pseudomonas* in otitis externa is low, and hypersensitivity is quite rare. Although they are slightly more expensive than neomycin combinations, fluoroquinolones require only 1 or 2 daily doses, possess superior in vitro activity, and provide a better safety profile that favor their use in moderate to severe otitis externa.

Symptoms and complications to watch for

Pain, which may be incapacitating, is the predominant complaint and the only symptom directly related to disease severity.^{1,6} Patients may also experience discharge, itchiness, and, in some cases, temporary hearing loss.^{1,5} A fluffy white exudate may signal a rare fungal infection, perhaps complicating an underlying bacterial infection.

Bone involvement. A rare, extremely severe form of otitis externa, known as malignant (or necrotizing) otitis externa, is caused by a *Pseudomonas* infection that invades the posterior cranial bone. This life-threatening form of otitis externa affects primarily elderly patients with diabetes who live in hot, humid environments. Malignant otitis externa usually requires hospitalization and parenteral antibiotic therapy.⁷

Stan L. Block, MD

Clinical Professor of Pediatrics,
University of Louisville,
Louisville, KY; University
of Kentucky, Lexington

CORRESPONDING AUTHOR

Stan L. Block, MD
201 South Fifth Street, Suite
102, Bardstown, KY 40004.
E-mail: slblock@pol.net

Pathogens of otitis externa

Acute inflammation of the external auditory canal most often is caused by bacterial infection. Infrequently, a fungal infection may be the cause.

Pseudomonas aeruginosa and *Staphylococcus aureus* are the predominant bacterial pathogens associated with otitis externa.^{1,2} The pathogenesis involves modification of the natural antimicrobial defense mechanisms of the external ear canal. Under healthy conditions, cerumen (ear wax), which is secreted by sebaceous and apocrine glands in the external ear canal, is acidic and contains lysozyme, an antimicrobial substance. The ear canal becomes vulnerable to bacterial infection when the cerumen barrier is disrupted by scratching or scraping, or macerated by prolonged exposure to water. Disruption of the external ear's epithelium, caused by seborrhea, eczema, or trauma, can also increase the risk of otitis externa. Because frequent swimming is the most common predisposing factor for the disease, otitis externa is commonly referred to as "swimmer's ear."^{1,3} As may be expected, the number of cases of otitis externa increases markedly during the summer months in temperate climates.⁴ The infection is uncommon in children aged less than 2 years.

Rarely, otitis externa appears to be caused by fungal infection.⁵ Such cases are not usually differentiated on clinical grounds, except when there is appearance of a fluffy white exudate. In most cases of fungal otitis externa, the fungus appears to be a superinfection after the bacterial infection. Thus, persistent otitis externa is typically treated with 2 or 3 courses of topical antibiotics before the clinician begins to investigate more specifically for fungal superinfection.

Secondary cellulitis. Summer often ushers in several cases of another severe form of otitis externa in children, involving a secondary cellulitis of the pre- and postauricular skin structures. If an underlying mastoiditis is uncertain, consider ordering a computerized tomography scan and referring for an otolaryngologic exam. This cellulitis infection also requires aggressive broad-spectrum oral or parenteral therapy.

■ Elements of successful treatment

Most treated cases of otitis externa resolve completely within 5 days. In a study conducted in the Netherlands, 35 out of 98

adult patients discontinued daily activities for a median of 4 days, and the median duration of bed rest was 3 days.³

However, secondary skin and soft tissue infections can slow resolution. They may also develop if treatment is delayed or ineffective. For uncomplicated otitis externa, treatment with an appropriate topical antibiotic, plus potent analgesics to relieve pain, is the preferred therapeutic approach.^{4,8} Choosing the optimal topical treatment, however, requires knowledge of evolving resistance among pathogens, possible hypersensitivity to neomycin, adherence factors, and cost issues.

Topical antibiotics usually sufficient.

Most cases of otitis externa without significant complications⁹ are effectively treated with just topical antibiotics; though, for more severe cases, I prefer to insert an ear wick and to use oral narcotics.⁷

In the 1970s to 1990s, topical combination preparations containing hydrocortisone and the antibiotics neomycin sulfate and polymyxin B were the mainstay of therapy for otitis externa.^{6,9} Approximately 5 years ago, topical fluoroquinolones became available for otitis externa. Given this range of antibiotic choices, physicians need to know the various treatment options and other modalities available.

Oral antibiotics. Additional oral or parenteral antibiotics are usually necessary for severe cases of otitis externa with secondary cellulitis or lymphadenitis.^{10,11} Oral antibiotics may also be necessary with concomitant disease at other sites (sinus, middle ear) or complications.

Pain relief. Nonsteroidal anti-inflammatory drugs (NSAIDs—eg, ibuprofen), acetaminophen, and narcotics (eg, codeine) are adjunctive measures for reducing ear pain.

Enabling compliance. Patient compliance, according to one systematic review, is inversely proportional to the prescribed number of doses per day.¹² Adherence with twice-daily dosing was significantly better than with 4-times-daily dosing for oral and topical medications.¹² Twice-daily dosing is accepted as readily as once-daily dosing¹²

FIGURE 1**Ear wick within the external ear canal**

The **ear wick** is inserted into the external auditory canal until the remaining edge is flush with the external ear. In smaller children, one fourth to one third of the wick may be cut to prevent it from falling out prematurely. Several drops of topical antibiotics are instilled onto the wick until it has fully expanded. At home, a few drops of topical antibiotic should be applied to the wick every few hours for the first 24 hours to keep the wick moist. The wick should be removed with tweezers within 24 to 48 hours if it has not already fallen out.

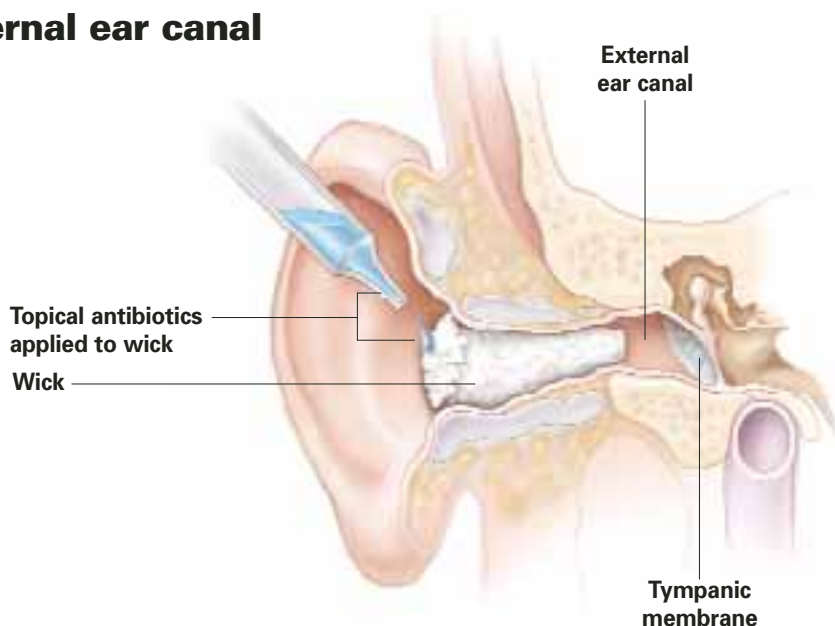


ILLUSTRATION BY: RICH LaROCCO

and may maintain continuity of drug action better than a once-daily regimen in the event a dose is forgotten.¹³

■ Is there a place for astringents?

Before antibiotic availability, the mainstay of treatment was topical compounds containing astringents such as aluminum acetate solution (Burow's Solution USP, Domeboro, and others) and acetic acid solutions (Vosol Otic).¹⁴⁻¹⁶ These preparations are still widely used but principally to prevent otitis externa.

Topical 8% aluminum acetate solution was as effective as a commonly used antimicrobial-corticosteroid topical mixture (polymyxin-neomycin-hydrocortisone) for 25 adult patients with otitis externa (72% vs 76%, respectively).¹⁷ In a double-blind, randomized study involving 65 adults and children, the effectiveness of aluminum acetate equaled that of gentamicin otic solution.¹⁸

In a Dutch study evaluating otitis externa in 213 adults, topical antibiotics were more effective than topical acetic acid alone and alleviated symptoms faster than

acetic acid plus steroids.

The lack of a large, well-structured, placebo-controlled study or other compelling evidence casts doubt on the relative effectiveness of astringent topical treatments for otitis externa. Also, topical astringents are often painful, which may impede adherence.¹⁹

Practitioners usually reserve nonspecific therapy such as acetic acid and Burow's solution for prevention and self-medication for mild symptoms. Studies that include measures of clinical goals, such as pain relief, cessation of symptoms, and eradication of infection, are needed before astringent agents can be recommended for routine therapy of moderate to severe otitis externa. Most treatment data concerning otitis externa have centered on therapy with antimicrobial otic drops.²⁰

■ Preparing the ear for antibiotic administration

Topical antibiotics are presumed to eradicate pathogens most effectively through direct contact at concentrations exceeding the minimum inhibitory concentration (MIC₉₀).²¹⁻²³

FAST TRACK

Most treated cases of otitis externa resolve completely within 5 days

TABLE

Common topical antibiotic treatments for otitis externa

TREATMENT (FORMULATION)	DOSING REGIMEN	ADVANTAGES/DISADVANTAGES
Neomycin sulfate/polymyxin B/hydrocortisone (suspension/acidic)	4 times daily	Efficacious, extensively used; moderately expensive (AWP \$65) Resistance and hypersensitivity increasing; potentially ototoxic; discourages compliance
Ofloxacin otic (solution/neutral)	Once or twice daily	Efficacious; no ototoxicity or hypersensitivity; favors compliance Resistance increasing; moderately expensive (AWP 5 cc \$44.45; 10 cc \$82.25)
Ciprofloxacin otic, with dexamethasone (suspension/acidic)	Twice daily	Efficacious; no ototoxicity with ciprofloxacin; favors compliance Resistance increasing; expensive (AWP \$85)

AWP, average wholesale price

FAST TRACK

Fluffy white exudate may signal fungal infection, perhaps complicating a bacterial infection

Debride if possible. Though the severity of pain may preclude debridement, removing debris from the external ear canal during the office visit will maximize delivery of the medication. This can be performed with a dry cotton swab or small Calgiswab or by suctioning with a metal or plastic catheter. Cleansing by irrigation or flushing of the ear canal with a syringe or pulsatile irrigator (Water-Pik) may be more tolerable for some patients, but probably should be performed only when the tympanic membrane can be visualized due to the risk that the debris overlies an unseen perforation of the tympanic membrane.²⁴

Ear wick helpful. After the ear canal has been debrided, consider the benefit of inserting an ear wick. Particularly if the ear canal is swollen, medication may not penetrate deep enough into the canal. In this situation, an ear wick, such as a Pope Oto-wick or Meroxel XL (Medtronic Xomed, Inc, Jacksonville, Fla) hydrogel polymer, can enhance medication delivery directly to the entire ear canal.

The medication is absorbed into the ear wick, which delivers the drug to the infected skin (FIGURE). As swelling subsides, most ear wicks extrude spontaneously, usually within 12 to 36 hours.

Once the edema subsides and much of the debris in the external ear canal has been cleared, topical antibiotics can be instilled.

Common topical therapies

Topical antibiotics commonly used for otitis externa are listed in the TABLE.

Combination drugs containing aminoglycosides

Combination topical drugs containing an aminoglycoside (neomycin), polymyxin B, and a corticosteroid were once the only antibiotic treatments for otitis externa approved by the US Food and Drug Administration.⁹ Neomycin is a bactericidal inhibitor of protein synthesis that is modestly active against *S aureus* but has minimal activity against *P aeruginosa*.²⁵

In 1999, a prevalence study of aminoglycoside resistance in Europe found that 25% of the *S aureus* isolates tested were resistant to gentamicin.²⁶ This study also found a high incidence (20%–38%) of gentamicin-resistant *P aeruginosa* isolates from Belgium, France, Italy, and Poland.²⁶ Furthermore, in a prospective study of aural isolates of *P aeruginosa*, only 17.8% were susceptible to neomycin.²⁷

Polymyxin B is active against *P aeruginosa* but not against *S aureus*.²⁸

Combining neomycin and polymyxin B broadens the spectrum of antimicrobial activity. Hydrocortisone, a low-potency steroid, purportedly helps reduce associated inflammation. Several ophthalmic preparations that contain a corticosteroid or an aminoglycoside, such as gentamicin or tobramycin, have been used off-label for otitis externa.^{3,29}

Neomycin/polymyxin B/hydrocortisone has been shown in earlier clinical trials to be efficacious in up to 97% of cases of otitis externa.¹⁶ However, *S aureus* has been increasingly resistant to aminoglycosides.^{30,31} More than 10% of *S aureus* strains were resistant to gentamicin between 1987 and 1999.^{26,32}

Possible ototoxicity. Aminoglycoside drops may cause vestibular ototoxicity when the tympanic membrane is perforated. Aminoglycosides instilled into the inner ear of test animals have been shown to damage cochlear inner and outer hair cells.³³⁻³⁵ Only a few similar case studies in humans have been published.³⁶⁻³⁸ Assessment of the tympanic membrane is often difficult because of excessive swelling of the external ear canal¹ or patient noncooperation due to pain. In such cases—though tympanic membrane perforation is uncommon in otitis externa—physicians may want to avoid aminoglycosides.

Beware hypersensitivity. Drug hypersensitivity is another concern with topical aminoglycosides. Neomycin and thimerosal are among the antibiotic allergens most commonly detected on patch testing.^{39,40} Thimerosal is a preservative added to common otic formulations of neomycin/polymyxin B/hydrocortisone.⁴¹ In a retrospective review of patch testing reactions from 587 adult patients, neomycin sulfate and thimerosal elicited a hypersensitivity reaction in 53% and 18% of the patients, respectively.⁴⁰

Hypersensitivity to these agents has also been shown in children by skin testing, although it is apparently rare clinically.^{42,43} A patch testing study involving 562 healthy

schoolchildren found that 18.4% and 14.9% of the children had hypersensitivity on skin testing to neomycin sulfate and thimerosal, respectively.⁴³ The high incidence of sensitization to neomycin and thimerosal may be related to the common use of neomycin as a topical ointment on skin abrasions and of thimerosal as a bacteriostatic preservative in immunizations in the past.

Fluoroquinolones

Oral fluoroquinolone antibiotics have been available for adults since 1990. The fluoroquinolones ofloxacin and ciprofloxacin were approved as topical therapy for otitis externa in 1997 and 1998, respectively. In addition, ofloxacin is indicated for otorrhea from the middle ear through an implanted tympanostomy tube (tube otorrhea).

Fluoroquinolones inhibit DNA gyrase and topoisomerase, which are required for bacterial DNA synthesis.²³ These are broad-spectrum antibiotics that have good in vitro activity against both *S aureus* and *P aeruginosa*.²³ An in vitro analysis of antimicrobial activity against clinical isolates of *S aureus* and *P aeruginosa* indicated that ofloxacin and ciprofloxacin were more active against these pathogens than was neomycin.⁴⁴ The MIC₉₀ values of ofloxacin and ciprofloxacin, respectively, were 1.0 µg/mL and 2.0 µg/mL for *S aureus* and 2.0 µg/mL and 0.25 µg/mL for *P aeruginosa*. In contrast, the MIC₉₀ values of neomycin were 4.0 µg/mL for *S aureus* and 16.0 µg/mL for *P aeruginosa*. The MIC₉₀ for polymyxin B against *P aeruginosa* was 2.0 g/mL.⁴⁵

Clinically equivalent to neomycin compound. Recent clinical studies have shown that ofloxacin and ciprofloxacin are as efficacious as neomycin/polymyxin B/hydrocortisone in the treatment of otitis externa.^{21,22,46} In one study, the overall cure rate was 89% in patients treated with either ofloxacin (N=301) or neomycin/polymyxin B/hydrocortisone (N=300).²¹ In another study, ciprofloxacin was comparably effective as neomycin/polymyxin B/hydrocortisone therapy (93% [N=239] vs 87%

FAST TRACK

Factors in choosing a topical antibiotic: evolving pathogen resistance, patient adherence, cost, possible hypersensitivity to neomycin

FAST TRACK

Remove debris from the ear canal, if not too painful, to maximize antibiotic contact

[N=228]; 95% confidence interval, 0.0–10.5).²²

***S aureus* resistance has increased.** Fluoroquinolone use has been reported to lead to resistance in topical infections other than otitis externa. For example, the incidence of fluoroquinolone-resistant keratitis isolates of *S aureus* increased from 11% in 1990 to 28% in 1998.⁴⁷ In another 5-year review of bacterial keratitis cases,⁴⁸ the incidence of ciprofloxacin-resistant isolates of *S aureus* increased annually from 5.8% in 1993 to 35.0% in 1997, and the incidence of resistant isolates to ofloxacin increased from 4.7% to 35.0% over the same period.⁴⁸ In contrast, *P aeruginosa* isolates remained susceptible to fluoroquinolones during the study periods.⁴⁸ Resistance of *P aeruginosa* to fluoroquinolones has increased only slightly.⁴⁹ Between 1991 and 1994, 0.44% of ocular isolates of *P aeruginosa* were resistant to ciprofloxacin, while 4.1% showed in vitro resistance between 1995 and 1998.⁴⁹

Fluoroquinolone has advantages over combination therapy. Ofloxacin and ciprofloxacin do not cause ototoxicity in humans and do not damage isolated cochlear cells, as can neomycin/polymyxin B/hydrocortisone combinations.^{34,50} In fact, both ofloxacin and ciprofloxacin/dexamethasone have been approved for use in patients with patent tympanostomy tube otorrhea.²⁹

Topical use of ofloxacin and ciprofloxacin is not associated with hypersensitivity, and hypersensitivity after the oral administration of these drugs is rare.^{51,52}

Finally, the once- or twice-daily dosage regimen of the topical fluoroquinolones markedly improves therapeutic adherence when compared with the 4-times-daily regimen of neomycin/polymyxin B/hydrocortisone.^{21,22,46}

Preparations containing corticosteroids

The benefit of corticosteroids for otitis externa is not well established, though they are added to many topical antibiotic preparations. In one study, the addition of hydrocortisone to neomycin and polymyx-

in B reduced pain by approximately 1 day for patients with otitis externa.²² A combination of ciprofloxacin 0.3% and dexamethasone 0.1% administered twice daily is indicated for acute otitis externa,⁵³ as was supported by an efficacy rate of 90.9% in a recent randomized, observer-masked, parallel-group, multicenter study in 468 children and adults.⁵⁴ Although hypersensitivity to topical corticosteroids is well documented in published clinical studies, it seems to be rare in clinical practice.^{55–57}

Special circumstances

Severe pain. Inserting an ear wick and prescribing a topical fluoroquinolone plus an oral narcotic, such as acetaminophen with codeine, may be the optimal approach to resolving the infection and managing pain. Compared with neomycin combinations, ofloxacin and ciprofloxacin are somewhat more active in vitro against likely pathogens.

Otitis externa with concomitant acute otitis media. Antibiotics such as amoxicillin/clavulanate or cefdinir for acute otitis media should be used in addition to topical antibiotics.

Otitis externa with mild localized cellulitis. A standard oral antibiotic that covers staphylococci is recommended. Oral fluoroquinolones, for patients over 17 years of age, or intravenous ceftazidime may also be considered for more severe cases associated with aural cellulitis.

For younger children, I have prescribed oral ciprofloxacin (off-label), which has been recently approved for children older than 12 months with complicated urinary tract infection. Outpatient parenteral ceftriaxone may alternatively be used for some cases of cellulitis if the patient is only moderately ill. If rates of community-acquired methicillin-resistant *S aureus* exceed 15% to 20% in the community, clinicians should consider empiric therapy initially with trimethoprim-sulfamethoxazole or clindamycin.

Fungal infection. If a patient develops (1) otitis externa refractory to 2 consecutive

courses of topical antibiotics, or (2) exhibits a discharge that looks like a white, fluffy exudate, suspect a fungal infection and obtain a culture of the exudate. Empiric therapy with either oral fluconazole (Diflucan) or topical ciclopirox (Loprox) solution should be considered. ■

DISCLOSURE

The author has received grant/research support from Abbott Laboratories and GlaxoSmithKline, and has served on speakers' bureaus for Abbott Laboratories.

REFERENCES

- Agius AM, Pickles JM, Burch KL. A prospective study of otitis externa. *Clin Otolaryngol* 1992; 17:150-154.
- Clark WB, Brook I, Bianki D, Thompson DH. Microbiology of otitis externa. *Otolaryngol Head Neck Surg* 1997; 116:23-25.
- van Asperen I, de Rover CM, Schijven JF, Oetomo SB, Schellekens JF, van Leeuwen NJ, et al. Risk of otitis externa after swimming in recreational fresh water lakes containing *Pseudomonas aeruginosa*. *BMJ* 1995; 311:1407-1410.
- Rowlands S, Devalia H, Smith C, Hubbard R, Dean A. Otitis externa in UK general practice: a survey using the UK General Practice Research Database. *Br J Gen Pract* 2001; 51:533-538.
- Hawke M, Wong J, Krajden S. Clinical and microbiological features of otitis externa. *J Otolaryngol* 1984; 13:289-295.
- Halpern MT, Palmer CS, Seidlin M. Treatment patterns for otitis externa. *J Am Board Fam Pract* 1999; 12:1-7.
- Lang R, Goshen S, Kitzes-Cohen R, Sade J. Successful treatment of malignant external otitis with oral ciprofloxacin: report of experience with 23 patients. *J Infect Dis* 1990; 161:537-540.
- Hannley MT, Denneny JC, Holzer SS. Use of ototopical antibiotics in treating 3 common ear diseases. *Otolaryngol Head Neck Surg* 2000; 122:934-940.
- Cassisi N, Cohn A, Davidson T, Witten BR. Diffuse otitis externa: clinical and microbiologic findings in the course of a multicenter study on a new otic solution. *Ann Otol Rhinol Laryngol Suppl* 1977; 86:1-16.
- Zikk D, Rapoport Y, Redianu C, Shalit I, Himmelfarb MZ. Oral ofloxacin therapy for invasive external otitis. *Ann Otol Rhinol Laryngol* 1991; 100:632-637.
- Kimura AC, Pien FD. Head and neck cellulitis in hospitalized adults. *Am J Otolaryngol* 1993; 14:343-349.
- Claxton AJ, Cramer J, Pierce C. A systematic review of the associations between dose regimens and medication compliance. *Clin Ther* 2001; 23:1296-1310.
- Urquhart J. Ascertaining how much compliance is enough with outpatient antibiotic regimens. *Postgrad Med J* 1992; 68(suppl 3):S49-S59.
- Garrity JD, Halliday TC, Glassman JM. Prevention of swimmer's ear by simple prophylactic regimen. *Curr Ther Res Clin Exp* 1974; 16:437-441.
- Dadagian AJ, Hicks JJ, Ordonez GE, Glassman JM. Treatment of otitis externa: a controlled bacteriologic-clinical evaluation. *Curr Ther Res Clin Exp* 1974; 16:431-436.
- Lambert IJ. A comparison of the treatment of otitis externa with 'Otosporin' and aluminium acetate: a report from a services practice in Cyprus. *J R Coll Gen Pract* 1981; 31:291-294.
- Clayton MI, Osborne JE, Rutherford D, Rivron RP. A double-blind, randomized, prospective trial of a topical antiseptic versus a topical antibiotic in the treatment of otorrhoea. *Clin Otolaryngol* 1990; 15:7-10.
- Kleinerman ES, Knowles RD, Lachman LB, Gutterman JU. Effect of recombinant granulocyte/macrophage colony-stimulating factor on human monocyte activity in vitro and following intravenous administration. *Cancer Res* 1988; 48:2604-2609.
- van Balen FA, Smit WM, Zuihoff NP, Verheij TJ. Clinical efficacy of three common treatments in acute otitis externa in primary care: randomised controlled trial. *BMJ* 2003; 327:1201-1205.
- Jones RN, Milazzo J, Seidlin M. Ofloxacin otic solution for treatment of otitis externa in children and adults. *Arch Otolaryngol Head Neck Surg* 1997; 123:1193-1200.
- Pistorius B, Westberry K, Drehobl M. Prospective, randomized, comparative trial of ciprofloxacin otic drops, with or without hydrocortisone, vs. polymyxin B-neomycin-hydrocortisone otic suspension in the treatment of acute diffuse otitis externa. *Infect Dis Clin Pract* 1999; 8:387-395.
- Hooper DC. Quinolones. In: Mandell G, Bennett J, Dolin R, eds. *Mandell, Douglas, and Bennett's Principles and Practice of Infectious Diseases*. Philadelphia, Pa: Churchill Livingstone, 2000:404-413.
- Blake P, Matthews R, Hornibrook J. When not to syringe an ear. *N Z Med J* 1998; 111:422-424.
- Chambers H. Antimicrobial agents: the aminoglycosides. In: Hardman J, Limbird L, eds. *Goodman & Gilman's The Pharmacological Basis of Therapeutics*. New York: McGraw-Hill, 2001:1219-1238.
- Schmitz F-J, Verhoef J, Fluit AC. Prevalence of aminoglycoside resistance in 20 European university hospitals participating in the European SENTRY Antimicrobial Surveillance Programme. *Eur J Clin Microbiol Infect Dis* 1999; 18:414-421.
- Dohar JE, Kenna MA, Wadowsky RM. In vitro susceptibility of aural isolates of *Pseudomonas aeruginosa* to commonly used ototopical antibiotics. *Am J Otol* 1996; 17:207-209.
- Chambers H. Antimicrobial agents: protein synthesis inhibitors and miscellaneous antibacterial agents. In: Hardman J, Limbird L, eds. *Goodman & Gilman's The Pharmacological Basis of Therapeutics*. New York: McGraw-Hill, 2001:1239-1271.
- Goldblatt EL. Efficacy of ofloxacin and other otic preparations for acute otitis media in patients with tympanostomy tubes. *Pediatr Infect Dis J* 2001; 20:116-119.
- Bovelacci A, Montini G, Ramacciotti PG. Changes in resistance to aminoglycoside antibiotics of different bacterial strains isolated during the period 1978 to 1983. Netilmicin as alternative therapy. *Chemioterapia* 1985; 4:439-444.
- Courcol RJ, Pinkas M, Martin GR. A seven year survey of antibiotic susceptibility and its relationship with usage. *J Antimicrob Chemother* 1989; 23:441-451.
- Chambers HF. The changing epidemiology of *Staphylococcus aureus*? *Emerg Infect Dis* 2001; 7:178-182.
- Wright CG, Meyerhoff WL. Ototoxicity of otic drops applied to the middle ear in the chinchilla. *Am J Otolaryngol* 1984; 5:166-176.
- Barlow DW, Duckert LG, Kreig CS, Gates GA. Ototoxicity of topical otomicrobials agents. *Acta Otolaryngol* 1995; 115:231-235.
- Jinn TH, Kim PD, Russell PT, Church CA, John EO, Jung TT. Determination of ototoxicity of common otic drops using isolated cochlear outer hair cells. *Laryngoscope* 2001; 111:2105-2108.
- Wong DL, Rutka JA. Do aminoglycoside otic preparations cause ototoxicity in the presence of tympanic membrane perforations? *Otolaryngol Head Neck Surg* 1997; 116:404-410.
- Marais J, Rutka JA. Ototoxicity and topical eardrops. *Clin Otolaryngol* 1998; 23:360-367.

FAST TRACK

An ear wick can enhance antibiotic delivery

38. Bath AP, Walsh RM, Bance ML, Rutka JA. Ototoxicity of topical gentamicin preparations. *Laryngoscope* 1999; 109:1088–1093.
39. Van Ginkel CJ, Bruintjes TD, Huizing EH. Allergy due to topical medications in chronic otitis externa and chronic otitis media. *Clin Otolaryngol* 1995; 20:326–328.
40. Dickel H, Taylor JS, Evey P, Merk HF. Delayed readings of a standard screening patch test tray: frequency of “lost,” “found,” and “persistent” reactions. *Am J Contact Dermat* 2000; 11:213–217.
41. Suneja T, Belsito DV. Thimerosal in the detection of clinically relevant allergic contact reactions. *J Am Acad Dermatol* 2001; 45:23–27.
42. Manzini BM, Ferdani G, Simonetti V, Donini M, Seidenari S. Contact sensitization in children. *Pediatr Dermatol* 1998; 15:12–17.
43. Barros MA, Baptista A, Correia TM, Azevedo F. Patch testing in children: a study of 562 schoolchildren. *Contact Dermatitis* 1991; 25:156–159.
44. Roland PS, Stroman DW. Microbiology of acute otitis externa. *Laryngoscope* 2002; 112:1166–1177.
45. Gales AC, Reis AO, Jones RN. Contemporary assessment of antimicrobial susceptibility testing methods for polymyxin B and colistin: review of available interpretative criteria and quality control guidelines. *J Clin Microbiol* 2001; 39:183–190.
46. Torum B, Block SL, Avila H, Montiel F, Oliva A, Quintanilla W, et al. Efficacy of ofloxacin otic solution once daily for 7 days in the treatment of otitis externa: a multicenter, open-label, phase III trial. *Clin Ther* 2004; 26:1046–1054.
47. Alexandrakis G, Alfonso EC, Miller D. Shifting trends in bacterial keratitis in south Florida and emerging resistance to fluoroquinolones. *Ophthalmology* 2000; 107:1497–1502.
48. Goldstein MH, Kowalski RP, Gordon YJ. Emerging fluoroquinolone resistance in bacterial keratitis: a 5-year review. *Ophthalmology* 1999; 106:1313–1318.
49. Chaudhry NA, Flynn HW Jr, Murray TG, Tabandeh H, Mello MO Jr, Miller D. Emerging ciprofloxacin-resistant *Pseudomonas aeruginosa*. *Am J Ophthalmol* 1999; 128:509–510.
50. Russell PT, Church CA, Jinn TH, Kim DJ, John EO, Jung TT. Effects of common topical otic preparations on the morphology of isolated cochlear outer hair cells. *Acta Otolaryngol* 2001; 121:135–139.
51. Pipek R, Vulfsons S, Wolfvitz E, Har-Shai Y, Taran A, Peled IJ. Case report: ofloxacin-induced hypersensitivity vasculitis. *Am J Med Sci* 1996; 311:82–83.
52. Reaño M, Vives R, Rodriguez J, Daroca P, Canto G, Fernandez J. Ciprofloxacin-induced vasculitis. *Allergy* 1997; 52:599–600.
53. Ciprodex® [manufacturer’s prescribing information]. Fort Worth, Tex: Alcon Laboratories, Inc, 2003.
54. Roland PS, Pien FD, Schultz CC, Henry DC, Conroy PJ, Wall GM, et al. Efficacy and safety of topical ciprofloxacin/dexamethasone versus neomycin/polymyxin B/hydrocortisone for otitis externa. *Curr Med Res Opin* 2004; 20:1175–1183.
55. Burden AD, Beck MH. Contact hypersensitivity to topical corticosteroids. *Br J Dermatol* 1992; 127:497–500.
56. Dooms-Goossens A, Morren M. Results of routine patch testing with corticosteroid series in 2073 patients. *Contact Dermatitis* 1992; 26:182–191.
57. Bircher AJ, Thurlimann W, Hunziker T, et al. Contact hypersensitivity to corticosteroids in routine patch test patients. A multi-centre study of the Swiss Contact Dermatitis Research Group. *Dermatology* 1995; 191:109–114.

Visit the **New JFPonline.com!**

THE JOURNAL OF FAMILY PRACTICE website has added many new features, making it even more useful and informative:



- New design with reader-friendly text
- Enhanced search, making it easier to find what you need
- Online purchase of subscriptions or single articles
- Plus more article options—
 - view full text or PDF
 - add to favorites
 - print this article
 - e-mail this article

And you can still access all the practice opportunities, supplements with CME credit, and other resources you’ve come to depend on at **JFPonline.com**

**Whether you’re a first-time or frequent visitor
—there’s lots more to see at the new JFPonline.com!**