

Abdominal pain in a pregnant woman

A 24-year-old woman, pregnant with a fetus at 22 weeks gestational age, came to the OB triage area with abdominal pain, nausea, and vomiting. She described a sharp pain that began the night before, starting at the umbilicus and radiating toward her right side; she rated it 7 out of 10.

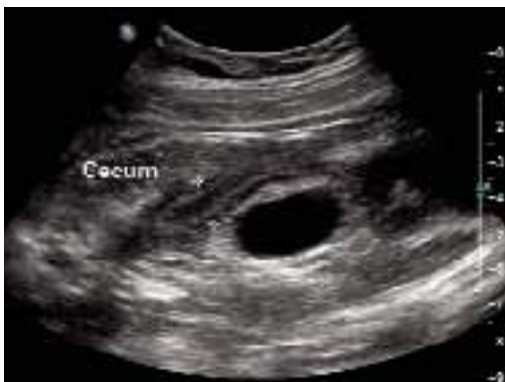The patient said there had been no contractions, vaginal bleeding or fluid leaking, or dysuria. She reported having GERD at times. She experienced chills the day before, but no fever. She had similar pain 1 month before that resolved spontaneously, and for which a cause was never determined. She had nothing significant in her medical history; family history was noncontributory.

On examination, she was afebrile, normotensive, and in no apparent distress. Her heart and lungs were normal. Her abdomen was soft and gravid with a fundal height of 22 cm. Bowel sounds were present in all 4 quadrants. Fetal heart tones

were normal, and there was no indication of contractions. Her abdomen was diffusely tender, with significant tenderness to deep palpation in the right upper quadrant at first. There was no rebound or guarding. The psoas sign was negative. The obturator sign was positive, with increased pain 4 out of 10 in the right lower quadrant. There were no abdominal masses. Digital rectal examination revealed no rectal masses, and a guaiac stool test result was negative. A few hours later, the tenderness seemed to move toward the right lower quadrant (**FIGURES 1 AND 2**).

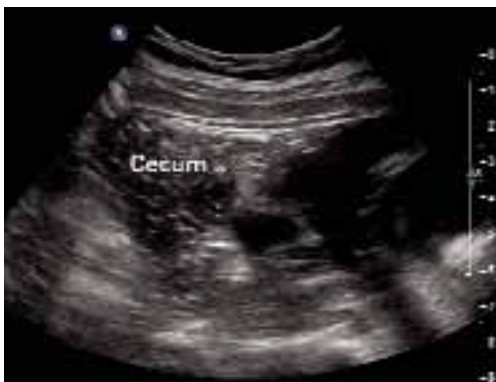- **What is the most likely diagnosis?**
- **How do the ultrasound images help you make the diagnosis?**

FIGURE 1 Ultrasound of RLO



Ultrasound view of right lower quadrant with cecum labeled.

FIGURE 2 A second ultrasound of RLO



Second ultrasound view of the patient's right lower quadrant.

**Maria Muñoz, MD, and
Richard P. Usatine, MD**

University of Texas
Health Sciences Center
at San Antonio

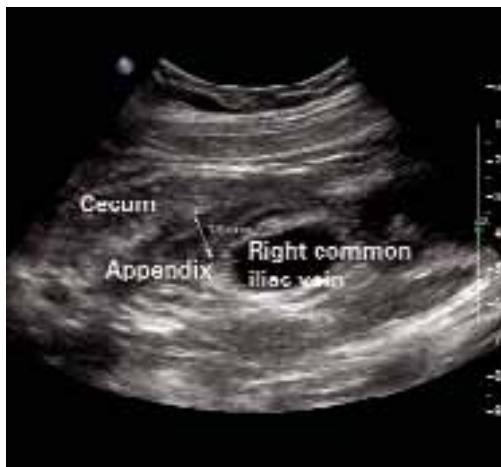FEATURE EDITOR

Richard P. Usatine, MD
University of Texas Health
Sciences Center at San
Antonio

CORRESPONDING AUTHOR

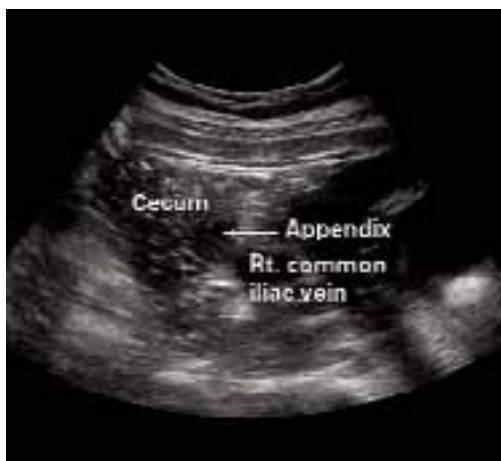Richard P. Usatine, MD,
University of Texas Health
Science Center at San
Antonio, Department of
Family and Community
Medicine, MC 7794, 7703
Floyd Curl Drive, San Antonio,
TX 78229-3900. E-mail:
usatine@uthscsa.edu

FIGURE 3 Appendix: Longitudinal view



Longitudinal view by ultrasound of enlarged appendix with diameter equal to 13 mm (normal is less than 6 mm).

FIGURE 4 Appendix: Transverse view



Transverse view of inflamed appendix by ultrasound with wall thickening.

FAST TRACK

Diagnosis of appendicitis is difficult because many of the symptoms occur normally in pregnancy

■ Differential diagnosis

The differential diagnosis of abdominal pain in a gravid patient includes placental abruption, cholecystitis, pancreatitis, appendicitis, intussusception, pyelonephritis, round ligament syndrome, hydronephrosis, ovarian torsion, uterine fibroid degeneration, ovarian cysts or tumors, intra-abdominal and rectus muscle abscesses, and Crohn's disease with diffuse peritoneal inflammation. Given the location of the pain and the lack of vaginal bleeding, the most likely diagnoses are cholecystitis and appendicitis.

■ Making the diagnosis

We performed several laboratory analyses, including a complete blood count, chemistry panel (including electrolytes and liver function studies), amylase, lipase, and a urinalysis. The test results were all normal. She had a white blood cell count of 15,000/ μ L, which can be normal in pregnancy. The initial evaluating physician had obtained a right upper quadrant ultrasound, which showed no gallstones or bilateral hydronephrosis; unfortunately, no attempt was made to visualize the right lower quadrant or appendix at that time.

In light of the physical exam findings and the absence of gallstones, the patient was admitted to rule out appendicitis. The surgery team at the university hospital was consulted. They requested a computed tomography (CT) scan of the abdomen with and without contrast. To avoid the risk of radiation to the fetus, the family medicine team spoke with Radiology to obtain another ultrasound.

The ultrasound showed an enlarged and inflamed appendix with a transverse diameter of 13 mm (normal is <6 mm) (FIGURES 3 AND 4).¹ A graded compression technique was used to assess the appendix. This involves using pressure of the ultrasound probe starting above the area of tenderness and working toward the tender area while scanning for the appendix. This showed obvious peristalsis in the cecum and no movement within the appendix, indicating obstruction or inflammation.

■ Patient management and outcome

An open appendectomy was performed. The appendix was inflamed and enlarged as suspected. The histology showed neutrophilic infiltration of mucosa, muscle, and serosa (FIGURE 5). Postoperatively, the patient recovered in Labor and Delivery to monitor for possible preterm labor. She did not develop any signs or symptoms of preterm labor, and was transferred to a regular antepartum floor after being observed for 6 hours.

She did well during her hospitalization, and was sent home on post-op day 2. Her abdominal pain had resolved, and she had very little post-op tenderness.

■ Discussion: Appendicitis in pregnancy

Acute appendicitis is the most common condition requiring surgery during pregnancy.² Suspected appendicitis accounts for nearly two thirds of all nonobstetric exploratory laparotomies performed during pregnancy; most cases occur in the second and third trimesters.

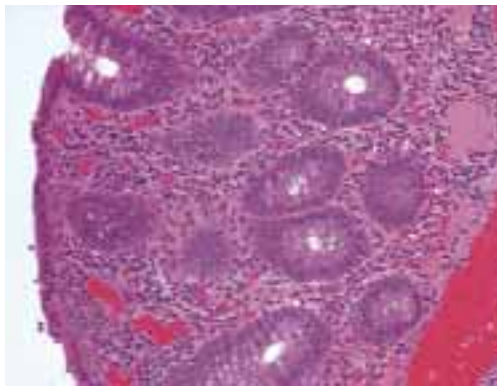
The incidence of appendicitis is 0.4 to 1.4 per 1000 pregnancies.² Although the incidence of appendicitis is not increased during pregnancy, rupture of the appendix occurs 2 to 3 times more frequently in pregnancy secondary to delays in diagnosis and operation. Maternal and perinatal mortality and morbidity rates are greatly increased when appendicitis is complicated by peritonitis.

A difficult diagnosis

Diagnosis is difficult because many symptoms are considered to be normal during pregnancy. Many times, pain in the right lower quadrant of the abdomen may be attributed to round ligament pain or urinary tract infection. After the first trimester, the appendix is gradually displaced above McBurney's point, with horizontal rotation of its base. This upward displacement occurs until the eighth month of gestation, when more than 90% of appendices lie above the iliac crest, and 80% rotate upward and toward the right subcostal area.^{2,3}

The most consistent clinical symptom encountered in pregnant women with appendicitis is vague right-sided abdominal pain.² Depending on the gestation, muscle guarding and rebound tenderness may or may not be present. Nausea, vomiting, and anorexia are usually present as in the nonpregnant patient. Twenty-five percent of pregnant patients with appendicitis are afebrile, as our patient was.^{2,4}

FIGURE 5 Histology



Pathologic specimens showing neutrophilic infiltration of mucosa, muscle, and serosa.

The leukocytosis of pregnancy makes it difficult to determine if there is an infection. Not all pregnant patients with appendicitis will have a white blood cell count greater than 16,000/ μ L, but approximately 75% of them will have a left shift in the differential.² A urinalysis may reveal pyuria and hematuria and can mislead the physician to explain the symptoms as pyelonephritis.²

■ Treatment: Appendectomy, antibiotics if needed

Treatment of nonperforated acute appendicitis in pregnancy is appendectomy. In the first trimester, a laparoscopic appendectomy may be performed.² Intravenous antibiotics are indicated with perforation, peritonitis or abscess formation.^{2,5}

Tocolysis is unnecessary in uncomplicated appendicitis, but may be indicated if the patient goes into labor after surgery. In the late third trimester, with perforation or peritonitis, a cesarean section is indicated.

Evaluation is imperative

Fetal loss may occur in association with preterm labor and delivery or with generalized peritonitis and sepsis, and occurs only rarely in uncomplicated appendicitis. Fetal loss appears to be more closely associated with severity of appendicitis than with surgical intervention.^{2,5,6}

FAST TRACK

Fetal loss is more likely with severe appendicitis than with intervention; evaluate abdominal pain in all pregnancies

TABLE

**Ultrasound and CT
in the diagnosis of appendicitis**

TEST	SN	SP	LR+	LR-
Ultrasound	0.86 (0.83–0.88)	0.81 (0.78–0.84)	5.8 (3.5–9.5)	.019 (0.13–0.27)
CT	0.94 (0.91–0.95)	0.95 (0.93–0.96)	13.3 (9.9–17.9)	0.09 (0.07–0.12)

Sn, sensitivity; Sp, specificity; LR+, positive likelihood ratio; LR-, negative likelihood ratio; CT, computed tomography.

Source: Teresawa et al, *Ann Intern Med* 2004.⁷

■ **Imaging test characteristics:
Is sonography enough?**

Thus, it is imperative that any pregnant patient that comes in to the hospital or clinic with abdominal pain be evaluated for appendicitis. Ultrasound was a valuable diagnostic tool in this case and saved both the patient and developing fetus the radiation exposure of a CT scan. Ultrasound has a high specificity for diagnosing appendicitis if the appendix is visualized with abnormal findings. However, the sensitivity is not as high as CT, and failure to visualize the appendix adequately would have required a decision between appendectomy on clinical grounds only or going through with the CT scan.

The sensitivity, specificity, and positive and negative predictive values for ultrasonography and CT scans in the diagnosis of appendicitis are given in the **TABLE** (level of evidence [LOE]=1a).⁷

In a prospective study of patients with clinical signs and symptoms of acute appendicitis using a graded compression technique of ultrasonography, sonographic testing was as accurate as the focused unenhanced single-detector helical CT. The primary sonographic criterion for diagnosing acute appendicitis was an incompressible appendix with a transverse outer diameter of 6 mm or larger, as seen in this patient. The sensitivity of CT and sonography was 76% and 79%, respectively; the specificity was 83% and 78%; the accuracy was 78% and 78%; the pos-

itive predictive value was 90% and 87%; and the negative predictive value was 64% and 65% (LOE=2a).⁸

In conclusion, it is reasonable to use graded compression ultrasonography in a pregnant woman with suspected appendicitis. If the suspicion for appendicitis is high, a negative result may still need further evaluation with a CT or ultimately lead to abdominal surgery despite negative imaging studies. ■

REFERENCES

1. Hansen GC, Toot PJ, Lynch CO. Subtle ultrasound signs of appendicitis in pregnancy. A case report. *J Reprod Med* 1993; 3:223–224.
2. Tamir IL, Bongard FS, Klein SR. Acute appendicitis in the pregnant patient. *Am J Surg* 1990; 160:571–576.
3. Hodjati H, Kazerooni, T. Location of the appendix in the gravid patient: a re-evaluation of the established concept. *Int J Gynecol Obstet* 2003; 81:245–247.
4. Morad JDO, Elliott JP, Lisboa L. Appendicitis in pregnancy: new information that contradicts long-held clinical beliefs. *Am J Obstet Gynecol* 2002; 182:1027–1029.
5. Andersen B, Nielsen TF. Appendicitis in pregnancy: diagnosis, management and complications. *Acta Obstet Gynecol Scand* 1999; 78:758–762.
6. Thurnau GR, Hales KA. Appendicitis in pregnancy. *Female Patient* 1992; 17:81.
7. Teresawa T, Blackmore CC, Bent S, Kohlwees RJ. Systematic review: computed tomography and ultrasonography to detect acute appendicitis in adults and adolescents. *Ann Intern Med* 2004; 141:537–546.
8. Poortman P, Lohle PN, Schoemaker CM et al. Comparison of CT and sonography in the diagnosis of acute appendicitis: a blinded prospective study. *AJR Am J Roentgenol* 2003; 181:1355–1359.

FAST TRACK

A negative result on graded compression ultrasound may need further evaluation with CT