

APPLIED EVIDENCE

New research findings that are changing clinical practice

Chronic compartment syndrome: Tips on recognizing and treating

The patient's history offers more important clues than physical exam

Practice recommendations

- A patient's description of symptoms and pattern of occurrence is the most reliable clinical guide. Confirm suspicion of chronic compartment syndrome by documenting intracompartmental pressures. Other diagnostic modalities, though promising, have no place in the work-up currently (C).
- Study data are sparse for conservative treatments, which seem largely unsuccessful in common clinical experience. Base any decision to offer conservative therapy on an individual's circumstances. It is usually impractical to ask competitive athletes to change sports or reduce intensity (C).
- Fasciotomy is an effective treatment for chronic compartment syndrome. Fasciotomy is preferred by some practitioners (C).

Shin splints and stress fractures are injuries we are accustomed to seeing among younger athletes. A less well-known painful injury becoming more prevalent—perhaps especially among young female athletes—is chronic compartment syndrome (CCS).

The patient's history offers more important clues to CCS than does the phys-

ical exam. Direct measurement of intracompartmental pressure—as described in this article—is the best means of confirming the diagnosis. Because it's an invasive procedure, first rule out shin splints and other more common disorders. In older, even nonathletic persons, who can also suffer from CCS, the list of disorders to rule out grows longer.

Outpatient surgical treatment relieves the pain of CCS and most often prevents recurrences.

Clinical presentation

The classic presentation of CCS is a young athlete who complains of an aching pain or a crampy ache in the lower leg during exercise, in an area of the leg corresponding to 1 of its 4 compartments (**FIGURE 1**). Symptoms are bilateral in 70% to 80% of athletes who develop compartment syndrome.^{1,2,3}

Symptom traits vary. Other patients describe a sensation of tightness, and some even notice a swelling or bulge over the affected compartment. Many patients describe a numbness or tingling at the affected site that occasionally radiates to the foot. They also often report a feeling of weakness and, in severe cases, may develop true muscle weakness such as drop foot

Jon Englund, MD

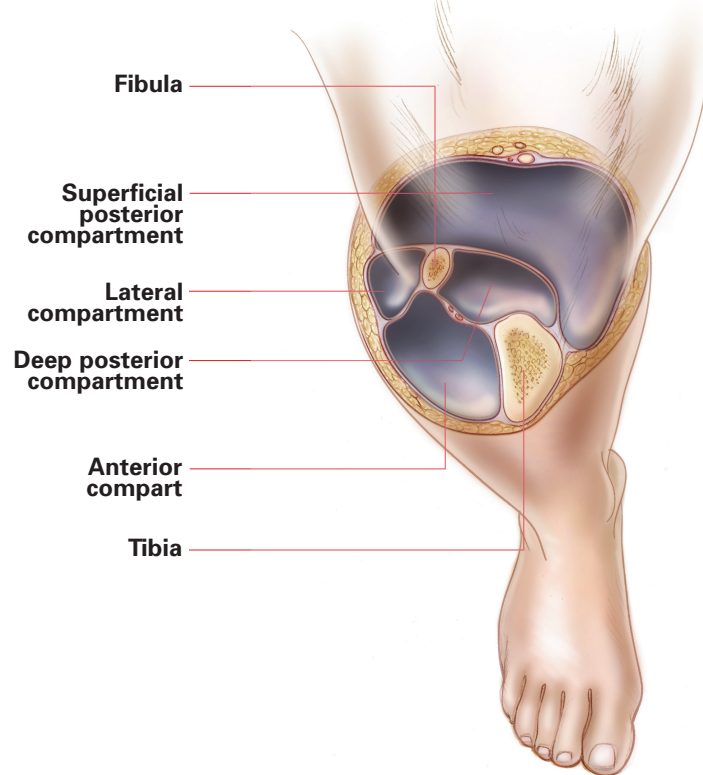
Fellow, South Bend Primary Care Sports Medicine Fellowship Program, South Bend, Indiana

CORRESPONDING AUTHOR

Jon Englund, MD, Memorial Healthplex Sports Medicine Institute, 111 West Jefferson, South Bend, IN 46601.
E-mail: jon.englund@aurora.org

APPLIED EVIDENCE

FIGURE 1
How chronic compartment syndrome develops



The lower leg comprises 4 main compartments: anterior, lateral, superficial posterior, and deep posterior. Some authorities think the superficial posterior compartment should be further divided into the lateral and medial superficial posterior compartments, reflecting the 2 heads of the gastrocnemius muscle.^{1,2} While all compartments can be affected in CCS, the ones most commonly involved are the anterior (40% to 70%) and deep posterior compartments (15% to 30%).^{1,2,3}

Though the debate over CCS pathophysiology is unresolved, most clinicians agree that symptoms are due to local ischemia. Exercise increases muscle volume by 20% secondary to increased blood volume and interstitial edema.⁴ Some individuals are unable to accommodate this extra volume and exhibit a corresponding increase in intracompartmental pressure. Elevated compartment pressure impairs capillary blood flow, resulting in tissue ischemia and the characteristic symptoms of CCS.

Explanations for why certain individuals are unable to tolerate this exercise-induced increase in muscle volume include abnormally thickened or stiff fascia, muscle hypertrophy, local scarring secondary to a soft tissue injury,⁵ and venous hypertension.^{1,2} This hypertension can result from a Baker's cyst, a DVT, or use of an excessively tight-fitting knee brace.⁶

ILLUSTRATION BY JENNIFER FAIRMAN

FAST TRACK

Though the debate is unresolved, most clinicians agree that the symptoms of CCS are due to local ischemia

(slap sign). Less often, patients with CCS report a severe shooting pain.

Symptoms usually resolve within minutes to hours following the cessation of activity. However, they can linger for 1 to 2 days following intense activity, especially when the athlete continues to participate despite symptoms.³

Symptoms follow regular pattern. While the onset of symptoms can vary among CCS sufferers, patients often note that symptoms recur consistently at a specific distance (if running or cycling) or duration of exercise.⁷ Temporary rest from or complete cessation of the associated activity may relieve symptoms, but a return to full participation inevitably leads to more severe symptoms. Those who ignore symptoms and continue their activity may over weeks or months experience a worsening in severity and an earlier onset of symptoms.²

Clinical exam much less helpful than

the history. With most patients who have CCS, the exam is completely normal. In fact, the real value of the exam may be to detect signs associated with other disorders in the differential (**TABLE**).

However, occasionally positive findings support the diagnosis of CCS. The finding most commonly encountered is muscle herniation, seen in 40% to 50% of patients.^{7,8} These hernias result from a defect in the overlying fascia and are evidenced by a soft tissue bulge that becomes more prominent with muscle contraction. Hernias can be tender to palpation or asymptomatic.²

Another finding, in the absence of herniation, is tenderness of the affected area when palpated. Less frequently, the examiner may note swelling or tightness over the affected compartment.

A few patients with anterior or lateral compartment syndromes have significant weakness on dorsiflexion.^{2,8}

CONTINUED

Examining the patient immediately after exercise may increase the sensitivity of all tests for abnormal sensations and weakness.

■ Rule out other disorders early

Since confirmatory testing for CCS is invasive, rule out alternative diagnoses before proceeding with the work-up. Two much more common diagnoses in young athletes are shin splints and stress fractures. Diffuse tenderness along the posteromedial aspect of the tibia suggests *shin splints*. Point tenderness along the anterior or posteromedial tibia suggests a *stress fracture*.

Another common diagnosis to consider in all age groups is *disk herniation*. Concomitant low back pain or pain that radiates from above the knee in a dermatomal distribution makes this diagnosis more likely. In older patients, *spinal stenosis* can cause radicular pain that must be distinguished from CCS. A thorough neurologic examination is imperative to rule out these conditions.

Also consider *claudication* with older patients, particularly those who have risk factors for peripheral vascular disease.

Peripheral neuropathy and *gastrocnemius/soleus strain* are other common diagnoses that are part of the differential. Uncommon yet important diagnoses to consider include *osteomyelitis* and *tumor*.

Rare disorders

Though much less common than the above diagnoses, popliteal artery entrapment syndrome (PAES) and peroneal nerve entrapments are important to discuss since their presentations can be almost identical to CCS.

PAES can mimic posterior CCS in presentation and should be part of the differential for any young patient complaining of exertional calf pain. PAES is a rare condition in which the popliteal artery becomes compressed from strenuous exercise, resulting in ischemia. The underlying anatomic anomaly is the relationship of

TABLE 1

Differential diagnosis for chronic compartment syndrome

| |
|--------------------------------------|
| Shin splints |
| Stress fracture |
| Gastrocnemius/Soleus strain |
| Claudication |
| Disk herniation |
| Spinal stenosis |
| Peripheral neuropathy |
| Popliteal artery entrapment syndrome |
| Peroneal nerve entrapments |
| Osteomyelitis |
| Tumor |

the popliteal artery to the adjacent musculotendinous structures.⁹ If you suspect PAES, evaluate for a diminished dorsalis pedis pulse with either passive plantar flexion or active dorsiflexion. Patients with exertional calf pain and a positive test result require imaging. These patients should undergo Doppler imaging at rest, with passive plantar flexion, and with active dorsiflexion. Equivocal or incomplete studies require arteriography.¹⁰

Similarly, peroneal nerve entrapments can masquerade as anterior/lateral compartment syndromes. While the common, deep, and superficial peroneal nerves can all be entrapped, the superficial branch is most frequently involved.¹¹ The superficial branch exits the lateral compartment approximately 10 cm proximal to the lateral malleolus. Tenderness at this site upon active dorsiflexion, a positive tinel sign at this site, or lateral leg pain upon plantar flexion and inversion all suggest superficial peroneal entrapment.¹¹ Electromyography, oftentimes performed after compartment pressures are found to be normal, is necessary to confirm the diagnosis.

FAST TRACK

Most patients with CCS have normal clinical exams; an exam's real value is to detect signs associated with other disorders

APPLIED EVIDENCE

A profile of chronic compartment syndrome

Chronic compartment syndrome was first identified by Mavor in 1956,¹² but it was not until 1975 that the disorder's clinical manifestations and basic pathophysiology were described.¹³ CCS is an uncommon condition and no published data exist regarding its incidence or prevalence. However, because more physicians are becoming aware of it, CCS is being increasingly recognized. At the University of Wisconsin, the number of patients diagnosed with CCS has more than tripled in each of the last 2 decades.^{1,2}

Athletes most affected. CCS, also known as *exertional compartment syndrome* or *effort-related compartment syndrome*, affects primarily young athletes. The mean age of afflicted persons at the time of diagnosis is mid to late twenties. The average duration of symptoms before diagnosis is 2 years.¹ The syndrome most commonly affects runners and soccer players, but other sports linked to the development of CCS are cycling, football, gymnastics, and tennis.^{1,2,3,7} Although the syndrome most commonly affects the lower extremities, many reported cases of CCS have occurred in the forearms and hands.

Young women may be most at risk. Early studies from the United States in the mid-1980s showed that the male to female ratio of affected patients was approximately 1:1.^{2,8} However, a large, more recent study showed a female-to-male ratio greater than 2:1.¹ This likely reflects the increase in female sports participation over the last 2 decades and suggests that females may be at a greater risk of developing the syndrome.

■ Direct pressure measurement best evaluation

Despite attempts to develop noninvasive testing for CCS, the gold standard remains the direct measurement of intracompartmental pressures. There is some controversy regarding the upper limit of normal, but most authors agree that a resting pressure >15 mm Hg is abnormally elevated.^{1,2,5} Other cutoffs cited in the literature include a 1-minute post-exercise value greater than 30 mm Hg, and a 5-minute post-exercise reading >25 mm Hg.⁵ Turnipseed and colleagues recommend checking post-exercise values in patients with modestly elevated resting pressures of 16 to 24 mm Hg to confirm the diagnosis. Because of the pathophysiology of the syndrome, it seems

appropriate to also check 5- or 10-minute post-exercise pressures in patients with typical clinical presentations and normal resting pressures.

Orthopedic, vascular, and general surgeons receive training in compartmental pressure measurement. There are 4 techniques for measurement: the simple needle, the Whitesides infusion, the wick catheter, and the slit catheter. Simple needle devices (such as the Stryker stic, **FIGURE 2**) have increased in popularity because they are handheld, portable, contain a scale within the device for direct measurement, and are easily operated in a clinic setting.¹⁴

Diagnostic tools that may yet prove useful

Many other diagnostic modalities have been studied in the last 10 years and may eventually prove helpful. Near-infrared spectroscopy has demonstrated a relative deoxygenation during exercise in CCS patients and a delayed reoxygenation in the immediate post-exercise period.¹⁵

MIBI scintigraphy has shown decreased muscle perfusion at peak exercise when compared with next-day imaging.^{16,17}

Laser Doppler flow studies conducted in the post-exercise period have demonstrated a delayed peak hyperemia in CCS patients, different from the gradual decrease in blood flow seen in controls.¹⁸

Finally, multiple studies have been conducted done with magnetic resonance imaging. Comparisons of pre- and post-exercise imaging have shown a greater increase in signal intensity in patients with CCS.¹⁹ Despite these findings, though, no clear clinical indications for these tools exist.

■ Treatment options Conservative measures unconvincing

A few studies have addressed the efficacy of conservative treatment of CCS, but most physicians have found such therapy unsuccessful. Modalities tried include nonsteroidal anti-inflammatory drugs

(NSAIDs), diuretics, compression, stretching, orthoses, massage, prolonged rest, change in training surface, change in footwear, change in sport, heat, electrostimulation, and whirlpool.²⁰

One small study showed that compartment pressures in middle-aged men with CCS decreased following treatment with diuretics.²¹ Another small study showed that athletes receiving compartmental massage increased the duration of time they were able to exercise before developing symptoms.²² A third trial found competitive runners to have significantly higher pressures than competitive cyclists, suggesting runners with CCS may be able to bike as an alternative form of exercise.²³

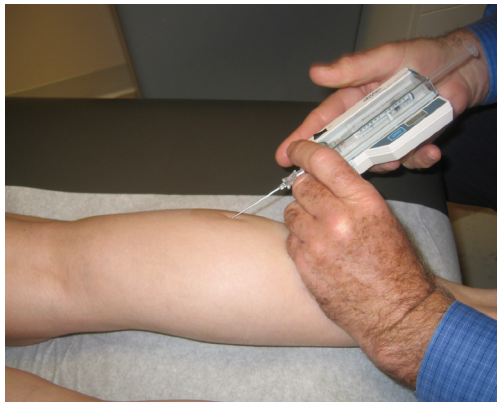The few data regarding other modalities suggests that only prolonged rest or cessation of sport is effective.^{24,25} These options, however, may be impractical for competitive athletes who often have no desire to modify their sports participation. With little available evidence, the decision to offer conservative treatment and the type of conservative therapy to recommend remain controversial.

Fasciotomy track record good

Fasciotomy is the most widely used surgical treatment for CCS. The surgeon makes 1 to 3 small skin incisions, exposes the underlying fascia of the affected compartment, and incises the fascia (**FIGURES 3 AND 4**). Most of these operations are performed under local anesthesia and last less than an hour. Complications are rare, but can include seroma, hemorrhage, cellulitis, peripheral nerve injury, popliteal injury, tibial artery injury, and deep vein thrombosis (DVT).^{1,2}

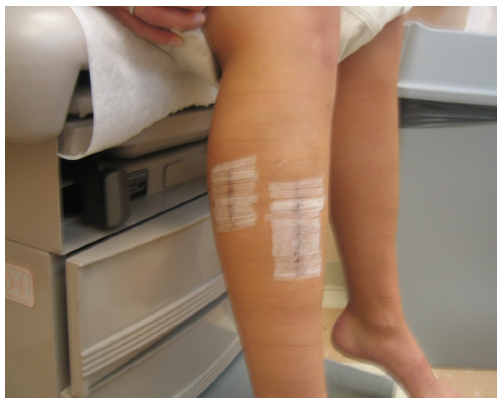Patient satisfaction with the operation ranges from 80% to 95% in most published series.^{1,2,3,5,26} The typical postoperative course involves crutches for the first few days, followed by nonimpact aerobic training for 2 to 4 weeks. Impact aerobic training is next, with gradual return to sport by 2 to 3 months depending on the intensity of sports participation and type of sport practiced.^{1,4}

FIGURE 2 Measurement with Stryker stic



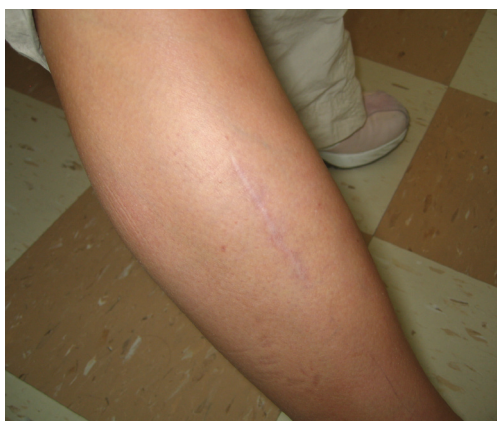Measurement of lateral superficial posterior compartment pressure with the Stryker stic on a 16-year-old girl with 4-month history of exertional calf pain.

FIGURE 3 5 days postsurgery



21-year-old female collegiate track athlete 5 days after anterior, lateral, and lateral superficial posterior compartment release.

FIGURE 4 6 months later



16-year-old female hockey and soccer player 6 months after anterior and lateral fasciotomy.

FAST TRACK

Intracompartmental pressure measurement is the gold standard of diagnosis—resting pressure >15 mm Hg is abnormally elevated

APPLIED EVIDENCE

Fasciotomy preferred by some. Though published long-term follow-up data are few, Turnipseed et al found an 11% CCS recurrence rate among patients undergoing fasciotomies before 1985, compared with a 6% recurrence among patients who received fasciectomy between 1991 and 2001.¹ The latter procedure involves excision of strips of fascia, which theoretically should decrease the risk of scarring over the compartment and subsequent recurrence of symptoms. This is one reason fasciectomy has become the procedure of choice for some physicians, while others reserved it for patients with recurrent CCS. Until a randomized study is performed, it will be difficult to compare the efficacy of fasciotomy and fasciectomy. ■

ACKNOWLEDGMENTS

The author would like to thank Dr. William Turnipseed, MD, Department of Vascular Surgery, University of Wisconsin, for his assistance in the preparation of this review article.

CONFLICT OF INTEREST

The author has no conflicts of interest to declare.

REFERENCES

- Turnipseed WD. Diagnosis and management of chronic compartment syndrome. *Surgery* 2002; 132:613-619.
- Detmer DE, Sharpe K, Sufit RL, Girdley FM. Chronic compartment syndrome: diagnosis, management, and outcomes. *Am J Sports Med* 1985; 13:162-170.
- Mavor GE. The anterior tibial syndrome: a chronic form. *J Bone Joint Surg Br* 1956; 38:513-517.
- Reneman RS. The anterior and lateral compartment syndrome of the leg due to intensive use of muscles. *Clinic Orthop Relat Res* 1975; 113:69-80.
- Pedowitz RA, Hargens AR, Murbarak SJ, Gershuni DN. Modified criteria for the objective diagnosis of chronic compartment syndrome of the leg. *Am J Sports Med* 1990; 18:35-40.
- Hargens AR, Mubarak SJ. Current concepts in the pathophysiology, evaluation, and diagnosis of compartment syndrome. *Hand Clin* 1998; 14:371-383.
- Jerosch J, Castro WHM, Hoffstetter R, Reer R. Secondary effects of knee braces on the intracompartmental pressure in the anterior tibial compartment. *Acta Orthop Belg* 1995; 61:37-42.
- Moeyersoons JP, Martens M. Chronic compartment syndrome: diagnosis and management. *Acta Orthop Belg* 1992; 58:23-27.
- Martens MA, Moeyersoons JP. Acute and recurrent effort-related compartment syndrome in sports. *Sports Med* 1990; 9:62-68.
- Adams MT, Wixon CL. Popliteal artery entrapment syndrome. *J Am Coll Surg* 2003; 196:152-153.
- Allen MJ, Barnes MR, Bell PR, Bolia A, Hartshorne TC. Popliteal entrapment syndrome: misdiagnosed as a compartment syndrome. *Eur J Vasc Surg* 1993; 7:342-345.
- DeLee J, Drez D, Miller MD. *DeLee and Drez's Orthopaedic Sports Medicine*. 2nd ed. Philadelphia, Pa: WB Saunders; 2003:2177-2178.
- Heppenstall RB. An update in compartment syndrome investigation and treatment. *Univ Penn Ortho J* 1997; 10:49-57.
- Mohler LR, Styf JR, Pedowitz RA, Hargens AR, Gershuni DH. Intramuscular deoxygenation during exercise in patients who have chronic anterior compartment syndrome of the leg. *J Bone Joint Surg Am* 1997; 79:844-849.
- Edwards PD, Miles KA, Owens SJ, Kemp PM, Jenner JR. A new non-invasive test for the detection of compartment syndromes. *Nuc Med Commun* 1999; 20:215-218.
- Owens S, Edwards P, Miles K, Jenner J, Allen M. Chronic compartment syndrome affecting lower limb: MIBI perfusion imaging as an alternative to pressure monitoring: two case reports. *Br J Sports Med* 1999; 33:49-53.
- Abraham P, Leftheriotis G, Saumet JL. Laser Doppler flowmetry in the diagnosis of chronic compartment syndrome. *J Bone Joint Surg Br* 1998; 80:365-369.
- Verleisdonk EJ, van Gils A, van der Werken C. The diagnostic value of MRI scans for the diagnosis of chronic exertional compartment syndrome of the lower leg. *Skeletal Radiol* 2001; 30:321-325.
- Micheli LJ, Solomon R, Solomon J, Plasschaert VF, Mitchell R. Surgical treatment for lower-leg compartment syndrome in young female athletes. *Am J Sports Med* 1999; 27:197-201.
- Christensen JT, Eklof B, Wulff K. The chronic compartment syndrome and response to diuretic treatment. *Acta Chir Scand* 1983; 149:249-252.
- Blackman PG, Simmons LR, Crossley KM. Treatment of chronic exertional anterior compartment syndrome with massage: a pilot study. *Clin J Sport Med* 1998; 8:14-17.
- Beckham SG, Grana WA, Buckley P, Breazile JL, Claypool PL. A comparison of anterior compartment pressures in competitive runners and cyclists. *Am J Sports Med* 1993; 21,1:36-40.
- Shah S, Miller B, Kuhn J. Chronic exertional compartment syndrome. *Am J Orthop* 2004; 33:335-341.
- Martens MA, Backaert M, Vermaut G, Mulier JC. Chronic leg pain in athletes due to recurrent compartment syndrome. *Am J Sports Med* 1984; 12:148-151.
- Tubb CC, Vermillion D. Chronic exertional compartment syndrome after minor injury to the lower extremity. *Mil Med* 2001; 166:366-368.
- Styf J, Korner L. Chronic anterior-compartment syndrome of the leg. Results of treatment by fasciotomy. *J Bone Joint Surg Am* 1986; 68:1338-1347.