

Joel J. Heidelbaugh,
MD, FFAFP;
Mikel Llanes, MD;
William J. Weadock, MD

Departments of Family
Medicine
(Drs. Heidelbaugh and
Llanes), Urology
(Dr. Heidelbaugh), and
Radiology (Dr. Weadock),
University of Michigan
Medical School,
Ann Arbor

jheidel@umich.edu

*The authors reported no
potential conflict of interest
relevant to this article.*



**TESTICULAR
PAIN
TREATMENT
TIPS**

JOEL J. HEIDELBAUGH,
MD, FFAFP

An algorithm for the treatment of chronic testicular pain

Exhaust conservative medical therapy prior to considering surgical options, using this algorithm as your guide.

PRACTICE RECOMMENDATIONS

- › Order ultrasound of the scrotum and testes to evaluate chronic testicular pain, with color Doppler to identify areas of hypervascularity. **C**
- › Treat suspected epididymitis with empiric coverage for chlamydia with either a 10-day regimen of doxycycline (100 mg twice daily) or a single dose (1 g) of azithromycin; treat suspected gonorrhea with a single intramuscular injection (125 mg) of ceftriaxone. **A**
- › Do not treat small epididymal cysts that do not correlate with testicular pain; larger, painful cysts can be aspirated, injected with a sclerosing agent, or surgically excised. **C**
- › Consider surgical options only after medical and conservative therapies have failed to alleviate chronic testicular pain. **C**

Strength of recommendation (SOR)

- A** Good-quality patient-oriented evidence
- B** Inconsistent or limited-quality patient-oriented evidence
- C** Consensus, usual practice, opinion, disease-oriented evidence, case series

CASE 1 ▶ Vincent B, a 33-year-old executive, visits his family physician for an evaluation of chronic orchialgia. Although his testicular pain has waxed and waned for several years, it has recently worsened, making it increasingly difficult for him to exercise or to sit for extended periods of time. In fact, this visit was prompted by a lengthy meeting during which he developed a “dull ache” that did not let up until he left the meeting and walked around.

CASE 2 ▶ Jason H, a 42-year-old married father of 3 who had a vasectomy 2 years ago, has had progressively worsening testicular pain ever since. He also has occasional pain after ejaculation, but no known hematospermia. Recently, the pain has become so bad that it limits both his physical and sexual activities and is having a negative effect on his relationship with his wife. Jason is sexually monogamous, has no significant medical history, and takes no prescription medications.

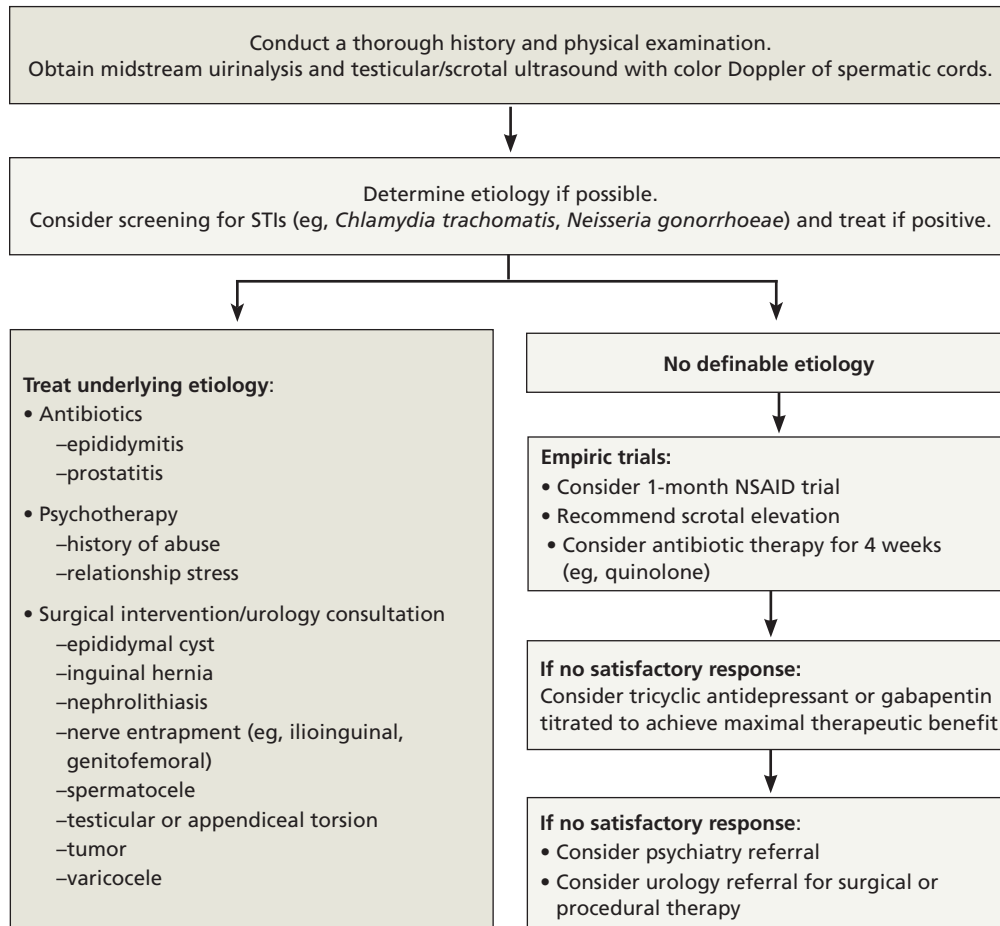
These 2 cases are based on actual patients we have seen in our practices. If Vincent and Jason (not their real names) were your patients, how would you initiate a work-up for testicular pain? What treatments would you offer? And at what point would you consider a referral to a urologist?

Chronic orchialgia is a complex urogenital focal pain syndrome in which neurogenic inflammation is the principal mediator. This debilitating condition is associated with substantial anxiety and frustration, and is characterized by intermittent or constant unilateral or bilateral testicular pain, occurring for at least 3 months, that has a significant negative impact on activities of daily living and physical activity.¹

A variety of procedural and surgical options may help to minimize or alleviate chronic orchialgia. But which approach is best? There are no evidence-based guidelines for the treatment of this condition, and no randomized controlled trials to

FIGURE 1

Chronic orchialgia: A diagnosis and treatment algorithm^{1,3,4,6,10}



NSAID, nonsteroidal anti-inflammatory drug; STIs, sexually transmitted infections.

>
In about 25% of cases of chronic orchialgia, no cause is found.

demonstrate the superiority of 1 modality over another. All diagnostic and treatment recommendations are based on expert opinion derived from small cohort studies.

With that in mind, we conducted a systematic review of the literature evaluating medical and surgical therapies for chronic testicular pain—and developed an algorithm (FIGURE 1), along with the text and TABLE that follow, for family physicians (FPs) to use as a guide.

CASE 1 ▶ Vincent B

Over the last few years, Vincent has had similar episodes of bilateral testicular pain. He denies any history of direct trauma to the testicles, and he works out regularly by lifting weights and running. When the pain be-

comes unbearable, he takes acetaminophen or ibuprofen and takes a few days off from exercising, which provides modest—but temporary—relief.

Vincent reports that he has had about a dozen lifetime sexual partners and had chlamydia over a decade ago as a college student. He is currently engaged and sexually monogamous, and tested negative for *Chlamydia trachomatis*, *Neisseria gonorrhoeae*, hepatitis, syphilis, and human immunodeficiency virus (HIV) at his annual health maintenance examination last month. Shortly before that, Vincent was treated empirically for epididymitis with a 4-week course of ciprofloxacin, with no significant improvement in symptoms. He has no significant past medical history,

TABLE
Causes of acute and chronic orchialgia^{1,3,4}

<p>Acute</p> <ul style="list-style-type: none"> • Acute appendicitis • Epididymitis • Inguinal hernia, strangulated • Lumbosacral radiculopathy • Orchitis (eg, mumps) • Testicular cancer • Testicular torsion/torsion of the appendix testis • Trauma
<p>Chronic</p> <ul style="list-style-type: none"> • Diabetic neuropathy • Epididymal cyst/spermatocele • Epididymitis <ul style="list-style-type: none"> –Infectious (eg, <i>Chlamydia trachomatis</i>, <i>Neisseria gonorrhoeae</i>, <i>Ureaplasma urealyticum</i>, coliform bacteria) –Noninfectious (eg, reflux of urine) • Fournier’s gangrene • Gout • Henoch-Schönlein purpura • Herniated lumbar disc • Hydrocele • Idiopathic swelling • Inguinal hernia • Interstitial cystitis • Nephrolithiasis in the mid-ureter • Orchitis (eg, mumps) • Polyarteritis nodosa • Previous surgical interventions • Prostatitis • Psychogenic (eg, history of sexual abuse, relationship stress) • Referred pain from abdomen/pelvis due to entrapment of genitofemoral or ilioinguinal nerve roots • Testicular cancer • Testicular vasocongestion from sexual arousal without ejaculation • Torsion/torsion of the appendix testis • Trauma • Varicocele • Vasectomy (postvasectomy pain syndrome)

denies depression, and takes no prescription medications.

Physical examination reveals mild to moderate diffuse tenderness to palpation throughout the scrotum, including both testicles and spermatic cords. There is no erythema of the scrotum. Nor are there any palpable scrotal masses, varicoceles, or hydroceles; testicular, scrotal, or penile lesions; inguinal masses; or lymph nodes. His urethral meatus is patent. The prostate is smooth, nonnodular, and nontender. The remainder of the physical exam is unremarkable.

Determining a cause can be a challenge

There are numerous possible causes of testicular pain (TABLE), including an inguinal hernia, torsion of the testicle, trauma, and a history of chlamydia or gonorrhea, to name a few.

Chronic testicular pain can also be psychogenic, often relating to a history of sexual abuse or relationship stress. One study examining comorbid psychological conditions in men with chronic orchialgia identified a somatization disorder in 56% of the patients, nongenital chronic pain syndromes in 50%, and major depression or chemical dependency in 27%.² Overall, however, estimates suggest that in about 25% of patients with chronic orchialgia, no identifiable etiology is found.¹

Establish a baseline with a physical exam

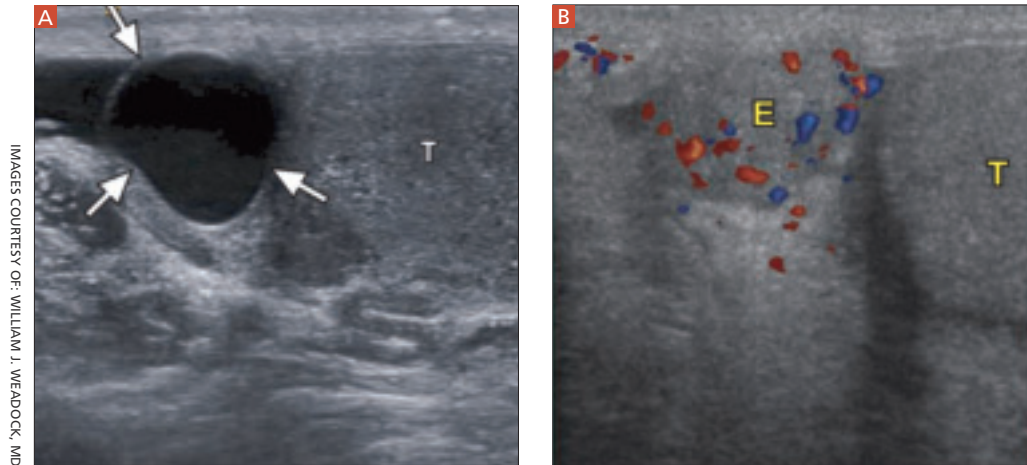
Conduct a physical examination of the scrotum, testes, spermatic cords, penis, inguinal region, and prostate as a baseline measurement in a patient who presents with chronic orchialgia.^{3,4} An initial urinalysis should be performed to rule out infection or identify microscopic hematuria, which may prompt a more targeted work-up and therapeutic plan. Take a thorough medical and psychosocial/sexual history, as well.

■ **Order an ultrasound of the scrotum and testes**, the accepted gold standard to highlight structural abnormalities of the testicles. The addition of color Doppler makes it possible to find areas of hypervascularity, an indication of inflammation in the testicle and epididymis (FIGURES 2A AND B).

Epididymal cysts are common findings

FIGURE 2

Well-circumscribed extratesticular mass



IMAGES COURTESY OF: WILLIAM J. WEADOCK, MD

In the image at left, ultrasound reveals an anechoic mass (arrows), representing either an epididymal cyst or spermatocele, superior to the testicle (T). A color Doppler image (right) reveals increased vascularity to the epididymis (E), as compared with the testicle.

on scrotal ultrasound; they are frequently incidental, but may relate to the patient's pain, depending on the size of the cyst. Smaller cysts that do not correlate with pain do not require treatment. Larger, painful cysts can be treated with aspiration or injection with a sclerosing agent—or with surgical excision, which offers the highest potential cure rate.^{3,4} A computed tomography (CT) scan without contrast is the best way to find genitourinary system calculi, which could be the source of referred renal pain to the groin and scrotum. A contrast-enhanced CT is best to evaluate for solid renal masses.

Start with the most conservative treatment

In the absence of any findings that require surgical intervention, start conservatively.

■ **Initiate a trial of nonsteroidal anti-inflammatory drugs (NSAIDs)** for at least 1 month. Although this is the standard first-line treatment, NSAIDs have been shown to help only a small percentage of patients with chronic orchialgia, and only on a short-term basis.^{1,3,4}

■ **Recommend scrotal elevation with supportive undergarments** to decrease venous congestion. Tell the patient, too, that modifying his seated posture to avoid scrotal pressure may alleviate pain and poses no discernible risk of worsening orchialgia.⁵

■ **Treat suspected STIs.** The Centers for Disease Control and Prevention report that in men 14 to 35 years of age, epididymitis is most commonly caused by chlamydia or gonorrhea.⁶ In males younger than 14 or older than 35, epididymitis is most commonly caused by urinary coliform pathogens, including *Escherichia coli*.

If epididymitis is suspected to be due to chlamydia or gonorrhea, treatment should include either doxycycline 100 mg orally twice daily for 10 days *or* a single dose of azithromycin 1 g orally (for chlamydia eradication) *and* a single dose of ceftriaxone 125 mg intramuscularly (for gonorrhea eradication).^{6,7} If coliform bacteria is suspected, order a standard dose of a quinolone (eg, ciprofloxacin or levofloxacin 500 mg/d) for 10 days.⁶ For refractory cases, treatment with a standard dose of a quinolone for 4 weeks is recommended.⁶

It is generally reasonable to treat most patients empirically for suspected epididymitis with antibiotics if no other identifiable etiology can be determined. Multiple antibiotic treatments should be avoided, however, in the absence of either an identifiable urogenital infection or ultrasound findings consistent with epididymitis (eg, congestion and enlargement). Antibiotics have not been shown to decrease the severity of chronic orchialgia and their use, unless clearly indicated, may lead to drug resistance.³



Epididymal cysts are commonly found on scrotal ultrasound; most small cysts that do not correlate with pain do not require treatment.

CONTINUED

>
Up to 43% of men who undergo vasectomy develop postvasectomy pain syndrome; the specific reason is unknown.

Consider a tricyclic antidepressant or gabapentin

Both tricyclic antidepressants (TCAs) and gabapentin have demonstrated benefit in the treatment of chronic pelvic and neuropathic pain.^{8,9} Doses should be titrated to achieve a maximal therapeutic benefit while avoiding anticholinergic and neurologic side effects.

A cohort study using a multidisciplinary team consisting of a psychologist, an anesthetist, a physiotherapist, and an occupational therapist found >50% symptomatic improvement in 62% of men with chronic orchialgia treated with gabapentin up to 1800 mg per day, and 67% of men treated with nortriptyline up to 150 mg per day.¹⁰ However, a subgroup of patients who reported postvasectomy testicular pain did not achieve a 50% symptomatic improvement rate with either TCA or gabapentin therapy.

CASE 1 ▶ Vincent B

The FP reassured Vincent that his physical examination was normal and recommended a 1-month trial of ibuprofen (600 mg every 6 hours), and regular use of supportive briefs. Since the patient had been treated with antibiotics in the past with no change in symptoms—and because he was thought to be at low risk for an STI—the physician did not prescribe another empiric trial of antibiotics. He did send the patient for an ultrasound evaluation of the scrotum and testes, which revealed only a 0.5 x 0.4 x 0.6-cm right epididymal cyst that was not palpable on examination.

The patient returned after 1 month, noting that his symptoms had neither improved nor worsened. The FP suggested that he stop taking the ibuprofen and begin a trial of gabapentin 100 mg daily, titrating up to 3 times daily for the first month, then to 300 mg 3 times daily in the second month.

When he returned 3 months later, Vincent reported that his symptoms had improved by about 50%. He has since been able to increase both the intensity and frequency of physical activity. Vincent is not interested in further increasing the dose of gabapentin and declined a referral to a urologist for consideration of procedural and surgical therapeutic options, but agreed to follow up as needed if his testicular pain worsened.

Postvasectomy pain is not unusual

Several years after a vasectomy, the diameter of a man's ejaculatory ducts often doubles in size to counteract the increase in fluid pressure.¹¹ The specific cause of long-term postvasectomy pain syndrome, or congestive epididymitis, is unknown, but has been reported in 5% to 43% of men who have undergone this procedure.¹²⁻¹⁴ Sperm granulomas or spermatoceles represent the body's effort to spare the testicle from damage secondary to increasing fluid pressure. While these granulomas are benign lesions, their presence may predispose a man to postvasectomy pain syndrome.¹⁵⁻¹⁷

CASE 2 ▶ Jason H

Two months before Jason's visit to the FP, his testicular pain had become so excruciating that he went to the ED seeking treatment. He was given an ultrasound with color Doppler and found to have postvasectomy surgical changes consistent with bilateral spermatoceles, but no evidence of epididymitis or a mass. Before leaving the ED, Jason received ceftriaxone (125 mg IM) as gonorrhea prophylaxis. He was discharged home with prophylactic antibiotics for chlamydia, as well as ibuprofen. He was advised to avoid strenuous physical activity and told to follow-up with his FP if his symptoms did not improve.

During several months of conservative medical therapy, including trials of NSAIDs, quinolone antibiotics, TCAs, and gabapentin, Jason did not experience any significant pain relief. He was frustrated by the dull, aching pain in his scrotum that continued to limit his physical and sexual activities.

Finally, the FP recommended a urologic consultation.

Consider these minimally invasive procedures

When conservative medical management fails, minimally invasive techniques are the next step. There are 2 commonly used procedures, both of which can be performed by a urologist in an outpatient setting.

■ **Spermatic cord blocks** with lidocaine and methylprednisolone have been shown to provide relief for weeks up to several months in small case studies, and may be repeated

at intervals of several months if modest relief is achieved.^{18,19}

■ **Transrectal ultrasound-guided periprostatic anesthetic injections**, another microinvasive option, offers minimal risk and may provide some short-term relief. However, data on long-term benefit and resolution of pain and disability are lacking.²⁰

Consider surgery only after all else fails

If all medical and conservative therapies have been tried and the patient continues to have debilitating pain, surgical options should be considered. Because current surgical therapies are not always effective and are not reversible (and research on the various options is limited), it is important to initiate a detailed discussion with the patient. Such conversations should be held in consultation with a urologist.

Highlight risks and benefits and provide realistic expectations of short- and long-term postsurgical outcomes. It is also important to address psychological factors and social stressors that often contribute to chronic pelvic pain syndromes, which can improve long-term outcomes regardless of the chosen treatment. For this reason, a referral to a psychiatrist may be indicated.

■ **Microsurgical denervation of the spermatic cord.** Removal of the afferent nerve stimulus to the testicle is believed to result in the downregulation of the peripheral and central nervous systems, so the patient no longer has the perception of testicular pain. Several small trials have yielded favorable symptomatic pain relief scores in up to 71% of patients, with reported adverse outcomes including rare testicular atrophy—but no complaints of hypoesthesia or hyperesthesia of the scrotum, penile shaft, inguinal, or medial thigh skin.^{21,22} This treatment should be considered only in patients who have experienced a significant degree of temporary relief from spermatic cord injection.

■ **Epididymectomy is recommended only when pain is localized** to the epididymis, as this is a testicle-sparing procedure. Unilateral or bilateral epididymectomy is a viable option for the treatment of chronic orchialgia related to postvasectomy pain syndrome or chronic epididymitis. Reports highlighting symptomatic improvement based on small case series range from 43% to 74%, with the highest success rate found during a 5½-year follow-up.²³⁻²⁵ In 1 study, 90% of patients reported that they were satisfied with their choice to undergo the procedure.²⁵

■ **Vasectomy reversal (vasovasostomy) and inguinal or scrotal orchiectomy** should be considered only after all other treatment modalities have failed. Vasovasostomy has the potential to restore fertility in up to 98% of cases,²⁶ which may or may not be desirable. One study of men who experienced postvasectomy pain syndrome and underwent microsurgical vasovasostomy found that after nearly 2½ years, 84% experienced complete pain resolution.²⁷

The goal of orchiectomy is to relieve orchialgia by releasing the entrapped ipsilateral genitofemoral and/or ilioinguinal nerves. One study determined that 90% of men who underwent unilateral epididymectomy for chronic orchialgia required an orchiectomy to resolve pain.¹ Another study found that 80% of patients continued to suffer both short- and long-term debilitating orchialgia postorchiectomy.²⁸

CASE 2 ▶ Jason H
Jason saw a urologist, who initially offered him bilateral spermatic cord blocks. They provided Jason with moderate symptom relief on most days of the week and allowed him to increase his physical and sexual activities. Three months later, Jason went back to the urologist for evaluation because he felt that the effects of the spermatic cord blocks had worn off. In the next 6 months, he had 2 additional bilateral blocks.

Nearly a year after a series of spermatic cord blocks, most of it spent in persistent discomfort, Jason returned to his FP with a request for narcotic pain medication. The FP tried to be supportive, but told Jason that chronic narcotic therapy was not an ideal choice—and referred him back to the urologist to discuss surgical options.

The urologist recommended a bilateral epididymectomy and the patient, who was desperate to obtain some pain relief and now

➤ **Denervation of the spermatic cord should be considered only for patients who have experienced temporary relief from spermatic cord injection and have tried all conservative measures.**

regretted undergoing a vasectomy, agreed. Within the first few weeks after his surgery, he noticed a reduction in pain, and he slowly increased his physical activity. A year later, Jason reported only minimal testicular and scrotal discomfort that did not limit his physical or sex-

ual activities—and he continues to be pleased with the outcome of his treatment. **JFP**

CORRESPONDENCE

Joel J. Heidelbaugh, MD, FAAFP, Ypsilanti Health Center, 200 Arnet, Suite 200, Ypsilanti, MI 48198; jheidel@umich.edu

References

1. Davis B, Noble MJ, Weigel JD, et al. Analysis and management of chronic testicular pain. *J Urol*. 1990;143:936-939.
2. Schover LR. Psychological factors in men with genital pain. *Cleve Clin J Med*. 1990;57:697-700.
3. Masarani M, Cox R. The aetiology, pathophysiology and management of chronic orchialgia. *Br J Urol Int*. 2003;91:435-437.
4. Granitsiotis P, Kirk D. Chronic testicular pain: an overview. *Eur Urol*. 2004;45:430-436.
5. Coogan CL. Painful scrotum. In: Myers JA, Millikan KW, Saclarides TJ, eds. *Common Surgical Diseases*. New York: Springer; 2008:293-295.
6. Centers for Disease Control and Prevention. Sexually transmitted diseases treatment guidelines, 2006. *MMWR Morb Mortal Wkly Rep*. 2006;55(RR-11):1-94.
7. Newman LM, Moran JS, Workowski KA. Update on the management of gonorrhea in adults in the United States. *Clin Infect Dis*. 2007;44(suppl 3):S84-S101.
8. Wiffen PJ, McQuay HJ, Rees J, et al. Gabapentin for acute and chronic pain. *Cochrane Database Syst Rev*. 2005;(3):CD005452.
9. American College of Obstetricians and Gynecologists. Chronic pelvic pain. ACOG Practice Bulletin No. 51. *Obstet Gynecol*. 2004;103:589-605.
10. Sinclair AM, Miller B, Lee LK. Chronic orchialgia: consider gabapentin or nortriptyline before considering surgery. *Int J Urol*. 2007;14:622-625.
11. Jarow JP, Budin RE, Dym M, et al. Quantitative pathologic changes in the human testis after vasectomy. *N Engl J Med*. 1985;313:1252-1256.
12. Choe J, Kirkemo A. Questionnaire-based outcomes study of nononcological post-vasectomy complications. *J Urol*. 1996;155:1284-1286.
13. McMahon A, Buckley J, Taylor A, et al. Chronic testicular pain following vasectomy. *Br J Urol*. 1992;69:188-191.
14. Ahmed I, Rasheed S, White C, et al. The incidence of post-vasectomy chronic testicular pain and the role of nerve stripping (denervation) of the spermatic cord in its management. *Br J Urol*. 1997;79:269-270.
15. Christiansen CG, Sandlow JL. Testicular pain following vasectomy: a review of postvasectomy pain syndrome. *J Androl*. 2003;24:293-298.
16. Shapiro EI, Silber SJ. Open-ended vasectomy, sperm granuloma, and postvasectomy orchialgia. *Fertil Steril*. 1979;32:546-550.
17. Taxy JB, Marshall FF, Erlickman RJ. Vasectomy: subclinical pathologic changes. *Am J Surg Pathol*. 1981;5:767-772.
18. Fuchs E. Cord block anesthesia for scrotal surgery. *J Urol*. 1982;128:718-719.
19. Issa M, Hsiao K, Bassel Y, et al. Spermatic cord anesthesia block for scrotal procedures in the outpatient clinic setting. *J Urol*. 2004;172:2358-2361.
20. Zorn B, Rauchenwald M, Steers WD. Periprostatic injection of local anesthesia for relief of chronic orchialgia. *J Urol*. 1994;151:411A735.
21. Levine LA, Matkov TG, Lubenow TR. Microsurgical denervation of the spermatic cord: a surgical alternative in the treatment of chronic orchialgia. *J Urol*. 1996;155:1005-1007.
22. Strom KH, Levine LA. Microsurgical denervation of the spermatic cord for chronic orchialgia: long-term results from a single center. *J Urol*. 2008;180:949-953.
23. Padmore DE, Norman RW, Millard OH. Analyses of indications for and outcomes of epididymectomy. *J Urol*. 1996;156:95-96.
24. West AF, Leung HY, Powell PH. Epididymectomy is an effective treatment for scrotal pain after vasectomy. *Br J Urol Int*. 2000;85:1097-1099.
25. Siu W, Ohl DA, Schuster TG. Long-term follow-up after epididymectomy for chronic epididymal pain. *Urology*. 2007;70:333-336.
26. Patel SR, Sigman M. Comparison of outcomes of vasovasostomy performed in the convoluted and straight vas deferens. *J Urol*. 2008;179:256-259.
27. Myers SA, Mershon CE, Fuchs EF. Vasectomy reversal for treatment of the post-vasectomy pain syndrome. *J Urol*. 1997;157:518-520.
28. Costabile RA, Hahn M, McLeod DG. Chronic orchialgia in the pain prone patient: the clinical perspective. *J Urol*. 1991;146:1571-1574.

Addressing psychological factors and social stressors that often contribute to chronic pelvic pain syndromes can improve long-term outcomes.

Issues in postmenopausal hormone therapy

DEPRESSION, ENDOMETRIAL HEALTH, AND DISCONTINUATION

**FREE
0.5 CME
CREDIT**

CASE 1 HT and new-onset depression Nanette F. Santoro, MD

CASE 2 Estrogen and endometrial health Veronica A. Ravnkar, MD, FACOG

CASE 3 Discontinuing HT James H. Liu, MD

Both physicians and patients report being confused by conflicting reports of the safety and efficacy of hormone therapy (HT). In this supplement to *Sexuality, Reproduction and Menopause*, 3 experts use case-based evidence to offer suggestions for prescribing HT to postmenopausal women who experience depression or vasomotor symptoms, or who want to discontinue HT.

Available online at <http://www.srm-ejournal.com/srm.asp?id=8035>