

Tam T. Nguyen, MD
San Joaquin General
Hospital Family Medicine
Residency Program,
French Camp, Calif

ttnguyen@sjgh.org

*The author reported no
potential conflict of interest
relevant to this article.*

Acne treatment: Easy ways to improve your care

For patients of any age, facial lesions can cause considerable embarrassment and distress. Read on to discover what key component of acne treatment you should be using (but probably aren't) and which dosage you can safely lower.

PRACTICE RECOMMENDATIONS

- › Use a classification system, such as that of the American Academy of Dermatology, to assess the severity of acne vulgaris. **(A)**
- › Treat inflammatory lesions aggressively to prevent scarring. **(A)**
- › When isotretinoin is indicated, consider prescribing a lower dosage (but longer duration) than the traditional regimen. **(B)**

Strength of recommendation (SOR)

- (A)** Good-quality patient-oriented evidence
- (B)** Inconsistent or limited-quality patient-oriented evidence
- (C)** Consensus, usual practice, opinion, disease-oriented evidence, case series

CASE ► Janis S, an otherwise healthy 19-year-old, is in your office, seeking treatment for acne. She reports she has tried various over-the-counter (OTC) creams in recent months, but has seen little improvement. The acne first appeared about 5 years ago, and her pediatrician prescribed topical adapalene and doxycycline. The treatment helped, but she says her face never fully cleared up; over the past year, the acne has gotten worse.

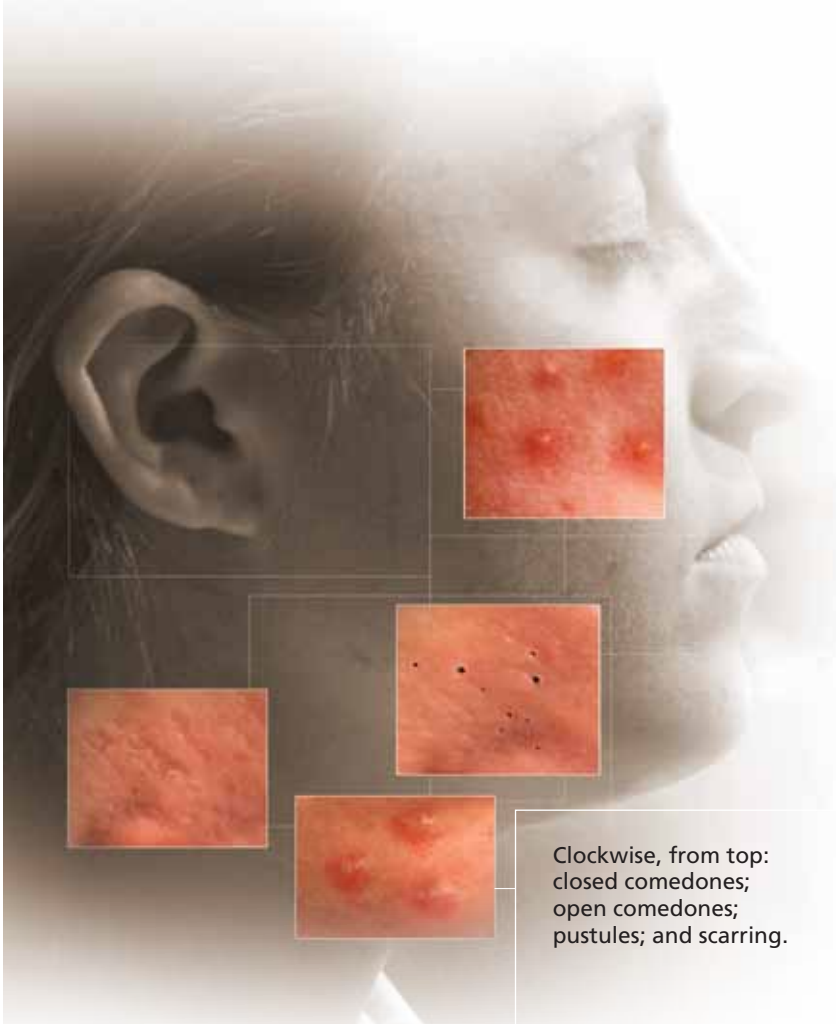
On examination, you find several nodules and comedones on the patient's face, chest, and back. Ms. S confides in you that the acne—particularly on her face—kept her from going to the senior prom.

More than 80% of adolescents and adults develop acne vulgaris at some point in their lives, and in at least 15% to 20% of cases, the acne is moderate to severe.¹ Although acne typically starts in early puberty, it can continue well into adulthood.² Females typically develop acne at an earlier age than males. There are no other sex or racial differences.³

Regardless of the age at which acne develops, it has substantial psychological effects, including embarrassment, shame, depression, anxiety, social isolation—and in extreme cases, suicidal ideation.⁴ This evidence-based update will better prepare you to provide optimal medical therapy—and alleviate patients' emotional distress—without delay.

The pathophysiology of acne vulgaris

The American Academy of Dermatology (AAD) defines acne as a “chronic inflammatory dermatosis which is notable for open and/or closed comedones (blackheads and white-



Because most patients have both inflammatory and bacterial lesions, it is important to use combined therapies to treat *P. acnes* and inflammation.

Clockwise, from top: closed comedones; open comedones; pustules; and scarring.

heads) and inflammatory lesions, including papules, pustules, and nodules...⁵ The underlying etiology is best described as a cascade of events involving the pilosebaceous unit.

Normally, single keratinocytes are shed into the follicular lumen for excretion. In acne, this process is disrupted and the keratinocytes accumulate, becoming interwoven with monofilaments and lipid droplets. The lipids, cellular debris, and excessive sebum, as well as the overgrowth of *Propionibacterium acnes*, block the follicles;⁶ the bacterial overgrowth can generate inflammation, as well.⁷ Areas rich in sebaceous glands, such as the face, neck, chest, upper arms, and back, are the sites at which acne is most likely to develop.

Androgen receptors play a role

For many years, the underlying pathophysiology of acne vulgaris was thought to be lesion progression, with microcomedone formation leading to both closed and open comedones. Emerging evidence has led to a deeper understanding of acne development. Sebum is now known to have androgen receptors (nuclear transcription factor Fox O1), which

are modulated by insulinlike-growth factor 1 (IGF-1) and insulin.^{8,9} Research to determine whether these receptors can be influenced by diet and melanocortins is ongoing.^{8,10}

Evidence has also shown that inflammation around the follicles and follicular differentiation precede bacterial overgrowth,⁷ and that *P. acnes* overgrowth exacerbates the blockage and inflammation by creating a bio-film that plugs the follicles. Inflammation is one of the main complications of acne, causing hyperpigmentation and scarring.

These factors increase the risk

There are numerous risk factors for acne, ranging from genetics to stress to certain medications (TABLE 1).¹¹ Although the exact genetic penetrance is unknown, acne often affects multiple family members;^{1,12} genetics is also associated with an increase in androgens, such as that found in patients with Cushing syndrome, polycystic ovary syndrome (PCOS), and congenital adrenal hyperplasia.¹³

Emotional and physical stress can increase the risk for acne,¹⁴ with the latter often related to excessive friction on the skin caused by sweat bands or helmet strips. Cos-

TABLE 1
**Drugs that are potential
acne triggers**

Common drugs/drug classes
Anabolic steroids (eg, danazol and testosterone)
Bromides and iodides
Corticosteroids (eg, prednisone)
Corticotropin
Isoniazid and ethionamide
Lithium and barbiturates
Phenytoin and trimethadione
Less common drugs
Azathioprine
Cyclosporine
Disulfiram
Phenobarbital
Quinidine

Adapted from: Sterry W, et al. *Dermatology*. Thieme Clinical Companions. 2006.¹¹

metics that plug the follicles are a risk factor for acne, as well.

The patient has acne, but how severe?

Because acne is often diagnosed clinically, there is often no need for routine testing. Nor is a bacterial culture for *P acnes* necessary.

If the patient has signs and symptoms suggestive of an endocrine disorder, however—eg, infertility, PCOS, or hirsutism—consider checking free testosterone, dehydroepiandrosterone sulfate (DHEA), luteinizing/follicle-stimulating hormones (LH/FSH), 17-alpha-progesterone, adrenocorticotrophic hormone (ACTH), and/or dexamethasone suppression. Other indicators of a need for endocrine testing include male or female pattern balding, an abnormal menstrual cycle, acanthosis nigricans, and truncal obesity.^{5,6}

Numerous acne classification systems have been developed; some are based on the type of lesions (ie, comedonal, papulopustu-

lar, nodulocystic), while others also consider the number of each type of lesion and areas affected.¹⁵ In 2002, the US Food and Drug Administration (FDA) defined the components of a Global Acne Severity Scale as having 6 grades (0-5), with 0 for normal skin and 5 representing a predominance of highly inflammatory lesions with a variable number of papules/pustules and nodulocystic lesions.¹⁶

The AAD'S classification system has only 3 grades—mild, moderate, and severe—and is one of the easiest to use:

- **Mild** cases have few to several papules and pustules, but no nodules
- **Moderate** cases have more papules and pustules, with a few nodules
- **Severe** cases have numerous papules, pustules, and nodules.⁵

CASE ► Ms. S is in obvious emotional distress, and her acne needs to be treated aggressively. Because of the emotional impact and the fact that she has lesions on several body parts, her case is classified as severe (and would be even if her face had only a few lesions).

Treatment: Prevention of new lesions is paramount

Preventing new formations is a key focus of acne therapy, and patients should be advised that it may take weeks for results to be seen. Nonetheless, aggressive treatment of inflammatory lesions is necessary to prevent scarring. Because most patients have both inflammatory and bacterial lesions, it is important to use combined therapies, including topical or oral antibiotics, to treat *P acnes* and inflammation (TABLE 2).^{13,17-23}

Topicals are the cornerstone of treatment

Retinoids and benzoyl peroxide topicals are the foundation of therapy for both comedonal and inflammatory acne,¹⁷ regardless of severity. Both are recommended by the AAD. But evidence suggests that only 55% of dermatologists and 10% of primary care providers recommend them.^{19,20}

■ **Retinoids** inhibit microcomedone formation and regulate follicular keratinocytes, which have anti-inflammatory properties and help to prevent the formation of new le-

INSTANT POLL

Do you recommend topical retinoids and benzoyl peroxide for patients with acne?

- Yes, on a routine basis
- Yes, if the acne is moderate to severe
- Only for patients who have not tried topicals previously
- Rarely; I've had more success with other treatments
- Other _____

jfponline.com

sions. Patients should be warned that topical retinoids can cause irritation, erythema, desquamation, pruritus, and burning. To reduce the adverse effects, advise patients to start retinoid therapy slowly, at a reduced frequency (eg, every other day or every third day) and shorter contact (washing it off after one to 4 hours for a week, then increasing the contact time). When it is clear that the medication is well tolerated, the frequency and amount can be increased. Use of the topical, as tolerated, should continue as long as the potential acne problem remains.

There are 3 retinoid formulations on the market—adapalene, tretinoin, and tazarotene—all of which have been shown to be effective. Adapalene is the least irritating and the most stable, and can be safely combined with benzoyl peroxide and topical antibiotics. If tretinoin and benzoyl peroxide are used concurrently, tretinoin should be applied at night and benzoyl peroxide during the day. To reduce the risk of inactivating the topical agents, advise patients not to use other skin products in conjunction with topical therapy.

■ **Benzoyl peroxide**, which is available as a cleanser, gel, or wash, affects keratinocyte dysmaturation, *P acnes*, and inflammation.¹¹ The antibacterial activity is due to its oxidation. Benzoyl peroxide is available both OTC and by prescription, with concentrations ranging from 2% to 10%. Salicylic acid (2%-3%), a well-tolerated keratolytic agent, is often used with benzoyl peroxide, as well. Azelaic acid, sodium sulfacetamide, and dapson are other topicals that have been found to be effective in treating acne.

■ **Topical antibiotics**, most commonly clindamycin 1% or sodium sulfacetamide, also affect both *P acnes* and inflammation,²⁴ although the exact mechanism is unknown. Available in solution or as a gel or lotion, topical antibiotics can be combined with benzoyl peroxide. Use of topical erythromycin has declined in recent years because it has a higher rate of bacterial resistance.^{9,21}

When to add oral antibiotics

When topical treatment does not produce the desired result or cannot be tolerated, oral antibiotics may be introduced, either as an addition or replacement. Like topicals, oral

antibiotics have both antimicrobial and anti-inflammatory properties.

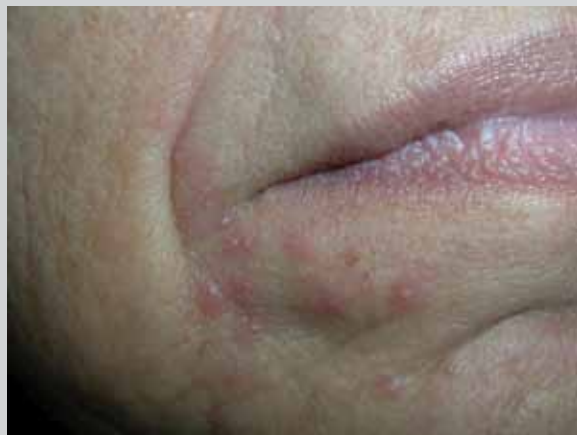Tetracycline antibiotics (ie, doxycycline and minocycline) are first-line oral therapy.²¹ Minocycline has been found to be the most potent agent in this drug class; tetracycline is the least.²² Tetracyclines can cause tooth discoloration and inhibit skeletal growth, and are contraindicated for children younger than 10 years and pregnant women.

Photosensitivity is an adverse effect of tetracycline antibiotics, so patients should be advised to cover up and avoid sun exposure. Other adverse effects, particularly of minocycline, include dizziness, lupus-like syndrome, pseudotumor cerebri, skin and mucosal pigmentation, serum sickness, and hepatitis. If the patient is taking an oral contraceptive pill (OCP) concurrently for family planning, she should be advised that oral antibiotics have the potential to reduce the efficacy of the OCP.

Other oral antibiotics sometimes used to treat acne include erythromycin, trimethoprim-sulfamethoxazole, amoxicillin, and azithromycin, but data on their efficacy are limited. Erythromycin has similar potency to tetracycline, but may need to be taken 2 to 4 times a day and may cause more gastrointestinal disturbances. Cephalosporins,

Diagnostic challenge

Is it acne? Test your skill



Turn the page to check your results

IMAGE COURTESY OF: RICHARD P. USATINE, MD

TABLE 2

Acne classification helps guide treatment decisions^{13,17-23}

Treatment	Severity of acne		
	Mild	Moderate*	Severe*
Dietary/lifestyle modifications (eg, reduce dairy intake, minimize use of cosmetics, reduce stress) PLUS benzoyl peroxide (2%-10%) PLUS retinoid (tretinoin, adapalene, or tazarotene) OR azelaic or salicylic acid	√	√	√
Combined OCPs PLUS oral antibiotics OR topical antibiotics (for males and females who are not candidates for OCPs)		√	√
Isotretinoin [†]			√
Other therapies, as needed (eg, intralesional injections, chemical peels, or laser therapy) [‡]	√	√	√

*Treatments for moderate or severe acne are also appropriate for acne that extends to other parts of the body and/or does not respond to topical therapy.

[†]Monitoring and counseling on adverse effects and teratogenic potential are required.

[‡]Should not be used concurrently or within 6-12 months of isotretinoin due to increased risk of keloid formation. OCPs, oral contraceptive pills.

➤ Although acne is often diagnosed clinically, testing is indicated for patients with signs and symptoms suggestive of an endocrine disorder.

fluoroquinolones, aminoglycosides, chloramphenicol, sulfonamides/sulfur, and gyrase inhibitors should not be used for acne because of a lack of efficacy.⁶

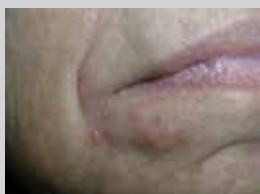Regardless of the type of oral antibiotic prescribed, it should be tried for about 3 months (8-16 weeks) and discontinued once improvement occurs. If no improvement is seen within 3 months, consider changing antibiotics due to resistance or adding antifungal therapy for *Pityrosporum* and *Malassezia* species.⁶

Initiating isotretinoin therapy: An evidence-based approach

Oral isotretinoin is the only potential cure for acne vulgaris. The cure rate is about 30% to 40% (with about 20% of patients developing a recurrence that requires retreatment within one to 3 years).²⁵

Isotretinoin is FDA approved for severe nodulocystic acne, but several organizations, including the AAD and the Global Alliance to Improve Outcomes in Acne, recommend its use for milder cases.^{25,26} It is also an ex-

Diagnostic challenge Is it acne?



No, it isn't. Pustules on the face, like those on the patient pictured here, are a common manifestation of acne. But facial lesions alone are not sufficient for a definitive diagnosis. In fact, the pustules that this 59-year-old woman sought treatment for were correctly diagnosed as perioral dermatitis. The tip-off? The lack of comedones and the distribution of the lesions, which were concentrated around the mouth.

cellent treatment for other forms of severe acne, such as acne fulminans and acne conglobata. Accutane is no longer available, but 5 other formulations of isotretinoin are on the market.

Because isotretinoin is a category X teratogen, all providers and patients must register with iPLEDGE (www.ipledgeprogram.com), an FDA-approved mandatory risk management program. Before starting to take isotretinoin, females of childbearing age are required to undergo 2 pregnancy tests; they must also agree to use 2 forms of program-approved birth control and submit to monthly pregnancy tests.

Patients on isotretinoin also need to be monitored for depression.²⁷ Other potential adverse effects include hepatitis, hypertriglyceridemia, arthralgia, myalgias, and inflammatory bowel disease.^{28,29} Dry skin and mucosa are the most common adverse effects, and patients should be advised to use moisturizers regularly.

A better dosing regimen?

The standard starting dose of isotretinoin is 0.25 to 1 mg/kg/d, divided and taken twice a day, then titrated upward monthly to a maximum daily dose of 2 mg/kg. The goal is for the total intake of isotretinoin to be 120 to 150 mg/kg. So, for example, the goal for a patient weighing 60 kg might be a cumulative intake of 7200 mg (120 mg/kg × 60 kg), taken in doses of 20 mg BID (40 mg/d) for 180 days.

The medication should be taken with food (especially with fatty food) for better absorption. Treatment duration has typically been 16 to 32 weeks, with an average of 20 weeks, with the daily dose lowered in patients requiring treatment for a longer period of time. Continuous use of isotretinoin is more effective than taking it intermittently.²⁶

■ **Lower dosages?** While that standard regimen has been adequate in the management of acne vulgaris, emerging evidence suggests that dosages of isotretinoin as low as 5 mg/d are equally effective and have significantly fewer adverse effects.³⁰ Relapse continues to be a problem. Risk factors for relapse include a macrocomedonal pattern of acne, smoking, and age, with patients <14 years and >25 years at higher risk.³⁰ While lower dos-

ing was previously thought to be associated with greater risk of relapse, this appears to be related less to the cumulative dose of 120 to 150 mg/kg and more to the duration of sebaceous gland suppression.³⁰

Based on the latest evidence, important changes in isotretinoin administration are called for—specifically, using a much lower dose (0.25-0.5 mg/kg, divided into 2 daily doses) for a longer period of time.³⁰ While the traditional dosing generally requires a 3- to 5-month course of treatment, the lower dosing can take 6 to 8 months.

Who's a candidate for hormonal therapy?

Any hormone that has antiandrogenic properties can have a beneficial effect on acne.

The most common hormonal therapy is an estrogen-progestin combination OCP.^{23,31} Progesterone-only OCPs should not be used as they can worsen acne.

In theory, any OCP that contains estrogen can work because of its androgenic properties. The estrogen appears to suppress sebaceous gland activity. OCPs with FDA approval for the treatment of acne include Estrostep Fe (norethindrone/ethinyl estradiol [EE]), Ortho Tri-cyclen (norgestimate/EE), and Yasmin and Beyaz (drospirenone/EE). With any OCP, the effect is gradual, and it can take 3 to 4 months for patients to see an improvement. OCPs are an excellent choice for women with moderate-to-severe acne or those suffering from hirsutism and seborrhea.

Other hormonal therapies—which are not FDA approved for acne treatment—include spironolactone, cyproterone, and flutamide.²⁴ There is no evidence to support the use of finasteride or cyproterone.

Spironolactone is the most studied and has modest benefits at 100 to 150 mg/d.²² Caution is needed when using spironolactone, as gynecomastia, hyperkalemia, and agranulocytosis are potential adverse effects. It is important to closely monitor the blood pressure, chemistry, and cell count of patients taking spironolactone.

CASE ► Because Ms. S is sexually active and does not wish to become pregnant, she is a



Tetracycline antibiotics should not be prescribed for children younger than 10 years or for pregnant women.

➤ **Before taking isotretinoin, females of childbearing age must have 2 pregnancy tests and agree to use 2 forms of contraception.**

candidate for an OCP. You prescribe a pill containing norgestimate and EE, add a topical retinoid to her regimen, and schedule a return visit in 3 months to evaluate the effectiveness of therapy. If there is little improvement, you will recommend isotretinoin at that time.

Talk to patients about lifestyle modifications

Although the role of lifestyle changes in acne treatment is controversial, there is some evidence to suggest that these modifications are worth considering:

■ **Glycemic load.** In Western society, where the typical diet includes foods with a high glycemic index, there appears to be a higher prevalence of acne compared with regions where foods with a low glycemic index (≤ 55 -60) are the mainstay. A low glycemic load appears to reduce both the occurrence and severity of acne.¹⁷ Thus, patients who are willing to make dietary changes should be advised to consume foods with a lower glycemic index, such as peanuts and green vegetables.

■ **Dairy.** Milk is believed to have an androgenic effect, and dairy products in general have a positive correlation with acne. Thus, a reduction in milk intake has been found to improve acne.^{18,32} Stress the importance of calcium supplementation for patients whose dairy consumption is reduced or eliminated.

■ **Fish oil.** Omega-6 fatty acid, found in fish oil, has anti-inflammatory properties, and an increase in foods rich in omega-3 fatty acid (eg, salmon, sardines, walnuts) has been associated with improvement of acne.¹⁷

■ **Probiotics.** There is limited evidence for probiotics as a therapy for acne. They do appear to regulate inflammatory cytokines within the skin and to upregulate the IGF-1, both of which influence the formation of acne.^{10,33}

Other treatment options to consider

Injections, chemical peels, and/or laser treatments may be considered as adjunctive therapy or when standard therapies fail.

■ **Steroid injections.** This treatment regimen centers around a midpotency steroid that is diluted with normal saline and is intro-

duced into each lesion until the lesion is distended and/or blanched. There are limited data on the use of corticosteroid injections for acne, however, and these injections are reserved for severe cases to reduce inflammation. Potential adverse effects include hyperglycemia, obesity, and Cushing traits.

■ **Chemical peels** are used to decrease both inflammatory and noninflammatory lesions, and are typically well tolerated. In one study, more than 95% of patients were satisfied with the results.^{11,34}

Various chemicals have been used, including alpha-hydroxyl acid (glycolic acid), beta-hydroxyl acid (salicylic acid), and Jessner's solution, with equal efficacy.³⁵⁻³⁸ Chemical peels can be used on patients with darker skin, but caution is required to avoid dyschromia.³⁹ Other adverse effects include dry skin, crusting, and facial erythema. More adverse effects have been reported with glycolic acid vs salicylic acid.³⁷

■ **Laser therapies** include photodynamic therapy—blue light with amino-luvinic acid—and phototherapy (blue light alone).⁴⁰⁻⁴² *P. acnes* accumulate photosensitizing porphyrins in the comedones; when the laser therapy is applied, the porphyrins absorb the light source and destroy the bacteria.

Laser treatment can also be used for scarring. Ablative laser resurfacing significantly improves acne scars; nonablative and fractional CO₂ laser modalities can also be used, with minimal downtime and no serious complications.⁴³

Other complementary therapies, including aloe vera, pyridoxine, kampo, tea tree extract, and fruit-based acids, have little or no data regarding their efficacy.

The importance of maintenance therapy

With the exception of patients whose acne was cured or who achieved remission with isotretinoin, maintenance is required once the desired appearance is reached. Without it, recurrence is likely—possibly within as little as 4 weeks.

For most patients, a topical retinoid is the only medication that should be continued. Tell patients to apply it nightly and to call for an appointment if an acne flare-up occurs.

CASE ▶ When Ms. S comes in for a follow-up visit, her acne is cleared except for a couple of lesions on her back and she is happy with the results. You advise her to continue on the OCP to avoid a recurrence but caution her that in a small percentage of cases, the acne may wors-

en even in women who continue to take OCPs and topicals. You agree to initiate isotretinoin if this occurs.

JFP

CORRESPONDENCE

Tam T. Nguyen, MD, San Joaquin General Hospital, 500 West Hospital Road, Suite 1103, French Camp, CA 95231; ttnguyen@sgh.org

References

- Ghods SZ, Orawa H, Zouboulis CC. Prevalence, severity, and severity risk factors of acne in high school pupils: a community-based study. *J Invest Dermatol.* 2009;129:2136-2141.
- Collier CN, Harper JC, Cafardi JA, et al. The prevalence of acne in adults 20 years and older. *J Am Acad Dermatol.* 2008;58:56-59.
- Lucky AW, Biro FM, Huster GA, et al. Acne vulgaris in premenarchal girls. An early sign of puberty associated with rising levels of dehydroepiandrosterone. *Arch Dermatol.* 1994;130:308-314.
- Kubota Y, Shirahige Y, Nakai K, et al. Community-based epidemiological study of psychosocial effects of acne in Japanese adolescents. *J Dermatol.* 2010;37:617-622.
- Strauss JS, Krowchuk DP, Leyden JJ, et al. Guidelines of care for acne vulgaris management. *J Am Acad Dermatol.* 2007;56:651-663.
- Thiboutot D, Gollnick H, Bettoli V, et al. New insights into the management of acne: an update from the Global Alliance to Improve Outcomes in Acne group. *J Am Acad Dermatol.* 2009;60(suppl):S1-S50.
- Jeremy AH, Holland DB, Roberts SG, et al. Inflammatory events are involved in acne lesion initiation. *J Invest Dermatol.* 2003;121:20-27.
- Kurokawa I, Danby FW, Ju Q, et al. New developments in our understanding of acne pathogenesis and treatment. *Exp Dermatol.* 2009;18:821-832.
- Zouboulis CC, Baron JM, Bohm M, et al. Frontiers in sebaceous gland biology and pathology. *Exp Dermatol.* 2008;17:542-551.
- Melnik BC, Schmitz G. Role of insulin, insulin-like growth factor-1, hyperglycaemic food and milk consumption in the pathogenesis of acne vulgaris. *Exp Dermatol.* 2009;18:833-841.
- Stery W, Paus R, Burgdorf WHC. *Dermatology. Thieme Clinical Companions.* Stuttgart, Germany: Thieme; 2006:530-535.
- Ballanger F, Baudry P, Nguyen JM, et al. Heredity: a prognostic factor for acne. *Dermatology.* 2006;212:145-149.
- Chen MJ, Chen CD, Yang JH, et al. High serum dehydroepiandrosterone sulfate is associated with phenotypic acne and a reduced risk of abdominal obesity in women with polycystic ovary syndrome. *Hum Reprod.* 2011;26:227-234.
- Yosipovitch G, Tang M, Dawn AG, et al. Study of psychological stress, sebum production and acne vulgaris in adolescents. *Acta Derm Venereol.* 2007;87:135-139.
- Adityan B, Kumari R, Thappa DM. Scoring systems in acne vulgaris. *Indian J Dermatol Venereol Leprol.* 2009;75:323-326.
- US Food and Drug Administration. Global acne severity scale. Available at: http://www.fda.gov/ohrms/dockets/ac/02/briefing/3904B1_03_%20Acne%20Global%20Severity%20Scale.pdf. Accessed January 16, 2013.
- Jung JY, Yoon MY, Min SU, et al. The influence of dietary patterns on acne vulgaris in Koreans. *Eur J Dermatol.* 2010;20:768-772.
- Adebamowo CA, Spiegelman D, Berkey CS, et al. Milk consumption and acne in teenaged boys. *J Am Acad Dermatol.* 2008;58:787-793.
- Hsu P, Litman GI, Brodell RT. Overview of the treatment of acne vulgaris with topical retinoids. *Postgrad Med.* 2011;123:153-161.
- Kim RH, Armstrong AW. Current state of acne treatment: high-lighting lasers, photodynamic therapy, and chemical peels. *Dermatol Online J.* 2011;17:2.
- Simonart T, Dramaix M, De Maertelaer V. Efficacy of tetracyclines in the treatment of acne vulgaris: a review. *Br J Dermatol.* 2008;158:208-216.
- Ingram JR, Grindlay DJ, Williams HC. Management of acne vulgaris: an evidence-based update. *Clin Exp Dermatol.* 2010;35:351-354.
- Rosen MP, Breitkopf DM, Nagamani M. A randomized controlled trial of second- versus third-generation oral contraceptives in the treatment of acne vulgaris. *Am J Obstet Gynecol.* 2003;188:1158-1160.
- Simpson RC, Grindlay DJ, Williams HC. What's new in acne? An analysis of systematic reviews and clinically significant trials published in 2010-11. *Clin Exp Dermatol.* 2011;36:840-844.
- Borghi A, Mantovani L, Minghetti S, et al. Low-cumulative dose isotretinoin treatment in mild-to-moderate acne: efficacy in achieving stable remission. *J Eur Acad Dermatol Venereol.* 2011;25:1094-1098.
- Agarwal US, Besarwal RK, Bhola K. Oral isotretinoin in different dose regimens for acne vulgaris: a randomized comparative trial. *Indian J Dermatol Venereol Leprol.* 2011;77:688-694.
- Kaymak Y, Taner E, Taner Y. Comparison of depression, anxiety and life quality in acne vulgaris patients who were treated with either isotretinoin or topical agents. *Int J Dermatol.* 2009;48:41-46.
- Crockett SD, Porter CQ, Martin CF, et al. Isotretinoin use and the risk of inflammatory bowel disease: a case-control study. *Am J Gastroenterol.* 2010;105:1986-1993.
- Crockett SD, Gulati A, Sandler RS, et al. Causal association between isotretinoin and inflammatory bowel disease has yet to be established. *Am J Gastroenterol.* 2009;104:2387-2393.
- Rademaker M. Isotretinoin: dose, duration and relapse. What does 30 years of usage tell us? *Australas J Dermatol.* 2012 September 26 [Epub ahead of print].
- Worret I, Arp W, Zahradnik HP, et al. Acne resolution rates: results of a single-blind, randomized, controlled, parallel phase III trial with EE/CMA (Belara) and EE/LNG (Microgynon). *Dermatology.* 2001;203:38-44.
- Adebamowo CA, Spiegelman D, Danby FW, et al. High school dietary dairy intake and teenage acne. *J Am Acad Dermatol.* 2005;52:207-214.
- Bowe WP, Logan AC. Acne vulgaris, probiotics and the gut-brain-skin axis - back to the future? *Gut Pathog.* 2011;3:1.
- Atzori L, Brundu MA, Orru A, et al. Glycolic acid peeling in the treatment of acne. *J Eur Acad Dermatol Venereol.* 1999;12:119-122.
- Levesque A, Hamzavi I, Seite S, et al. Randomized trial comparing a chemical peel containing a lipophilic hydroxy acid derivative of salicylic acid with a salicylic acid peel in subjects with comedonal acne. *J Cosmet Dermatol.* 2011;10:174-178.
- Garg VK, Sinha S, Sarkar R. Glycolic acid peels versus salicylic-mandelic acid peels in active acne vulgaris and post-acne scarring and hyperpigmentation: a comparative study. *Dermatol Surg.* 2009;35:59-65.
- Kessler E, Flanagan K, Chia C, et al. Comparison of alpha- and beta-hydroxy acid chemical peels in the treatment of mild to moderately severe facial acne vulgaris. *Dermatol Surg.* 2008;34:45-51.
- Lee SH, Huh CH, Park KC, et al. Effects of repetitive superficial chemical peels on facial sebum secretion in acne patients. *J Eur Acad Dermatol Venereol.* 2006;20:964-968.
- Grimes PE. The safety and efficacy of salicylic acid chemical peels in darker racial-ethnic groups. *Dermatol Surg.* 1999;25:18-22.
- Gold MH. Acne and PDT: new techniques with lasers and light sources. *Lasers Med Sci.* 2007;22:67-72.
- Gold MH. Acne vulgaris: lasers, light sources and photodynamic therapy—an update 2007. *Expert Rev Anti Infect Ther.* 2007;5:1059-1069.
- Orringer JS, Sachs DL, Bailey E, et al. Photodynamic therapy for acne vulgaris: a randomized, controlled, split-face clinical trial of topical aminolevulinic acid and pulsed dye laser therapy. *J Cosmet Dermatol.* 2010;9:28-34.
- Chapas AM, Brightman L, Sukal S, et al. Successful treatment of acneiform scarring with CO2 ablative fractional resurfacing. *Lasers Surg Med.* 2008;40:381-386.

➤ **Milk is thought to have an androgenic effect, and reducing milk intake has been associated with an improvement in acne.**