

Series Editor: Camila K. Janniger, MD

Genital Ulcers Associated With Epstein-Barr Virus

Kimberly Jerdan, MD; Iris Aronson, MD; Claudia Hernandez, MD; Patricia M. Fishman, MD; John V. Groth, MD

Practice Points

- Epstein-Barr virus should be considered as a potential cause of genital ulcers in young women who are not sexually active.
- Flulike symptoms, fever, headache, and/or diarrhea may precede genital ulcers.
- Monospot test may be falsely negative in the first 2 weeks of infection.

Genital ulcerations are a rare clinical finding of Epstein-Barr virus (EBV) infection. We present the case of a 16-year-old adolescent girl who reported the onset of diarrhea, headaches, dysuria, and vaginal discharge along with vulvar ulcerations with edema. Laboratory studies revealed a high-quantitative EBV IgG and early antigen as well as a positive IgM antibody for EBV. Although the association between EBV and genital ulcerations is rare, physicians should be aware of this clinical presentation to exclude other infectious entities, to be reassured to accept negative testing, and to quell patient distress or concerns of abuse.

Cutis. 2013;91:273-276.

Epstein-Barr virus (EBV) is an infectious agent most commonly associated with infectious mononucleosis, a common syndrome in adolescents and young adults. Most cases are characterized by fever, pharyngitis, lymphadenopathy, and fatigue. Genital infection due to EBV is unusual and typically manifests as ulcerations that easily may

be misdiagnosed as herpes simplex virus (HSV). However, genital ulcers may be the primary clinical indicator of EBV infection in adolescent girls.¹⁻⁴ We report a case of vulvar ulcerations with edema in a 16-year-old adolescent girl that were linked to EBV infection.

Case Report

A 16-year-old adolescent girl with oral aphthous ulcers presented to the dermatology clinic for evaluation of labial edema on the left side and ulceration of 1 week's duration (Figure 1). The patient reported onset of diarrhea approximately 2 weeks prior to the

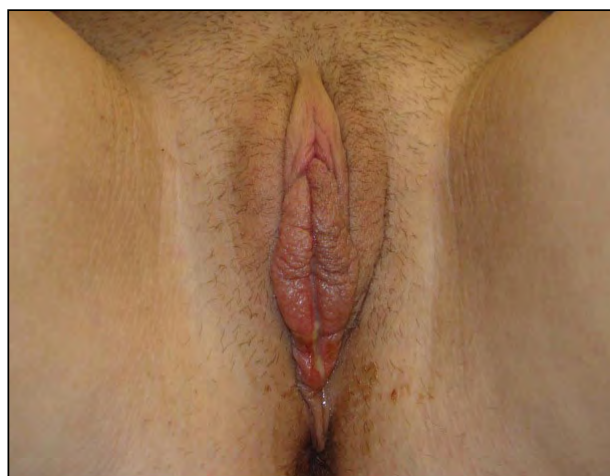


Figure 1. Labial edema on the left side.

From the University of Illinois College of Medicine, Chicago. Drs. Jerdan, Aronson, and Hernandez are from the Department of Dermatology, and Drs. Fishman and Groth are from the Department of Pathology.

The authors report no conflict of interest.

Correspondence: Claudia Hernandez, MD, Department of Dermatology (MC 624), University of Illinois College of Medicine, 808 S Wood St, Room 376 CME, Chicago, IL 60612 (claudiah@uic.edu).

genital eruption and a more recent onset of headaches that coincided with the appearance of the genital ulcers. Other concerns included dysuria and yellowish vaginal discharge. Her medical history was otherwise unremarkable.

Physical examination revealed multiple discrete, sharply demarcated ulcers on the labia majora that were approximately 5 mm in diameter. The ulcers were 5-mm deep with a yellow base, and the edge of the labia minora was noted to have a purple hue (Figure 2A). Inguinal lymphadenopathy and a lacy, white, linear, buccal mucosal plaque also were noted.

The patient's gynecologist previously had biopsied one of the labial ulcers prior to dermatology consultation. Pathology was notable for ulceration with neutrophilic inflammation and fibrin thrombi in small vessels. Histology revealed granulation

tissue underneath an eroded epithelium. The intact portion of the overlying epithelium was slightly hyperplastic (Figure 3) with no evidence of viral cytopathic changes. Extensive acute suppurative inflammation with reactive changes was present in the dermal small blood vessels (Figure 4). Periodic acid–Schiff stain was negative for fungal elements, but Gram stain demonstrated scattered gram-positive bacilli. Bacteria, HSV, gonorrhea, and chlamydia cultures were negative.

On follow-up examination 5 days after presentation, newer ulcers coalesced with older lesions and measured up to 8 mm in diameter. Yellow exudate covered the inner aspects of the labia minora. The patient was treated with a single dose of azithromycin (1 g) and topical lidocaine 2% as needed for pain control. Two days after follow-up, she still reported headaches, but the vulvar ulcerations and edema

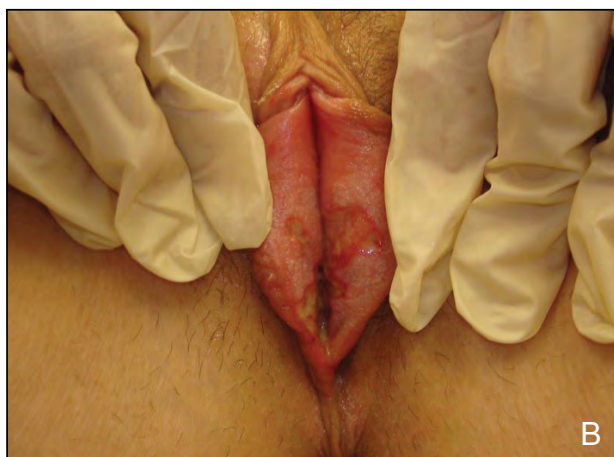
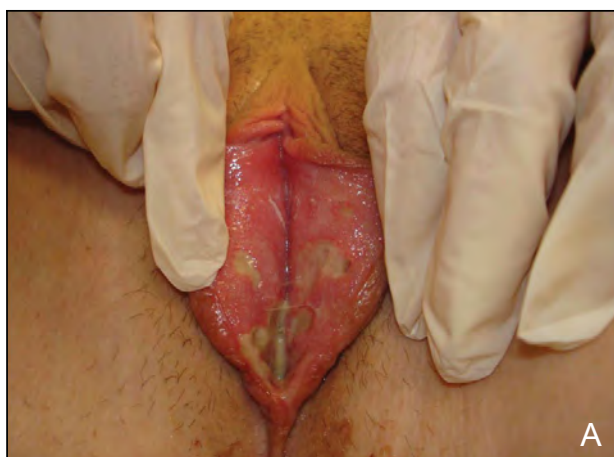
Figure 2. Genital ulcerations from Epstein-Barr virus infection (A). Ulcerations persisted for days with decreased vaginal discharge (B).

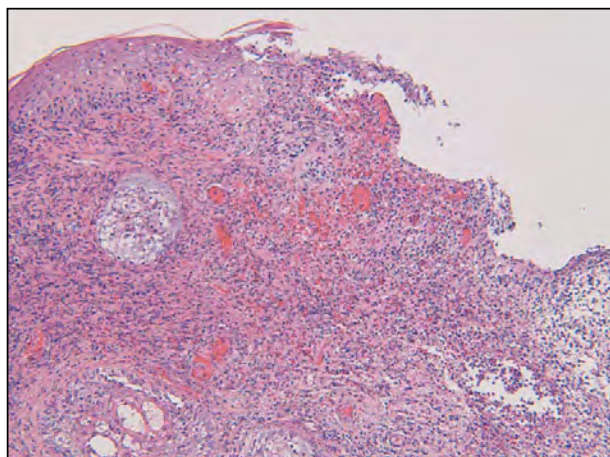


Figure 3. Slightly hyperplastic overlying epithelium (H&E, original magnification $\times 20$).

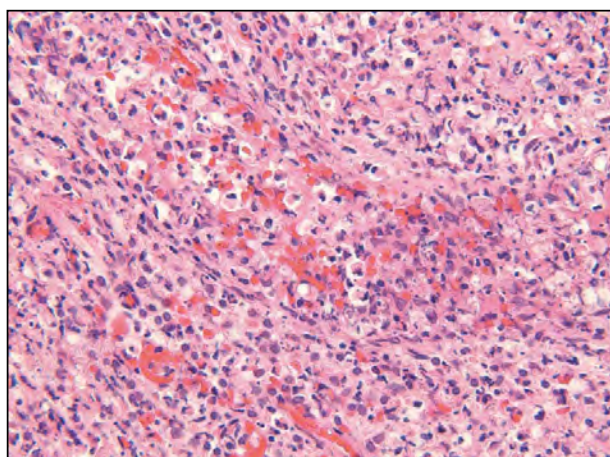


Figure 4. Extensive acute suppurative inflammation (H&E, original magnification $\times 60$).

had decreased (Figure 2B). Elevated liver function tests were detected with an aspartate aminotransferase level of 355 U/L (reference range, 10–34 U/L) and alanine aminotransferase level of 466 U/L (reference range, 10–40 U/L). The complete blood cell count was within reference range, and direct fluorescent antibody tests for viral HSV, HSV titers, and cytomegalovirus titers all were negative; however, EBV IgG was high (2.22 U [reference range, <0.99 U]) and EBV IgM results were within reference range (0.73 U [reference range, <0.99 U]).

Three weeks after presentation, the ulcerations began to resolve. To control vulvar pain, the patient was treated with topical lidocaine 2% as needed, metronidazole gel 0.75% once daily, and clobetasol gel 0.05% once daily. A positive monospot test result was indicative of a new EBV infection. Repeat EBV IgM levels registered at 6.54 U (high), EBV viral capsid antigen IgG at 9.12 U (within reference range), and EBV early antigen at 5.02 U (high). A diagnosis of EBV-associated vaginal ulcerations and EBV mononucleosis was made.

Comment

Genital ulcers may be linked to acute febrile illnesses of various etiologies, both noninfectious and infectious, one of which is EBV infection.⁵ In 26 case reports from 1913 to 2006 linking EBV to genital ulcers in females, the mean age of patients was 14.5 years. Sexual activity was reported in 6 of those cases.⁵ According to Lehman et al,⁶ in 70% (7/10) of reported cases with genital ulcers linked to EBV, patients had a history of oral aphthosis,⁶ including our patient. Because EBV genital ulceration is rare, the probability for misdiagnosis is high,⁶ with HSV often being the assumed etiology of genital ulcers, especially in patients who are sexually active. Our patient denied sexual activity. When patients report no history of sexual activity, it is important to remember EBV as a potential etiology of genital ulcers before becoming skeptical of their sexual history or considering sexual abuse. Suspicion of sexual abuse adds considerable stress for the patient and family members and has substantial social implications for the individuals involved.⁷ Other systemic non-sexually transmitted but rare infectious etiologies of genital ulcerations include mumps,⁸ cytomegalovirus,⁹ and paratyphoid fever¹⁰; noninfectious etiologies include Crohn disease and Behçet disease.¹¹

Primary EBV infection typically is seen in early childhood or adolescence in developing countries,¹² with an estimated 90% of adults worldwide likely having had a primary asymptomatic infection.¹³ Epstein-Barr virus is classified as a member of the Herpesviridae family with double-stranded DNA. It

proliferates in the squamous epithelium, spreading to host B lymphocytes that preferentially infect the oral mucosa.¹⁴ Epstein-Barr virus possibly is most well-known for causing infectious mononucleosis, a clinical syndrome that presents with fever, pharyngitis, lymphadenopathy, malaise, loss of appetite,

Reported Findings in 33 Cases of Epstein-Barr Virus Infection^{1-7,12,13,15,a}

Symptom	Patients With Symptom, % (n)
Genital ulcers	100% (33/33)
Fever	72.7% (24/33)
Dysuria	51.5% (17/33)
Pharyngitis	48.5% (16/33)
Oral ulcers	45.5% (15/33)
Lymphadenopathy	42.4% (14/33)
Atypical lymphocytosis	30.3% (10/33)
Bilateral inguinal lymphadenopathy	21.2% (7/33)
Fatigue	18.2% (6/33)
Diarrhea	15.2% (5/33)
Headache	12.1% (4/33)
Malaise	12.1% (4/33)
Abdominal pain	9.1% (3/33)
Arthritis	9.1% (3/33)
Myalgia	9.1% (3/33)
Abnormal liver function tests	6.1% (2/33)
Morbilloform rash	6.1% (2/33)
Nausea	6.1% (2/33)
Splenomegaly	3.0% (1/33)
Urinary frequency	3.0% (1/33)

^aIncludes current report.

headache, prolonged fatigue, and atypical lymphocytosis.¹³ A review of the literature found that these typical symptoms appeared before the onset of the vulvar ulcers,^{6,15} and in all likelihood, EBV-induced vulvar ulceration is more common than suspected.⁷ The Table summarizes reported findings in EBV infections.^{1-7,12,13,15}

Suggested evaluation of patients with vulvar ulcers includes physical examination and complete medical history; complete blood cell count with differential; HSV polymerase chain reaction, or biopsy and direct fluorescent antibody testing of the specimen; potassium hydroxide preparation; bacterial culture; syphilis serology; IgG and IgM viral capsid antigens for EBV; and human immunodeficiency virus serologies.^{6,13} Physicians must be careful when relying on the monospot test to confirm a case of mononucleosis, as it is often reported negative for infectious mononucleosis during the first 2 weeks of symptoms.¹³ Diagnosis can be made with presence of IgM to the EBV viral capsid antigen or EBV DNA polymerase chain reaction examination.⁷

Although resolution of infectious mononucleosis can take 5 to 10 weeks,¹⁶ acute vulvar ulcers normally heal within 2 weeks.⁷ Recurrence of the vulvar ulcers has not yet been reported in the literature, but it has been recommended that patients with EBV-linked ulcers should be followed over time¹⁵ to learn more about possible recurrences or long-term sequelae.¹² Awareness of EBV as the potential cause of vulvar ulcers in adolescent girls should be part of any differential diagnoses.

Conclusion

The occurrence of genital ulcers with EBV appears to be rare; however, physicians should be aware of this clinical finding in adolescent girls who are not sexually active. Knowledge of this potential finding should encourage physicians to pursue other infectious causes of the condition, which will reduce the possibility of causing distress to the patient and the family.

REFERENCES

- Hudson LB, Perlman SE. Necrotizing genital ulcerations in a premenarcheal female with mononucleosis. *Obstet Gynecol.* 1998;92(4, pt 2):642-644.
- Lorenzo CV, Robertson WS. Genital ulcerations as presenting symptom of infectious mononucleosis. *J Am Board Fam Pract.* 2005;18:67-68.
- Portnoy J, Ahronheim GA, Ghibu F, et al. Recovery of Epstein-Barr virus from genital ulcers. *N Engl J Med.* 1984;311:966-968.
- Sisson BA, Glick L. Genital ulceration as a presenting manifestation of infectious mononucleosis. *J Pediatr Adolesc Gynecol.* 1998;11:185-187.
- Halvorsen JA, Brevig T, Aas T, et al. Genital ulcers as initial manifestation of Epstein-Barr virus infection: two new cases and a review of the literature. *Acta Derm Venereol.* 2006;86:439-442.
- Lehman JS, Bruce AJ, Wetter DA, et al. Reactive nonsexually related acute genital ulcers: review of cases evaluated at Mayo Clinic [published online ahead of print May 11, 2010]. *J Am Acad Dermatol.* 2010;63:44-51.
- Taylor S, Drake SM, Dedicat M, et al. Genital ulcers associated with acute Epstein-Barr virus infection. *Sex Trans Infect.* 1998;74:296-297.
- Chanal J, Carlotti A, Laude H, et al. Lipschütz genital ulceration associated with mumps [published online ahead of print October 1, 2010]. *Dermatology.* 2010;221:292-295.
- Martín JM, Godoy R, Calduch L, et al. Lipschütz acute vulvar ulcers associated with primary cytomegalovirus infection. *Pediatr Dermatol.* 2008;25:113-155.
- Pelletier F, Aubin F, Puzenat E, et al. Lipschütz genital ulceration: a rare manifestation of paratyphoid fever. *Eur J Dermatol.* 2003;13:297-298.
- Huppert JS. Lipschutz ulcers: evaluation and management of acute genital ulcers in women. *Dermatol Ther.* 2010;23:533-540.
- Brown ZA, Stenchever MA. Genital ulceration and infectious mononucleosis: report of a case. *Am J Obstet Gynecol.* 1977;127:673-674.
- Cheng SX, Chapman MS, Margesson LJ. Genital ulcers caused by Epstein-Barr virus. *J Am Acad Dermatol.* 2004;51:824-826.
- Thompson MP, Kurzrock R. Epstein-Barr virus and cancer. *Clin Cancer Res.* 2004;10:803-821.
- Deitch H, Huppert J, Adams Hillard PJ. Unusual vulvar ulcerations in young adolescent females. *J Pediatr Adolesc Gynecol.* 2004;17:13-16.
- Mendoza N, Diamantis M, Arora A, et al. Mucocutaneous manifestations of Epstein-Barr virus infection. *Am J Clin Dermatol.* 2008;9:295-305.