

# Treating Acne Scars in Patients With Fitzpatrick Skin Types IV to VI Using the 1450-nm Diode Laser

Natalie Semchyshyn, MD; Edward Prodanovic, MD; Reena Varade, MD

*Individuals with Fitzpatrick skin types IV to VI are becoming a larger proportion of our patient base. Although acne scarring can be difficult to treat in all skin types, it presents a greater challenge in darker skin types due to an increased risk for scarring and postinflammatory hyperpigmentation (PIH). Few studies have focused on infrared laser treatment of acne scarring in darker skin types. In this study, we assess the efficacy and side-effect profile of a 1450-nm diode laser for the treatment of acne scars in participants with Fitzpatrick skin types IV to VI. Our findings show the nonablative 1450-nm diode laser to be safe and effective in improving the appearance of atrophic acne scars in darker skin types. Postinflammatory hyperpigmentation was a common occurrence.*

*Cutis.* 2013;92:49-53.

As individuals with Fitzpatrick skin types IV to VI are becoming an increasingly larger proportion of the population, we would expect them to become an increasingly larger proportion of our patient base. Acne scarring is a concern in patients of all skin types and can be difficult to treat; however, a variety of treatment options exist. The treatment of acne scarring in darker skin types represents a special challenge due to the increased risk for scarring and postinflammatory hyperpigmentation (PIH) in this patient population.

Traditional skin resurfacing techniques such as ablative laser resurfacing or medium-depth chemical peels are not attractive options for most darker-skinned patients due to the near-universal incidence of PIH, increased risk for infection and scarring, and prolonged healing times.<sup>1,2</sup> Minimally invasive nonablative laser and light treatments have become popular among both patients and physicians due to their minimal downtime and low risk for serious complications. Few studies have focused on infrared laser treatment of acne scarring in darker skin types. Our study was designed to evaluate the efficacy and safety of the 1450-nm diode laser in treating acne scarring in participants with Fitzpatrick skin types IV to VI.

## Methods

This single-center prospective study assessed the clinical efficacy and side-effect profile of the 1450-nm diode laser for treatment of acne scarring in patients with Fitzpatrick skin types IV to VI. Participants were recruited among the outpatient population from the Saint Louis University School of Medicine Department of Dermatology, Missouri; clinical offices; local dermatologists' offices; and the community. Twenty participants, both male and female, aged 25 to 70 years with Fitzpatrick skin types IV to VI and atrophic facial acne scarring were enrolled in the study. The duration of the study was 18 months, which included a baseline visit; monthly treatments and follow-up visits for the first 7 months; and additional follow-up visits at 9, 12, and 18 months. Of the 20 participants, 2 (10%) were lost to follow-up.

Exclusion criteria included pregnancy or lactation in women; history of isotretinoin use within the last 12 months; history of keloids; moderate to severe active inflammatory acne; prior skin resurfacing procedure or dermal filler injections in the treatment area within 12 months of or during the study period;

From the Department of Dermatology, Saint Louis University School of Medicine, Missouri.

The authors report no conflict of interest.

Correspondence: Reena Varade, MD, 4400 Lindell Blvd, Apt 3D, St Louis, MO 63108 (varaders@slu.edu).

history of injectable silicone or other permanent fillers in the treatment area; known sensitivity to laser wavelength, lidocaine/topical anesthetic, or hydroquinone; a medical condition that, in the opinion of the investigator, contraindicated participation in the study (eg, light-induced seizures, vitiligo, lupus erythematosus); and inability to follow aftercare instructions and/or attend follow-up visits. The study was approved by the Saint Louis University institutional review board.

The 1450-nm diode laser (Smoothbeam, Candela Corporation) was used with a 6-mm spot size to deliver fluences ranging from 11 to 14 J/cm<sup>2</sup> with a dynamic cooling device setting of 25 to 35 milliseconds. Participants wore protective eyewear during treatment. Topical anesthesia (L.M.X.4, Biopelle, Inc) was applied for 1 hour and removed immediately before treatment. At each treatment session, 1 pass was performed over treatment areas on both sides of the face with uniform nonoverlapping pulses. Sunscreen (EltaMD, Swiss American Products) was applied to the treatment areas before participants left the office, and aftercare instructions were reviewed and provided in written form at the end of each treatment. If PIH was noted at the follow-up visit, the participant was treated with a combination cream with fluocinolone acetonide 0.01%, hydroquinone 4%, and tretinoin 0.05% (Tri-Luma, Galderma Laboratories, LP), or hydroquinone 4% (Lustra, Medicis Pharmaceutical Corporation). All treatments were performed by 1 dermatologist.

Participants obtained 6 monthly treatments, followed by 4 follow-up visits. Standardized photographs were taken at each visit. Participants filled out subjective assessment questionnaires regarding improvement in the appearance of scars, skin oiliness, smoothness, pore size, degree of PIH after treatments, and any adverse events. Participants rated their improvement on a 10-point scale (1=none; 2–4=minimum; 5–7=moderate; 8–10=significant). Objective assessment of global improvement was performed by nonchronologic comparison of photographs with 45° angle views of the left and right cheeks at baseline and at months 1, 3, 6, 12, and 18. The evaluators (2 nontreating dermatologists) used a 5-point scale to rate the photographs (1=worse/no improvement; 2=mild improvement; 3=moderate improvement; 4=significant improvement; 5=complete resolution), and the average score was obtained for each side of the face. Each averaged score was then converted to a 3-point scale ( $\leq 1$ =no improvement; 1.5–2=marginal improvement;  $\geq 2$ =clear improvement). This method allowed the scores of both blind evaluators to be equally represented in the analysis of the photographs.

## Results

Of the 20 participants enrolled in the study, 2 were lost to follow-up. Results were obtained from data pertaining to the 18 remaining participants.

At the 45° right angle view, evaluators observed clear improvement in 67% (12/18) of participants at the first posttreatment visit, which signified that a score of 2 or higher was obtained by the average of the 2 evaluators. This change was maintained, as 72% (13/18) of participants were classified as having clear improvement at the last posttreatment visit. Eleven percent (2/18) and 22% (4/18) of participants were classified as showing no improvement or marginal improvement, respectively, at the first posttreatment visit.

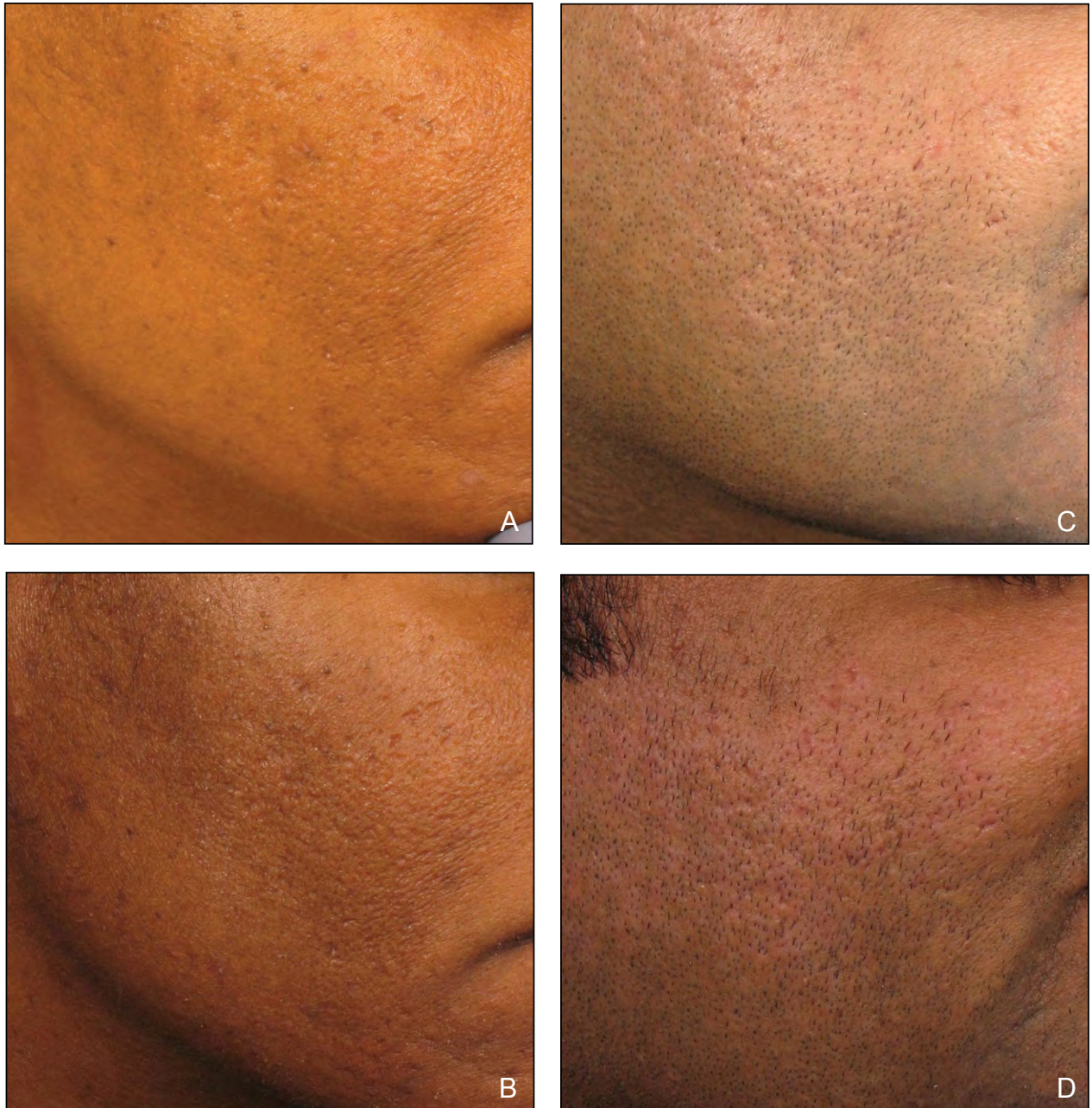At the 45° left angle view, evaluators observed clear improvement in 72% (13/18) of participants at the first posttreatment visit. This change was maintained by 61% (11/18) of participants at the last posttreatment visit. Eleven percent (2/18) and 22% (4/18) of participants were classified as showing no improvement or marginal improvement, respectively, at the first posttreatment visit.

Results from both views were combined to assess overall changes in scarring. Evaluators observed clear improvement that was maintained at the last posttreatment visit on at least 1 side in 83% (15/18) of participants (Figure 1). The remaining 17% (3/18) of participants were rated as showing marginal improvement on at least 1 side. No participants were rated as having no improvement bilaterally at the first or last posttreatment visit, indicating the treatment likely was beneficial for at least 1 side of the face in all participants.

Participant subjective assessments are shown in Figure 2. The majority of participants noted improvement in the appearance of scars, oiliness, smoothness, and pore size. Postinflammatory hyperpigmentation was noted in 56% (10/18) of participants. Mild erythema was common, though blistering occurred only in 1 patient. Serious adverse events were not seen.

## Comment

The treatment of acne scarring in darker skin types is challenging due to an increased risk for scarring and PIH in this patient population. Few studies have focused specifically on infrared laser treatment of acne scarring in darker skin types. Because infrared lasers do not target epidermal melanin, they represent a good nonablative treatment option for these patients. Nonablative treatments have been shown to effect both clinical and histologic improvements in photoaged skin and acne scarring.<sup>3-7</sup> The mechanism of action is thought to involve a modest thermal injury in the dermis, which initiates a cascade of events



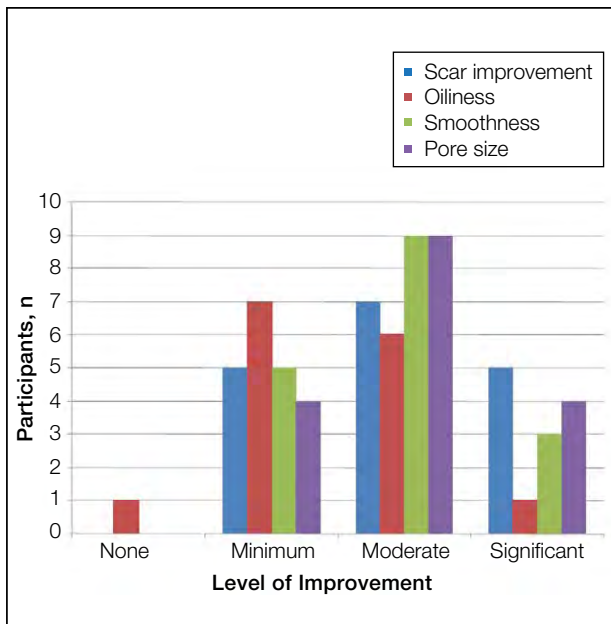
**Figure 1.** Patients with acne scarring on the right cheek at baseline (A and C) and 18 months posttreatment (B and D).

including fibroblast proliferation and upregulation of collagen expression and remodeling.

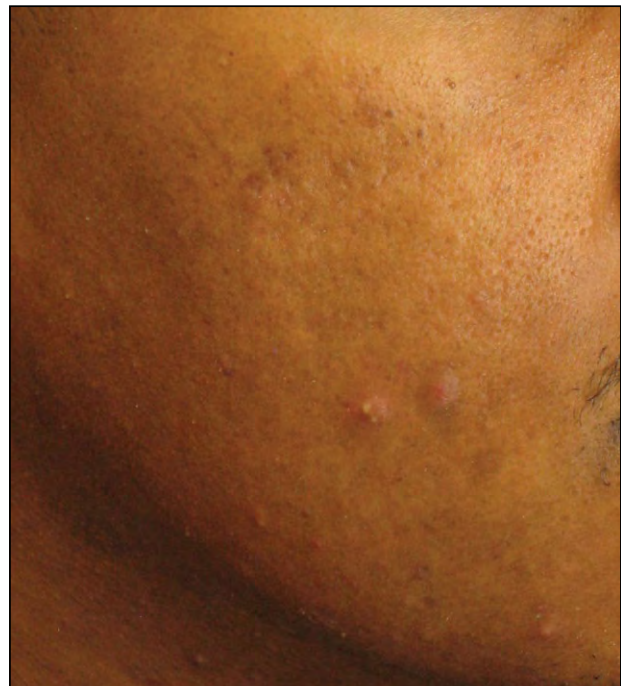Infrared lasers have been successfully used to treat wrinkles and acne scarring, and both clinical and histologic improvement has been documented. Variable rates of PIH have been reported.<sup>8-11</sup> In our study, participants had 6 treatment sessions with an additional 12-month follow-up period for posttreatment assessment. Eighty-three percent (15/18) of participants had clear improvement, which was maintained

from the first to the last posttreatment visit. Our study showed a persistence of improvement for more than 1 year, which is a longer follow-up period than most studies. The participants noted improvement in oiliness, smoothness, and pore size. The modest yet substantial results are consistent with those of other nonablative collagen remodeling treatments.<sup>5,6</sup>

Infrared lasers such as the 1320-nm Nd:YAG and 1450-nm diode laser use a cryogen spray device to cool and protect the epidermis while allowing dermal



**Figure 2.** Secondary outcomes derived from the participant assessment questionnaire regarding improvement in scar appearance, skin oiliness, smoothness, and pore size. Eighteen participants completed the study but not all participants completed the questionnaire in its entirety. Participants rated their improvement on a 10-point scale (1=none; 2–4=minimum; 5–7=moderate; 8–10=significant).



**Figure 3.** Mild treatment-related postinflammatory hyperpigmentation.

heating to effect collagen remodeling. The risk for PIH is related to the degree of cutaneous inflammation. Postinflammatory hyperpigmentation may occur due to epidermal injury from either thermal damage or cold injury caused by cryogen spray cooling.

In our study, PIH was noted in 56% (10/18) of participants at some point during treatment (Figure 3). The incidence of PIH in other reported studies using the 1450-nm diode laser for treatment of acne scars with the high-fluence, single-pass regimen in patients with darker skin types can range from 30% to 66.7%.<sup>10,11</sup> In our study, we believe the instances of PIH were caused by cryogen cooling. The PIH had an arcuate shape in many cases. The settings of the cooling spray used in our study were not excessive. Prior to each treatment session, the laser was test fired on test paper in the recommended manner and no abnormality was observed. It is possible that the dynamic cooling device may have been slightly misaligned with the laser beam, causing excessive cryogen to be delivered to an area of the spot. Despite our best intentions, the treatment sessions overlapped with summer months, which also may have contributed to some of the PIH. Studies using the 1450-nm laser for the treatment of

acne vulgaris in Asians found increased tolerability with a multiple-pass, low-fluence treatment and reported a decreased incidence of PIH compared to high-fluence treatment.<sup>12,13</sup> It is not known if using a multiple-pass, low-fluence regimen would result in decreased efficacy when used in the treatment of acne scarring compared to high-fluence parameters. Given the high incidence of PIH in our study, it seems reasonable to use the multiple-pass, low-fluence technique in an attempt to decrease the risk for this side effect when treating patients with darker skin types.

## REFERENCES

1. Alster T, Hirsch R. Single-pass CO<sub>2</sub> laser skin resurfacing of light and dark skin: extended experience with 52 patients. *J Cosmet Laser Ther.* 2003;5:39-42.
2. Al-Waiz MM, Al-Sharqi AI. Medium-depth chemical peels in the treatment of acne scars in dark-skinned individuals. *Dermatol Surg.* 2002;28:383-387.
3. Goldberg DJ, Rogachefsky AS, Silapunt S. Non-ablative laser treatment of facial rhytides: a comparison of 1450-nm diode laser treatment with dynamic cooling as opposed to treatment with dynamic cooling alone. *Lasers Surg Med.* 2002;30:79-81.

4. Zelickson BD, Kilmer SL, Bernstein E, et al. Pulsed dye laser therapy for sun damaged skin. *Lasers Surg Med.* 1999;25:229-236.
5. Chan HH, Lam LK, Wong DS, et al. Use of 1,320 nm Nd:YAG laser for wrinkle reduction and the treatment of atrophic acne scarring in Asians. *Lasers Surg Med.* 2004;34:98-103.
6. Lipper GM, Perez M. Nonablative acne scar reduction after a series of treatments with a short-pulsed 1,064-nm neodymium:YAG laser. *Dermatol Surg.* 2006;32:998-1006.
7. Sadick NS, Schechter AK. A preliminary study of utilization of the 1320-nm Nd:YAG laser for the treatment of acne scarring. *Dermatol Surg.* 2004;30:995-1000.
8. Tanzi EL, Alster TS. Comparison of a 1450-nm diode laser and a 1320-nm Nd:YAG laser in the treatment of atrophic facial scars: a prospective clinical and histologic study. *Dermatol Surg.* 2004;30(2, pt 1):152-157.
9. Rogachefsky AS, Hussain M, Goldberg DJ. Atrophic and a mixed pattern of acne scars improved with a 1320-nm Nd:YAG laser. *Dermatol Surg.* 2003;29:904-908.
10. Chua SH, Ang P, Khoo LS, et al. Nonablative 1450-nm diode laser in the treatment of facial atrophic acne scars in type IV to V Asian skin: a prospective clinical study. *Dermatol Surg.* 2004;30:1287-1291.
11. Rasheed AI. Non-ablative diode laser for the treatment of post acne scars. *Egyptian Dermatol Online J.* 2005;1:6.
12. Yeung CK, Shek SY, Yu CS, et al. Treatment of inflammatory facial acne with 1,450-nm diode laser in type IV to V Asian skin using an optimal combination of laser parameters [published online ahead of print March 20, 2009]. *Dermatol Surg.* 2009;35:593-600.
13. Noborio R, Nishida E, Morita A. Clinical effect of low-energy double-pass 1450 nm laser treatment for acne in Asians. *Photodermatol Photoimmunol Photomed.* 2009;25:3-7.