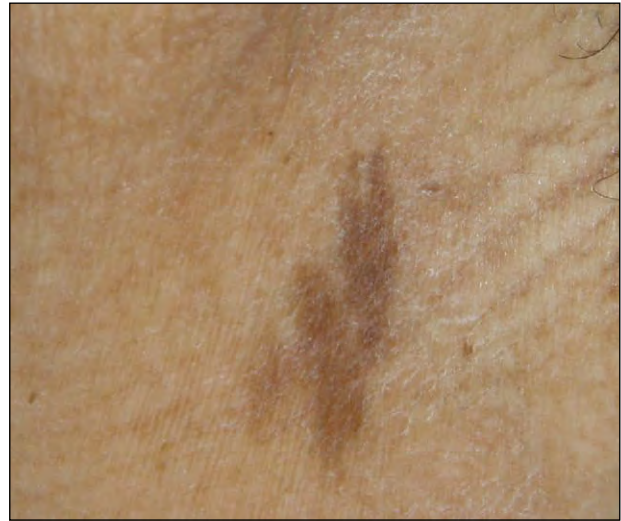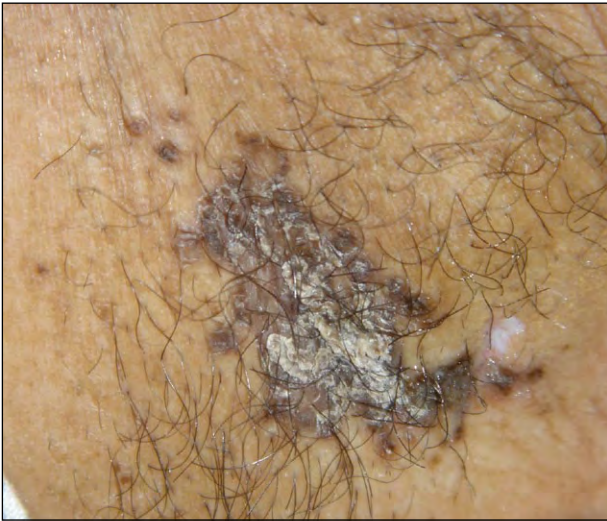


What Is Your Diagnosis?



A 52-year-old obese woman presented with dark brown, scaly, nontender, and nonpruritic eruptions in both axillae that gradually had enlarged and thickened in the last 6 weeks. The left axilla (left) appeared to be more affected than the right axilla (right). The lesions initially appeared as hyperpigmented papules that coalesced into dark plaques covered by an adherent, keratotic, friable scale. Her medical history was notable for mild asthma, seasonal allergies, and obesity. She denied any history of diabetes mellitus. There was no other intertriginous involvement. Potassium hydroxide preparation of the lesion was negative for fungi.

PLEASE TURN TO PAGE 65 FOR DISCUSSION

Jennifer Channal, MD; Douglas J. Fife, MD; Jashin J. Wu, MD

Dr. Channal is from the School of Medicine, University of California, Irvine. Dr. Fife is in private practice, Las Vegas, Nevada. Dr. Wu is from the Department of Dermatology, Kaiser Permanente Los Angeles Medical Center, California.

The authors report no conflict of interest.

Correspondence: Jashin J. Wu, MD, Department of Dermatology, Kaiser Permanente Los Angeles Medical Center, 1515 N Vermont Ave, 5th Floor, Los Angeles, CA 90027 (jashinwu@hotmail.com).

The Diagnosis: Axillary Granular Parakeratosis

Granular parakeratosis (GP), first reported as axillary granular parakeratosis in 1991,¹ is a seemingly rare and possibly underrecognized² benign skin disease manifesting as erythematous to brown, hyperkeratotic papules and plaques that appear most commonly in the axillae (Figures 1 and 2) or other intertriginous regions, such as the

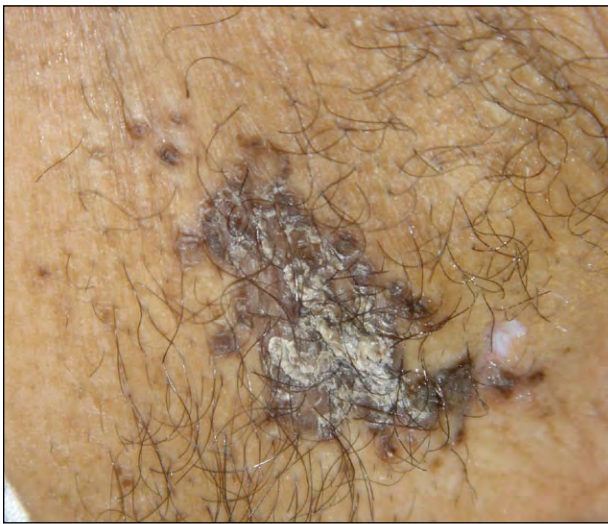


Figure 1. Left axilla with dark brown plaques and adherent, keratotic, friable scaling.

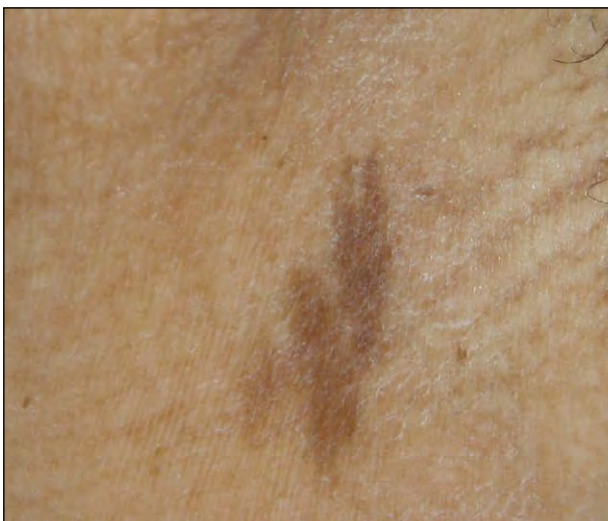

Figure 2. Right axilla with hyperpigmented patches and no scaling.

groin, the submammary and intermammary regions, and the abdominal folds.³ The lesions also may be discrete, confluent, or reticulated,² with the presence of satellite papules.

Clinically, eruptions may present unilaterally or bilaterally and may be pruritic and scaly. Granular parakeratosis affects individuals of all races and ages including children⁴ but appears to have a female predominance (female to male ratio, 25 to 1).⁵ Granular parakeratosis has been associated with exposure to contact irritants or physical factors, including personal hygiene products (eg, antiperspirants, deodorants), hyperhidrosis,³ friction, obesity,⁶ occlusive environments, and excessive washing in children.⁴ Microscopic examination is required for definitive diagnosis. The characteristic histopathologic findings of GP include hyperkeratosis and parakeratosis with retention of keratohyalin granules in the stratum corneum, often with a perivascular infiltrate consisting of lymphocytes and histiocytes.

In our patient, microscopic examination of the epidermis was relatively unremarkable (Figure 3A). A biopsy specimen revealed prominent confluent parakeratosis with retention of keratohyalin granules in the stratum corneum (Figure 3B). Pigment incontinence and a perivascular infiltrate consisting predominantly of lymphocytes were evident within the dermis. The patient initially was treated with hydrocortisone cream 1% with slight improvement after 2 weeks and then was prescribed fluocinonide cream 0.05% due to the improvement noted after hydrocortisone treatment. However, there was only further slight improvement with fluocinonide cream 0.05% after 3 months of therapy.

The etiology of GP is presently unknown, but several hypotheses exist. Some investigators have proposed that it occurs secondary to an allergic contact dermatitis reaction to personal hygiene products, such as deodorants and antiperspirants.^{1,3} More specifically, it has been hypothesized that the contact allergen interrupts the processing of profilaggrin to filaggrin during epidermal differentiation, leading to the retention of nuclei and keratohyalin granules in the stratum corneum^{1,3}; however, the presence of unilateral or extra-axillary lesions and the occurrence of GP even in patients who are not exposed to personal hygiene products do not support this theory. Mehregan et al⁷ suggested that the eruptions may serve as a protective mechanism to mechanical irritation.

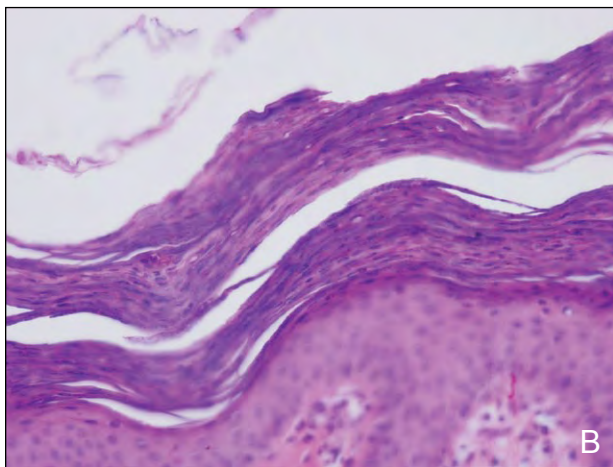
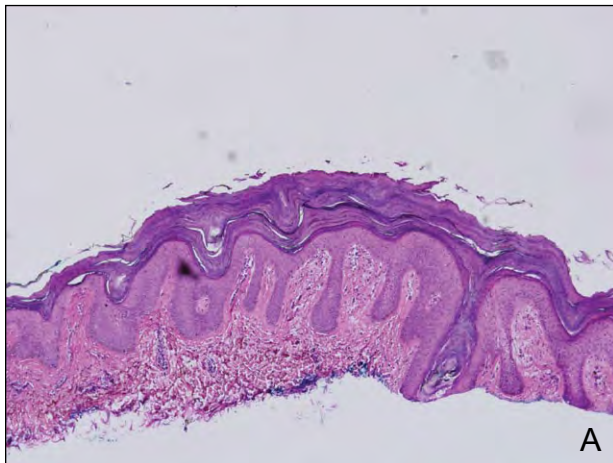


Figure 3. Skin biopsy specimen from the left axilla revealed a relatively unremarkable epidermis (A)(H&E, original magnification $\times 10$). However, prominent confluent parakeratosis with retention of keratohyalin granules was noted in the stratum corneum (B)(H&E, original magnification $\times 400$).

Granular parakeratosis can persist for months but has been reported to resolve spontaneously^{3,7} or upon discontinuation of deodorant or antiperspirant use. Successful treatment also has been reported with the use of topical corticosteroids and oral and topical retinoids.^{5,8} Other treatment options include topical or systemic antifungal agents and antibiotics, topical vitamin D derivatives, and botulinum toxin.⁹ Physical destruction of the lesions via cryotherapy also has been reported.⁶

REFERENCES

1. Northcutt AD, Nelson DM, Tschien JA. Axillary granular parakeratosis. *J Am Acad Dermatol.* 1991;24:541-544.
2. Scheinfeld NS, Mones J. Granular parakeratosis: pathologic and clinical correlation of 18 cases of granular parakeratosis. *J Am Acad Dermatol.* 2005;52:863-867.
3. Metze D, Rütten A. Granular parakeratosis—a unique acquired disorder of keratinization. *J Cutan Pathol.* 1999;26:339-352.
4. Patrizi A, Neri I, Misciali C, et al. Granular parakeratosis: four paediatric cases. *Br J Dermatol.* 2002;147:1003-1006.
5. English JC 3rd, Derdeyn AS, Wilson WM, et al. Axillary granular parakeratosis. *J Cutan Med Surg.* 2003;7:330-332.
6. Wallace CA, Pichardo RO, Yosipovitch G, et al. Granular parakeratosis: a case report and literature review. *J Cutan Pathol.* 2003;30:332-335.
7. Mehregan DA, Thomas JE, Mehregan DR. Intertriginous granular parakeratosis. *J Am Acad Dermatol.* 1998;39:495-496.
8. Compton AK, Jackson JM. Isotretinoin as a treatment for axillary granular parakeratosis. *Cutis.* 2007;80:55-56.
9. Ravitskiy L, Heymann WR. Botulinum toxin-induced resolution of axillary granular parakeratosis. *Skinmed.* 2005;4:118-120.