

# Acantholytic Dyskeratosis Occurring Within an Epidermal Nevus

Shilpi Khetarpal, MD; Michelle Tarbox, MD; Ralph J. Tuthill, MD; Allison Vidimos, MD, RPh

## Practice Points

- Epidermal nevi are congenital epidermal malformations that follow the lines of Blaschko and present between birth and adolescence. There are several histologic subtypes.
- Acantholytic dyskeratosis is a histologic pattern with acanthosis, papillomatosis, and hyperkeratosis containing acantholytic and dyskeratotic keratinocytes in the epidermis. These findings are distinctive but not pathognomonic for Darier disease because they occur in other conditions such as Grover disease, warty dyskeratoma, Starink hamartoma, or acantholytic dyskeratotic epidermal nevi.

*A 25-year-old woman presented with a large area of flesh-colored verrucous plaques following the lines of Blaschko on the left side of the body that had been present since 6 months of age. The plaques had been stable and grew proportionately with the patient's body until she reached 20 years of age when they began to thicken and enlarge. Her medical and family history was unremarkable. A shave biopsy revealed a papillomatous epidermis with 3 discrete foci of acantholytic dyskeratosis, with corps ronds and grains that were similar to the histologic findings of Darier disease (DD). Epidermolytic hyperkeratosis was not identified. Our patient's lack of a family history of DD, early-onset disease, and linear presentation along the lines of Blaschko all favored a diagnosis of acantholytic dyskeratotic epidermal nevi (ADEN) versus localized DD.*

*Cutis.* 2013;92:80-82.

## Case Report

A 25-year-old woman presented with a large area of flesh-colored verrucous plaques following the lines of

Blaschko on the left side of the body that had been present since 6 months of age. The plaques had been stable and grew proportionately with the patient's body until she reached 20 years of age when they began to thicken and enlarge. Her medical and family history was unremarkable. The patient reported mild pruritus but no pain. Prior therapies included ammonium lactate lotion 12% without benefit.

Physical examination revealed numerous flesh-colored verrucous papules coalescing into linear hypertrophic plaques along with several 2- to 3-mm solitary papules involving the left lateral leg, abdomen, flank, and buttocks in a Blaschkoid distribution (Figure 1). No mucosal lesions, nail abnormalities, punctate keratoses, or palmoplantar pits were observed. A biopsy specimen was obtained from the upper left posterior thigh.

The shave biopsy specimen revealed a papillomatous epidermis with 3 discrete foci of acantholytic dyskeratosis, with corps ronds and grains that were similar to the histologic findings of Darier disease (DD)(Figure 2). Epidermolytic hyperkeratosis was not identified. Treatment with the erbium:YAG laser was discussed and 3 sessions were scheduled due to the size of the affected area.

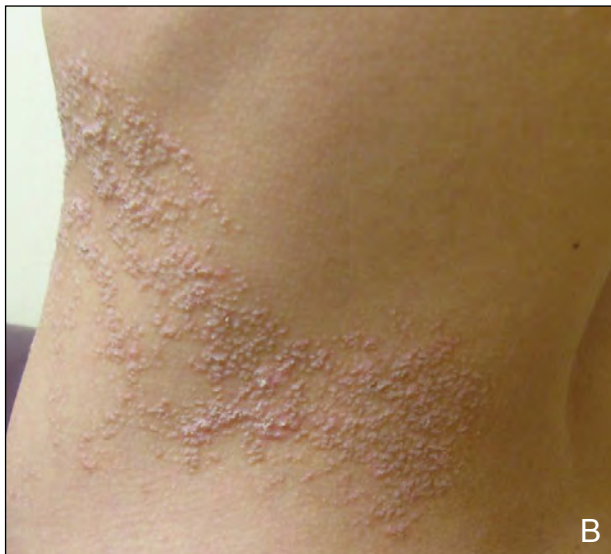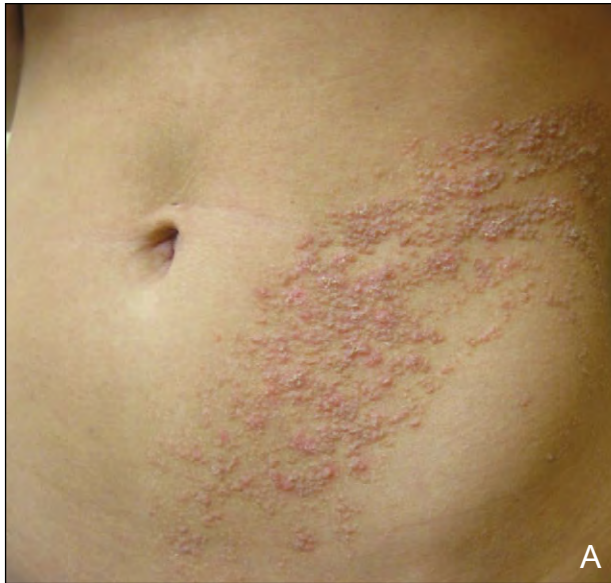## Comment

Epidermal nevi arise from congenital epidermal malformations and are hamartomatous proliferations of the epithelium that commonly occur on the limbs

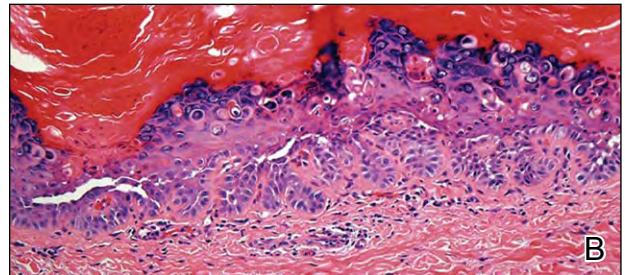
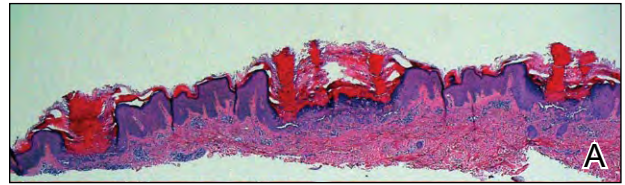
From the Cleveland Clinic Foundation, Ohio. Drs. Khetarpal and Vidimos are from the Department of Dermatology, and Drs. Tarbox and Tuthill are from the Division of Dermatopathology.

The authors report no conflict of interest.

Correspondence: Shilpi Khetarpal, MD, 9500 Euclid Ave, Desk A61, Cleveland, OH 44195 (shilpikhetarpal@gmail.com).



**Figure 1.** Large area of flesh-colored verrucous plaques on the left side of the body of a 25-year-old woman following the lines of Blaschko (A and B).



**Figure 2.** Papillomatous epidermis with 3 individual foci of acantholytic dyskeratosis with the formation of corps ronds and grains (A and B)(H&E; original magnifications  $\times 4$  and  $\times 20$ , respectively).

### Clinical Features

Darier Disease	Acantholytic Dyskeratotic Epidermal Nevi
Autosomal-dominant inheritance	Negative family history
Greasy plaques in seborrheic distribution	Follow lines of Blaschko in linear distribution
Punctate keratoses on palms and soles	Lack of other physical examination findings
Palmar and plantar pits	Younger age at onset
Longitudinal striations on nails	
Older age at onset	

following the lines of Blaschko.<sup>1</sup> They usually present in the first year of life and can cause pruritus, erythema, and scaling, especially when present on the buttocks and lower extremities. Epidermal nevi also can occur in conjunction with other epidermal lesions, such as congenital hypopigmented macules, café au lait patches, and congenital nevocellular nevi.<sup>1</sup>

Ten histologic variants of the epidermal nevus are described in the literature, all sharing a common ectodermal derivation. A majority of the variants

are characterized by acanthosis, papillomatosis, and hyperkeratosis. Less common patterns are acantholytic dyskeratotic epidermal nevi (ADEN), acrokeratosis verruciformis-like (Darier-like), seborrheic keratosis-like, psoriasiform, verrucoid, and porokeratosis-like.<sup>2</sup> Acantholytic dyskeratosis is a histologic pattern characterized by acantholysis of the suprabasal layers of the epidermis with intraepidermal cleft formation and dyskeratotic keratinocytes in the form of corps ronds and grains with overlying parakeratosis and

hyperkeratosis.<sup>3</sup> These histologic findings often are indicative of DD but are not pathognomonic of the condition. This histologic pattern can be seen in other conditions including Grover disease, ADEN (Starink hamartoma), warty dyskeratoma, or acantholytic papular dermatosis.<sup>3</sup>

Our patient's lack of a family history of DD, early-onset disease, and linear presentation along the lines of Blaschko all favored a diagnosis of ADEN versus localized DD.<sup>4</sup> However, it has been suggested that ADEN represents a localized mosaic form of DD.<sup>5</sup> It also has been shown that ADEN can be the result of a somatic mutation in *ATP2A2*, which is the same gene that is defective in DD.<sup>6</sup> Darier disease typically presents at an older age and has a predilection for seborrheic areas, such as the head, neck, and trunk. The Table presents a comparison of DD and ADEN. Classification of ADEN versus mosaicism of DD is still a matter of debate.

## REFERENCES

1. Valencia TD, Swanson NA, Ken LK. Benign epithelial tumors, hamartomas, and hyperplasias. In: Wolff K, Goldsmith LA, Katz SI, et al, eds. *Fitzpatrick's Dermatology in General Medicine*. 7th ed. New York, NY: McGraw-Hill; 2008:1056-1060.
2. Shaffer HC, Schosser R, Phillips C. Acantholytic dyskeratotic epidermal nevus with eccrine differentiation: a case report and review of literature. *J Cutan Pathol*. 2009;36:1001-1004.
3. Bergua P, Puig L, Fernández-Figueras MT, et al. Congenital acantholytic dyskeratotic dermatosis: localized Darier disease or disseminated benign papular acantholytic dermatosis? *Pediatr Dermatol*. 2003;20:262-265.
4. Starink TM, Woerdeman MJ. Unilateral systematized keratosis follicularis. a variant of Darier's disease or an epidermal naevus (acantholytic dyskeratotic epidermal naevus)? *Br J Dermatol*. 1981;105:207-214.
5. Huh WK, Fujiwara K, Takahashi H, et al. Congenital acantholytic dyskeratotic epidermal naevus following Blaschko's lines versus segmental Darier's disease [published online ahead of print March 2, 2007]. *Eur J Dermatol*. 2007;17:130-132.
6. Sakuntabhai A, Dhitavat J, Burge S, et al. Mosaicism for *ATP2A2* causes segmental Darier's disease. *J Invest Dermatol*. 2000;115:1144-1147.