

Addisonian Pigmentation and Vitamin B₁₂ Deficiency: A Case Series and Review of the Literature

Madhukara Jithendriya, DVD, DNB; Sendhil Kumaran, MD, DNB; Ishwara Bhat .P, MD

Practice Points

- Patients presenting with Addisonian pigmentation should be screened for vitamin B₁₂ deficiency.
- Assessment of serum vitamin B₁₂ levels is a reliable and cost-effective method of screening for vitamin B₁₂ deficiency.
- Oral vitamin B₁₂ supplementation is effective in correcting a deficiency state.

Skin changes associated with vitamin B₁₂ deficiency are common. In most cases, patients present primarily with systemic involvement (eg, megaloblastic anemia and/or neurologic effects), and additional cutaneous changes related to the diagnosis are noted as incidental findings. The role of vitamin B₁₂ deficiency in the etiology of Addisonian pigmentation has not been well studied. We discuss the importance of testing vitamin B₁₂ levels in patients who present for evaluation of generalized hyperpigmentation. Various cutaneous changes associated with vitamin B₁₂ deficiency also are reviewed.

Cutis. 2013;92:94-99.

Vitamin B₁₂ deficiency is common in developing countries¹ and may manifest from a fatal disease to a condition diagnosed biochemically during routine screenings. Although vitamin B₁₂ deficiency can have a range of hematologic,

psychiatric, neurologic, dermatologic, and cardiovascular effects, megaloblastic anemia and neurologic manifestations are most commonly described.² Cutaneous manifestations of vitamin B₁₂ deficiency include characteristic pigmentation, vitiligo, angular cheilitis, and hair abnormalities.³ Vegetarians are at a higher risk for developing this deficiency because animal products are the main sources of vitamin B₁₂.⁴ Reports of hyperpigmentation as the primary presenting symptom of vitamin B₁₂ deficiency are sparse in the literature. There have been no studies regarding the incidence of vitamin B₁₂ deficiency in patients presenting primarily with Addisonian pigmentation; a PubMed search of articles indexed for MEDLINE using the terms *Addisonian pigmentation and vitamin B₁₂ deficiency*, *vitamin B₁₂ deficiency*, and *skin and vitamin B₁₂ deficiency* yielded case reports only. We present a case series of patients who were found to be vitamin B₁₂ deficient after initially presenting with Addisonian pigmentation.

Case Series

Nine patients presented with a history of generalized hyperpigmentation. Of these 9 patients, 7 were men and 2 were women (age range, 21–51 years). The demographics and disease parameters for each patient are outlined in the Table. The duration of symptoms ranged from 2 to 12 months, with more than half of patients reporting increased hyperpigmentation in the 6 weeks prior to presentation.

From the Department of Dermatology, Saint John's Medical College Hospital, Bangalore, India.

The authors report no conflict of interest.

Correspondence: Madhukara Jithendriya, DVD, DNB, Department of Dermatology, Saint John's Medical College Hospital, Surjapur Rd, Koramangala Bangalore-560034, Karnataka State, India (madhudoc2009@yahoo.com).

Patient Demographics and Disease Parameters

| Age, y | Gender | Diet | Hb, g/dL ^a | MCV, fL ^b | Vitamin B ₁₂ Level, pg/mL ^c | Serum Cortisol Level, µg/dL ^d | Duration, mo | Other Symptoms |
|--------|--------|--------|-----------------------|----------------------|---|--|--------------|----------------------------|
| 33 | M | Nv | 11.30 | 119 | <50 | 9.65 | 12 | Weakness, numbness of feet |
| 26 | M | Ovoveg | 15.6 | 96 | 57 | 11.01 | 7 | Weakness |
| 25 | F | Veg | 13.8 | 85 | 75 | 8.08 | 6 | Weakness |
| 23 | F | Nv | 11.0 | 121 | 75.2 | 7.83 | 12 | Oral ulcers |
| 22 | M | Veg | 11.2 | 115.5 | <50 | 10.19 | 9 | None |
| 51 | M | Veg | 11.2 | 76.8 | 93 | 9.83 | 3 | Weakness, numbness of feet |
| 23 | M | Veg | 15.4 | 106.4 | <50 | 9.65 | 3 | Weakness, numbness of feet |
| 25 | M | Ovoveg | 13.5 | 114.5 | 82 | 16.47 | 3 | None |
| 21 | M | Veg | 15.0 | 98.6 | 55 | 10.67 | 2 | Oral ulcers |

Abbreviations: Hb, hemoglobin; MCV, mean corpuscular volume; M, male; Nv, nonvegetarian; Ovoveg, ovo-lacto vegetarian; F, female; Veg, lacto-vegetarian.

^aReference range, 13–18 g/dL (male) and 11.5–15.5 g/dL (female).

^bReference range, 76–96 fL.

^cReference range, 180–914 pg/mL (via chemiluminescence).

^dReference range, 6.7–22.6 µg/dL.

Further evaluation revealed that 5 patients had a history of nonspecific generalized weakness and 3 had a history of paresthesia of the feet. All but one patient, who was taking oral metformin for treatment of diabetes, reported no current medications. Two patients had a history of recurrent oral ulcers. There was no history suggestive of malabsorption.

On clinical examination, characteristic Addisonian hyperpigmentation in the form of brownish black discoloration was noted in all patients, with involvement of the face, oral mucosa (Figure 1), and dorsal hands and feet with periungual accentuation. Palmoplantar involvement varied from patchy to diffuse discoloration (Figure 2). Nail discoloration from diffuse hyperpigmentation to longitudinal melanonychia and pigmentation of the onychodermal band

also was noted. A thorough systemic evaluation, including the nervous system, was conducted in all patients and revealed no systemic abnormalities.

Laboratory Evaluation—Serum cortisol levels were well within reference range in all 9 patients. Serum vitamin B₁₂ levels were low in all patients, with values ranging from below the detectable limit of 50 pg/mL to 93 pg/mL via chemiluminescence. Three patients had low hemoglobin with raised mean corpuscular volume values. The Schilling test was not performed, as it was not available at our institution or in surrounding laboratories. All 9 patients were treated with oral methylcobalamin (1000 µg/d). No additional medication was administered. After 4 weeks, all patients showed an 80% decrease in hyperpigmentation. Two patients

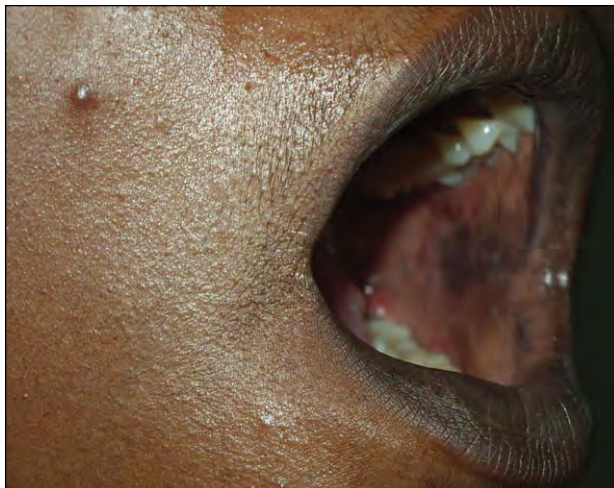

Figure 1. Mucosal pigmentation.

experienced minor adverse effects (ie, mild gastritis and nasal congestion).

Comment

Vitamin B₁₂ (cobalamin) is found only in bacteria, eggs, and animal by-products. The average daily requirement for vitamin B₁₂ in adults is 1 to 3 μg to make up for daily losses. The body stores of vitamin B₁₂ range from 2 to 3 mg (2000 to 3000 μg), which is sufficient for 3 to 4 years without replenishment.⁵ Vitamin B₁₂ exists in a number of different chemical forms and is the cofactor for important enzymes such as methylmalonyl-CoA mutase and methionine synthase.⁵

Although vitamin B₁₂ deficiency generally is associated with people who are strict vegetarians, the condition also can result from malabsorption due to inadequate gastric production or defective functioning of the intrinsic factor. Other conditions that can lead to vitamin B₁₂ deficiency include gastrectomy, wide surgical resection of the terminal ileum, bacterial overgrowth in the small intestine, diverticulitis, celiac disease, Crohn disease, chronic alcoholism, human immunodeficiency virus, *Diphyllobothrium* infestation, giardiasis, and medications such as metformin and colchicine. Additionally, malabsorption of vitamin B₁₂ has been associated with long-term use (>4 years) of H₂-receptor antagonists and proton-pump inhibitors. Among these potential causes for vitamin B₁₂ deficiency, the most common are low dietary intake and malabsorption.⁶

Baker et al⁷ referred to Dr. Bramwell Cook's first description in 1944 of pigmentary changes suggestive of vitamin B₁₂ deficiency. Since then, there have been several anecdotal reports of various cutaneous changes associated with the condition. Baker et al⁸

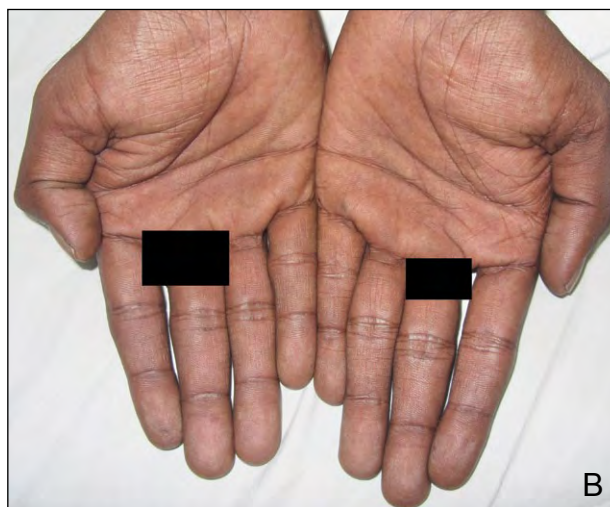
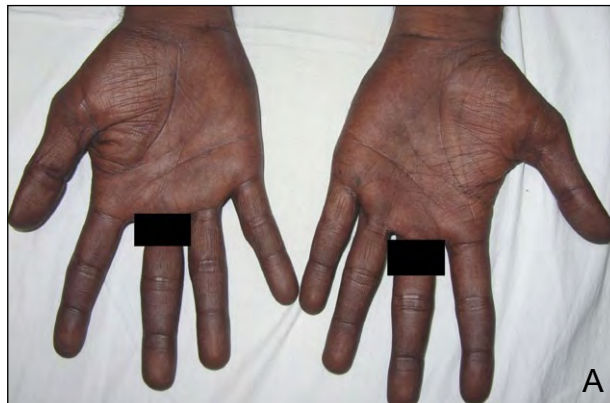

Figure 2. Palmar pigmentation before (A) and after treatment with oral methylcobalamin (B).

described predominant pigmentation of the skin over the dorsal aspect of the interphalangeal joints in patients with tropical sprue and megaloblastic anemia. There is a paucity of reported cases of vitamin B₁₂ deficiency wherein mucocutaneous lesions predate other manifestations. The characteristic reversible, brownish black hyperpigmentation often affects photoexposed sites, dorsal aspects of the hands and feet, knuckles, flexures, mucosa, palmar creases, and nails. Hyperpigmentation related to vitamin B₁₂ deficiency is more common in darker-skinned patients.³ Vitiligo also has been associated with vitamin B₁₂ deficiency, which is now being disputed, as recent analysis has not shown any difference in vitamin B₁₂ levels between vitiligo and control groups.⁹ Of note, none of our patients had vitiligo. Pigmentary changes are less prominent in patients of European descent and usually are spotty or reticulated rather than generalized.¹⁰ In most patients presenting with Addisonian pigmentation, investigation often

includes serum cortisol levels only, and vitamin B₁₂ levels seldom are assessed. Studies have shown that vitamin B₁₂ deficiency is widely prevalent in the Indian community, both due to dietary and nondietary factors, with only a few patients having overt systemic involvement. The skin, on the other hand, may be the site of the first manifestations of the condition, highlighting the importance of vitamin B₁₂ testing in the early diagnosis of this condition.

The mechanism of reversible hyperpigmentation in vitamin B₁₂ deficiency is unclear. Electron microscopic findings in biopsies have suggested that hyperpigmentation is not due to a defect in melanin transport but is secondary to an increase in melanin synthesis.¹¹ Vitamin B₁₂ deficiency causes a decrease in the cell's ability to synthesize DNA without affecting RNA and protein synthesis.¹² It has been postulated that vitamin B₁₂ deficiency lowers the intracellular redox potential with a concomitant decrease in the reduced glutathione to oxidized glutathione ratio. Once the tyrosinase-inhibiting effect of reduced glutathione has diminished, the epidermal melanocytes are then stimulated to produce melanin.¹³ Another hypothesis is that high intracellular tyrosine levels, which may be found in vitamin B₁₂ deficiency, produce excess DOPA, presumably by mass effect inducing excess melanin production.¹²

Another prominent cutaneous finding of vitamin B₁₂ deficiency described in the literature is graying hair,^{14,15} which is paradoxical to the hyperpigmentation of the skin. It could be related to an altered cyanocobalamin metabolism in genetically susceptible individuals.¹⁵ It has been shown that gray hair has undergone a reduction in the number of melanin granules; this decrease in melanin synthesis appears to be associated with a decrease in tyrosinase activity.¹⁶ In our case series, however, graying hair was observed in only 1 patient.

Reddish brown hyperpigmentation confined to the lateral surfaces of the legs,¹⁶ polymorphous rashes on photoexposed areas,³ and secondary organic delusion of parasitosis¹⁷ also have been described in association with vitamin B₁₂ deficiency. Nail changes such as pigmentation and bluish discoloration also may be seen.¹⁰ Four of our patients had either diffuse or longitudinal melanonychia or both. An interesting finding was pigmentation of the onychodermal band in some of the affected nails.

Mucosal manifestations of vitamin B₁₂ deficiency are varied and may range from glossodynia to diffuse erythematous mucositis and recurrent ulcers.^{18,19} Hunter glossitis (or Moeller glossitis) is the most classic form of mucosal manifestation, which can occur in up to 25% of cases and is characterized by diffuse, beefy red erythema and atrophy of the lingual papillae

affecting more than half of the tongue.¹⁹ Hunter glossitis has 2 stages: an inflammatory stage with bright red plaques, and a late atrophic stage characterized by papillary atrophy. The linear, erythematous, depapillated lesions on the tongue and hard palate may be a specific and early manifestation of vitamin B₁₂ deficiency.¹⁹ These oral changes may occur in the absence of symptomatic anemia or macrocytosis.²⁰ Pigmentation of the mucosa was observed in all of our patients, and 2 patients reported recurrent oral ulcers.

Assessment of serum vitamin B₁₂ levels generally is considered to be a sufficiently robust and cost-effective method of ruling out vitamin B₁₂ deficiency in the majority of patients suspected of having vitamin B₁₂ deficiency.⁵ However, normal concentrations of vitamin B₁₂ have been reported in patients with overt deficiency. In such cases, serum homocysteine and methylmalonic acid levels are considered to be more reliable indicators of vitamin B₁₂ deficiency.²¹

Four of our patients had low hemoglobin levels; 6 had a macrocytic blood picture; and another 3 reported occasional tingling of the feet without any sensory, motor, or proprioceptive deficits. Variable manifestations occur because vitamin B₁₂ deficiency may affect 1 cell line before involving another in a given patient.^{22,23} Mean corpuscular volume levels were normal in 3 (33.3%) of our patients, as described in earlier studies.^{23,24} High mean corpuscular volume has low sensitivity in the diagnosis of vitamin B₁₂ deficiency, as a pooled analysis conducted by Oosterhuis et al²⁵ showed that the sensitivity was 30% for low serum vitamin B₁₂ concentration, 58% for deficiency, and 75% for deficiency in patients with anemia, which is consistent with our findings.

Another common cause of vitamin B₁₂ deficiency is malabsorption. It takes 2 to 5 years to develop vitamin B₁₂ deficiency, even in the presence of severe malabsorption.³ None of our patients showed features of malabsorption.

Treatment of vitamin B₁₂ deficiency depends on the underlying causes. Blocked or reduced oral bioavailability, such as in patients with pernicious anemia, requires injections of vitamin B₁₂. However, if there are no obvious reasons for an injection (eg, in cases of ileal resection where absorption of oral vitamin B₁₂ in the gut is likely to be impaired), oral substitution is a sensible strategy. Dosage recommendations can vary, but 1 to 2 mg administered daily at the start of treatment and then tapered to weekly and later monthly generally is recommended.⁴ All of our patients responded well to oral methylcobalamin therapy; studies have shown that oral vitamin B₁₂ is as effective as intramuscular injections.²⁶⁻²⁸

Vitamin B₁₂ generally is well tolerated; however, there have been reports of sclerodermoid skin

changes,²⁹ acneform eruptions,^{30,31} Nicolau syndrome,³² urticarial reactions,³³ and anaphylaxis³⁴ associated with injectable forms. Patients who are allergic to hydroxocobalamin may tolerate cynaocobalamin, and vice versa.³³⁻³⁵ High doses of hydroxocobalamin are recommended as an antidote for cyanide poisoning, which may impart a harmless and transient reddish color to the skin and urine.³⁶ In our patients, no major adverse effects were reported.

A probable limitation of our study was the nonestimation of folate levels, as low folate levels also can produce pigmentary changes. It also should be noted that serum folate levels tend to be increased in patients with vitamin B₁₂ deficiency, presumably because of impairment of the methionine synthase pathway and accumulation of 5-methyltetrahydrofolate, the principal form of folate in the serum. For this reason, it is recommended that red blood cell folate levels are measured³⁷; however, this method of testing was unavailable at our institute. Despite this limitation, the rapid and gratifying response to oral vitamin B₁₂ therapy that was observed in our patients makes this possibility an unlikely etiology in our particular case series.

Our case series highlights the importance of assessing vitamin B₁₂ levels in addition to serum cortisol levels in patients with Addisonian pigmentation. Overt systemic manifestations of vitamin B₁₂ deficiency may not always be observed. We propose that there may be a small patient population that is genetically prone to developing pigmentary changes prior to the onset of other systemic manifestations in the setting of vitamin B₁₂ deficiency. It is important that clinicians are aware of this condition, especially in developing countries where dietary deficiencies leave a large segment of the population at risk for vitamin B₁₂ deficiency.

Conclusion

Addisonian pigmentation is not an uncommon presentation of vitamin B₁₂ deficiency in clinical practice. A high percentage of the population in India practices a vegan diet, which also is popular in the West, and predisposes patients to vitamin B₁₂ deficiency. To avoid serious complications from this easily treatable condition, it is important for physicians to have a high index of suspicion in recognizing patients with pigmentary changes who also may be vitamin B₁₂ deficient.

REFERENCES

- Allen LH. How common is vitamin B-12 deficiency [published online ahead of print December 30, 2008]? *Am J Clin Nutr*. 2009;89:693S-696S.
- Hvas AM, Nexø E. Diagnosis and treatment of vitamin B₁₂ deficiency—an update [published online ahead of print October 17, 2006]. *Haematologica*. 2006;91:1506-1512.
- Kannan R, Ng MJ. Cutaneous lesions and vitamin B₁₂ deficiency: an often-forgotten link [comment in *Can Fam Physician*. 2008;54:978-979]. *Can Fam Physician*. 2008;54:529-532.
- Herrmann W, Obeid R. Causes and early diagnosis of vitamin B₁₂ deficiency [published online ahead of print October 3, 2008]. *Dtsch Arztebl Int*. 2008;105:680-685.
- Hoffbrand AV. Megaloblastic anemias. In: Fauci AS, Braunwald E, Kasper DL, et al, eds. *Harrison's Principles of Internal Medicine*. 17th ed. New York, NY: McGraw-Hill; 2008:643-651.
- Allen LH. Causes of vitamin B₁₂ and folate deficiency. *Food Nutr Bull*. 2008;29(suppl 2):S20-S34, discussion S35-S37.
- Baker SJ, Ignatius M, Johnson S, et al. Pigmentation and vitamin B₁₂ deficiency. *Br Med J*. 1963;2:1205.
- Baker SJ, Ignatius M, Johnson S, et al. Hyperpigmentation of skin. a sign of vitamin-B12 deficiency. *Br Med J*. 1963;1:1713-1715.
- Gonul M, Cakmak SK, Soylu S, et al. Serum vitamin B₁₂, folate, ferritin and iron levels in Turkish patients with vitiligo. *Indian J Dermatol Venereol Leprol*. 2010;76:448.
- Carmel R. Hair and fingernail changes in acquired and congenital pernicious anemia. *Arch Intern Med*. 1985;145:484-485.
- Mori K, Ando I, Kukita A. Generalized hyperpigmentation of the skin due to vitamin B₁₂ deficiency. *J Dermatol*. 2001;28:282-285.
- Lee SH, Lee WS, Whang KC, et al. Hyperpigmentation in megaloblastic anemia. *Int J Dermatol*. 1988;27:571-575.
- Lin SH, Sourial NA, Lu KC, et al. Imerslund-Grasbeck syndrome in a Chinese family with distinct skin lesions refractory to vitamin B₁₂. *J Clin Pathol*. 1994;47:956-958.
- Noppakun N, Swasdikul D. Reversible hyperpigmentation of skin and nails with white hair due to vitamin B₁₂ deficiency. *Arch Dermatol*. 1986;122:896-899.
- Niiyama S, Mukai H. Reversible cutaneous hyperpigmentation and nails with white hair due to vitamin B₁₂ deficiency [published online ahead of print October 19, 2007]. *Eur J Dermatol*. 2007;17:551-552.
- Aroni K, Anagnostopoulou K, Tsagrani E, et al. Skin hyperpigmentation and increased angiogenesis secondary to vitamin B₁₂ deficiency in a young vegetarian woman. *Acta Derm Venereol*. 2008;88:191-192.
- Kumar T, Singh J. Delusion of parasitosis: an atypical initial presentation of multiple sclerosis. *Hong Kong J Psychiatry*. 2009;19:42-45.
- Pontes HA, Neto NC, Ferreira KB, et al. Oral manifestations of vitamin B₁₂ deficiency: a case report. *J Can Dent Assoc*. 2009;75:533-537.
- Graells J, Ojeda RM, Muniesa C, et al. Glossitis with linear lesions: an early sign of vitamin B₁₂ deficiency. *J Am Acad Dermatol*. 2009;60:498-500.
- Field EA, Speechley JA, Rugman FR, et al. Oral signs and symptoms in patients with undiagnosed vitamin B₁₂ deficiency. *J Oral Pathol Med*. 1995;24:468-470.

21. Oh R, Brown DL. Vitamin B₁₂ deficiency. *Am Fam Physician*. 2003;67:979-986.
22. Herbert V. Staging vitamin B₁₂ (cobalamin) status in vegetarians. *Am J Clin Nutr*. 1994;59(5, suppl 1):S1213-S1222.
23. Aaron S, Kumar S, Vijayan J, et al. Clinical and laboratory features and response to treatment in patients presenting with vitamin B₁₂ deficiency-related neurological syndromes. *Neurol India*. 2005;53:55-58.
24. Dong A, Scott SC. Serum vitamin B₁₂ and blood cell values in vegetarians. *Ann Nutr Metab*. 1982;26:209-216.
25. Oosterhuis WP, Niessen RW, Bossuyt PM, et al. Diagnostic value of the mean corpuscular volume in the detection of vitamin B₁₂ deficiency. *Scand J Clin Lab Invest*. 2000;60:9-18.
26. Kripke C. Is oral vitamin B₁₂ as effective as intramuscular injection? *Am Fam Physician*. 2006;73:65.
27. Butler CC, Vidal-Alaball J, Cannings-John R, et al. Oral vitamin B₁₂ versus intramuscular vitamin B₁₂ for vitamin B₁₂ deficiency: a systematic review of randomized controlled trials. *Fam Pract*. 2006;23:279-285.
28. Andrès E, Fothergill H, Mecili M. Efficacy of oral cobalamin (vitamin B₁₂) therapy. *Expert Opin Pharmacother*. 2010;11:249-256.
29. Ho J, Rothchild YH, Sengelmann R. Vitamin B₁₂-associated localized scleroderma and its treatment. *Dermatol Surg*. 2004;30:1252-1255.
30. Dupré A, Albarel N, Bonafe JL, et al. Vitamin B-12 induced acne. *Cutis*. 1979;24:210-211.
31. Sherertz EF. Acneiform eruption due to "megadose" vitamins B₆ and B₁₂. *Cutis*. 1991;48:119-120.
32. Luton K, Garcia C, Poletti E, et al. Nicolau Syndrome: three cases and review. *Int J Dermatol*. 2006;45:1326-1328.
33. Heyworth-Smith D, Hogan PG. Allergy to hydroxycobalamin, with tolerance of cyanocobalamin. *Med J Aust*. 2002;177:162-163.
34. Vidal C, Lorenzo A. Anaphylactoid reaction to hydroxycobalamin with tolerance of cyanocobalamin. *Postgrad Med J*. 1998;74:702.
35. Moloney FJ, Hughes R, O'Shea D, et al. Type I immediate hypersensitivity reaction to cyanocobalamin but not hydroxycobalamin. *Clin Exp Dermatol*. 2008;33:412-414.
36. Cescon DW, Juurlink DN. Discoloration of skin and urine after treatment with hydroxocobalamin for cyanide poisoning. *CMAJ*. 2009;180:251.
37. Aslinia F, Mazza JJ, Yale SH. Megaloblastic anemia and other causes of macrocytosis. *Clin Med Res*. 2006;4:236-241.