

# Efinaconazole Solution 10%: Topical Antifungal Therapy for Toenail Onychomycosis

Antonella Tosti, MD

## Practice Points

- Toenail onychomycosis is a common disease with limited treatment options, as treatment failures and relapses frequently are encountered.
- Many patients experience long-term disease that affects multiple toenails and causes substantial discomfort and pain.
- Although many patients prefer topical therapies, treatment efficacy with ciclopirox and amorolfine lacquers has been disappointing.

*Toenail onychomycosis is a common disease with limited treatment options, as treatment failures and relapses frequently are encountered. Many patients experience long-term disease that affects multiple toenails and causes substantial discomfort and pain. Although many patients prefer topical therapies, treatment efficacy with ciclopirox and amorolfine lacquers has been disappointing.*

*Efinaconazole solution 10% is a new triazole antifungal agent specifically developed for the treatment of onychomycosis. Efinaconazole has shown a broad spectrum of antifungal activity in vitro and is more potent than ciclopirox against common onychomycosis pathogens. It has lower keratin binding and quicker drug release from keratin than ciclopirox and amorolfine and exhibits remarkably greater in vivo activity. Efinaconazole has limited or no potential for drug interactions and a low resistance potential. Efinaconazole*

*provides a viable alternative to oral therapy for the treatment of toenail onychomycosis.*

*Cutis. 2013;92:203-208.*

Onychomycosis, most frequently seen in toenails, is a common growing problem in dermatology practice and can be difficult to treat.<sup>1,2</sup> It is not self-healing; rather it often is the source of more widespread disease.<sup>3</sup> Onychomycosis can have a substantial impact on the patient and also can spread to his/her family members.<sup>4,6</sup> Toenail appearance is a real concern, as it can negatively impact the patient's quality of life and occasionally can result in remarkable pain and discomfort.<sup>4</sup> Many patients have long-term disease that can affect several toenails.<sup>7</sup> Although the true burden of the disease is unknown, the patient's desire to cure his/her affected nails is clear.<sup>4,8</sup> The objective of this article is to briefly review onychomycosis and current treatment options as well as to provide an overview of a new topical treatment, efinaconazole solution 10%.

## Overview of Onychomycosis

Onychomycosis usually is caused by dermatophyte fungi (*Trichophyton rubrum* and *Trichophyton mentagrophytes* in 80%–90% of cases)<sup>1,9-11</sup> but can be caused by nondermatophyte fungi, mainly

From the Department of Dermatology & Cutaneous Surgery, Leonard M. Miller School of Medicine, University of Miami, Florida. Dr. Tosti was an advisor to Medicis, a division of Valeant Pharmaceuticals North America LLC.

Correspondence: Antonella Tosti, MD, Department of Dermatology & Cutaneous Surgery, Leonard M. Miller School of Medicine, University of Miami, Miami, FL 33136 (atosti@med.miami.edu).

*Scopulariopsis brevicaulis*, *Fusarium* species, or *Aspergillus* species. Nondermatophyte infections are increasingly prevalent in some countries, particularly in Europe and South America.<sup>12</sup>

Distal lateral subungual onychomycosis (DLSO) is the most common form of toenail onychomycosis in which the fungus, usually *T rubrum*, invades the nail bed at the distal and lateral edges.<sup>13</sup> Hyperkeratosis occurs under the nail, resulting in detachment from the nail bed and subungual thickening. Some degree of tinea pedis almost always is present.<sup>14</sup> Other clinical types include superficial onychomycosis (white or black), originating on the superficial nail plate or beneath the proximal nail fold and resulting in a powdery white, patchy discoloration of the nail surface or transverse striae with severity and spread from a complex host-parasite relationship<sup>15</sup>; proximal subungual onychomycosis with invasion through the proximal margin embedded within the proximal nail fold, resulting in the infection slowly extending distally (commonly coexists with immunodeficiency); endonyx onychomycosis with lamellar splitting of the nail, discoloration, and internal invasion of the nail plate; and total dystrophic onychomycosis, the end stage commonly seen in DLSO in which the nail plate crumbles away and the nail bed becomes thickened, ridged, and often covered with debris.<sup>14</sup> Two additional classifications—mixed pattern onychomycosis and onychomycosis secondary to other nail disease—also have been proposed.<sup>13</sup>

Treatment options are limited both in the number of available agents and their low to moderate efficacy. Treatment selection depends on the disease type, the number of affected nails, and the severity of nail involvement.<sup>16</sup> The proximity of the infection to the nail matrix, degree of subungual hyperkeratosis, and presence of dermatophytoma are important considerations when assessing disease severity and selecting therapy.<sup>17</sup>

Relapse and reinfection are common, occurring in 20% to 25% of cases; therefore, new therapeutic options are needed.<sup>18</sup> Current treatments range from topical care with no systemic side effects but limited efficacy to systemic treatments that are more effective but can be limited in some patients due to drug-drug interactions (DDIs) and safety concerns, most notably hepatotoxicity.<sup>19,20</sup> In some cases, topical treatments and nail avulsion<sup>21</sup> may be combined with oral antifungals to decrease adverse effects and duration of therapy.<sup>22</sup>

Topical therapy is used in mild to moderate DLSO, in initial treatment of classic superficial onychomycosis,<sup>14</sup> and in patients cured with systemic therapy to prevent recurrence.<sup>23</sup> Although many patients may prefer topical treatments, results with ciclopirox and

amorolfine lacquers (amorolfine lacquer is not available in the United States) have been disappointing, probably due to limited penetration through the diseased nail.<sup>24,25</sup> Efinaconazole solution 10% is a triazole antifungal agent specifically developed for topical treatment of mild to moderate DLSO.<sup>26,27</sup>

## Nonclinical Development

A topical antifungal must penetrate through the dense keratinized nail plate into the deeper nail layers and nail bed and be present in its free form to be effective. Keratin binding can reduce the availability of the free active drug.<sup>28,29</sup> Antifungal drugs possess a high affinity to keratin that can have a deleterious effect on efficacy.<sup>30</sup> Keratin binding also can decrease drug penetration to the deeper nail layers, even after repeated topical application. Although keratin binding can result in persistent drug concentrations in the nail, it is only beneficial if the drug is released at a sufficient concentration and rate so as not to compromise efficacy.

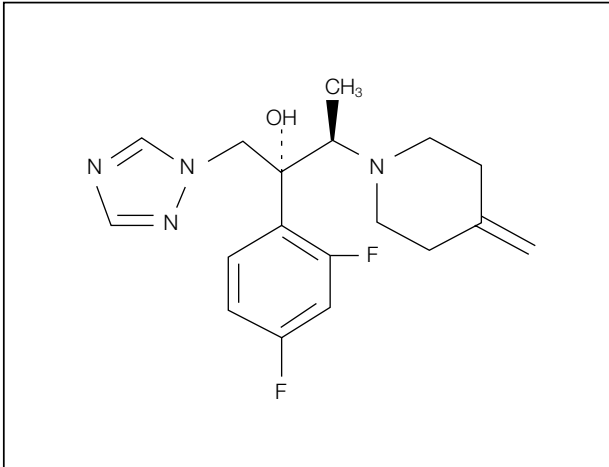
Although in vitro and in vivo fungicidal activities are not necessarily predictive of clinical outcome, they are important indicators of therapeutic success. With the greater emergence of nondermatophytes and yeast in onychomycosis, a broad spectrum of activity is ideal.

## Pharmacokinetic Profile

Topical efinaconazole 10% is a clear, low-surface-tension solution. Its low systemic exposure means that DDIs are unlikely.<sup>31</sup> Two single-center, open-label studies of healthy participants and participants with severe onychomycosis assessed the DDI potential of efinaconazole by characterizing its pharmacokinetic profile and systemic exposure. Topical application of efinaconazole solution 10% resulted in low systemic exposures to efinaconazole in patients with severe onychomycosis as well as healthy participants.<sup>32</sup> The likelihood of an in vivo DDI with efinaconazole was considered remote, especially because efinaconazole is highly plasma protein bound and the model (validated LC-MS/MS method) takes into account both free and bound forms.<sup>31</sup>

## Mechanism of Action and Unique Physicochemical Properties

The unique physicochemical properties of efinaconazole and the nature of its vehicle formulation are important contributors to its clinical success. Efinaconazole is a triazole antifungal agent (Figure 1) that inhibits fungal lanosterol 14 $\alpha$  demethylase involved in ergosterol biosynthesis at concentrations below its minimum inhibitory concentration (MIC). Efinaconazole



**Figure 1.** Efinaconazole—(2R,3R)-2-(2,4-difluorophenyl)-3-(4-methylidenepiperidin-1-yl)-1-(1,2,4-triazol-1-yl)butan-2-ol—structural formula.

is 4.8 times more potent in *T mentagrophytes* than itraconazole and 7.3 times more potent in *Candida albicans* than clotrimazole.<sup>33</sup>

Efinaconazole solution 10% showed a considerably lower keratin-binding rate and faster drug release after 5 washings (85.7% bound with 46% released) when compared to amorolfine (98.1% bound with 6.9% released) and ciclopirox (99.3% bound with 2.4% released). Keratin affinity influences drug permeation and was much greater with efinaconazole solution 10% than ciclopirox; amorolfine was not detectable.<sup>32</sup>

### Broad-Spectrum In Vitro and Superior Activity In Vivo

Efinaconazole demonstrated more potent antifungal activity in vitro against *T rubrum* and *T mentagrophytes* (MIC<sub>90</sub>, 0.008–0.015 µg/mL) and *C albicans* (MIC<sub>50</sub>, 0.004 µg/mL), the most common causative pathogens, compared to currently marketed onychomycosis antifungals.<sup>34</sup> Against *T rubrum* and *T mentagrophytes*, efinaconazole had comparable activity to amorolfine and terbinafine (1- to 4-fold) and higher activity than ciclopirox and itraconazole (8- to 64-fold). Efinaconazole was more potent in inhibiting *C albicans* than terbinafine, ciclopirox, itraconazole, and amorolfine. Efinaconazole has a broad spectrum of activity, being effective against *Trichophyton*, *Microsporum*, *Epidermophyton*, *Acremonium*, *Fusarium*, *Paecilomyces*, *Pseudallescheria boydii*, *Scopulariopsis*, *Aspergillus*, *Cryptococcus*, *Trichosporon*, and *Candida* species.<sup>34</sup>

Efinaconazole solution 10% was significantly superior to amorolfine ( $P < .001$ ) and ciclopirox ( $P < .01$ ) nail lacquers in decreasing the number of dermatophytes in an in vivo guinea pig model

of onychomycosis.<sup>32</sup> In vitro studies suggested low potential for antibiotic resistance.<sup>34,35</sup>

### Nonclinical Toxicology

Efinaconazole and efinaconazole solution 10% were well tolerated following chronic dosing in rats via subcutaneous injection and minipigs via dermal application, respectively; only minor vehicle-related skin toxicity was observed in minipigs.<sup>36</sup> There was no systemic toxicity at plasma efinaconazole exposures of at least 70-fold higher than in onychomycosis patients.<sup>37</sup> Efinaconazole was not mutagenic or clastogenic in in vitro and in vivo assays and was not oncogenic in a 2-year dermal carcinogenicity study in mice.<sup>36</sup>

Efinaconazole elicits “azole class effect” embryofetal and early postnatal mortality at high, maternally toxic doses. There is no evidence that efinaconazole is teratogenic, unlike some other antifungal agents, or that it affects fertility.<sup>36</sup>

### Clinical Studies

Two identical 52-week, prospective, multicenter, randomized, double-blind studies of 1655 participants (age range, 18–70 years) assessed the safety and efficacy of efinaconazole solution 10% in the treatment of toenail onychomycosis. Participants had mild to moderate toenail DLSO (20%–50% clinical involvement of the target toenail).<sup>27</sup>

For study 1, complete cure rates at week 52 were 17.8% (117/656) with efinaconazole solution 10% and 3.3% (7/214) with vehicle ( $P < .001$ ); for study 2, complete cure rates were 15.2% (88/580) and 5.5% (11/201), respectively ( $P < .001$ ) (Table 1)(Figure 2).<sup>27</sup> Mycologic cure rates (combined for both studies) at week 52 were 54.4% (672/1236) with efinaconazole solution 10% compared to 16.9% (70/415) with vehicle ( $P < .001$ )(Table 2). More participants treated with efinaconazole solution 10% (25.0% [309/1236]) achieved complete or almost complete cure compared to vehicle (7.2% [30/415])( $P < .001$ )(Table 2). More than 40% (527/1236) of participants treated with efinaconazole solution 10% were considered treatment successes compared to 16.1% (67/415) with vehicle ( $P < .001$ )(Table 2).<sup>27</sup>

Related adverse events reported within 48 weeks of treatment and in at least 1% of participants treated with efinaconazole solution 10% or vehicle in both studies are shown in Table 3.<sup>38</sup> In general, these adverse events were mild and transient and did not lead to study discontinuation.<sup>27</sup>

### Conclusion

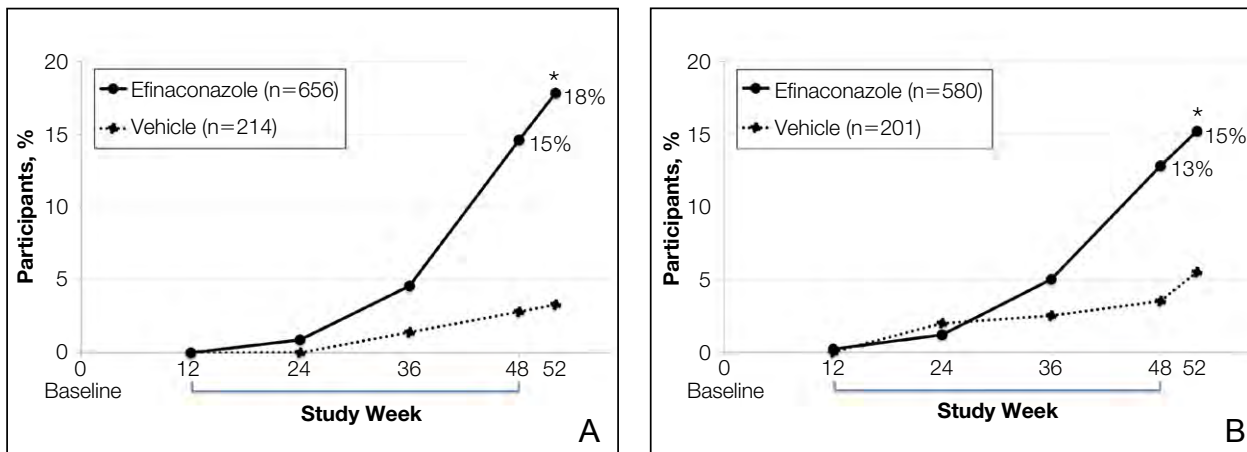
Onychomycosis is a chronic progressive disease with a high prevalence and burden of illness. There is a

Table 1.

**Complete Cure With Efinaconazole Solution 10% (Intention-to-Treat Population)**

	Study 1		Study 2	
	Efinaconazole Solution 10% (n=656)	Vehicle (n=214)	Efinaconazole Solution 10% (n=580)	Vehicle (n=201)
Complete cure at week 52, n (%)	117 (17.8)	7 (3.3)	88 (15.2)	11 (5.5)

Data from Elewski et al.<sup>27</sup>



**Figure 2.** Primary efficacy end point (complete cure) over 52 weeks in study 1 (A) and study 2 (B). Asterisk indicates  $P < .001$ . Adapted from the *Journal of the American Academy of Dermatology*, Copyright 2013, with permission from Elsevier.<sup>27</sup>

Table 2.

**Combined Secondary Efficacy Results With Efinaconazole Solution 10% (Intention-to-Treat Population)**

	Efinaconazole Solution 10% (n=1236)	Vehicle (n=415)
Mycologic cure, <sup>a</sup> n (%)	672 (54.4)	70 (16.9)
Complete or almost complete cure, <sup>b</sup> n (%)	309 (25.0)	30 (7.2)
Treatment success, <sup>c</sup> n (%)	527 (42.6)	67 (16.1)

<sup>a</sup>Mycologic cure is defined as negative potassium hydroxide examination and negative fungal culture of the target nail specimen.

<sup>b</sup>A complete or almost complete cure is defined as  $\leq 5\%$  affected target nail area in addition to mycologic cure.

<sup>c</sup>Treatment success is defined as  $\leq 10\%$  affected target nail area.

Data from Elewski et al.<sup>27</sup>

Table 3.

**Treatment-Related Adverse Events<sup>a</sup>**

	<b>Efinaconazole Solution 10% (n=1227)</b>	<b>Vehicle (n=413)</b>
Application-site dermatitis, n (%)	26 (2.1)	1 (0.2)
Application-site vesicles, n (%)	18 (1.5)	0 (0)

<sup>a</sup>Reported by at least 1% of participants treated for up to 48 weeks for studies 1 and 2 (safety population).

Data from Joseph et al.<sup>38</sup>

real medical need for an effective topical treatment. Efinaconazole solution 10% is a new triazole antifungal specifically developed for the topical treatment of mild to moderate DLSO, the most common presentation of onychomycosis.

Efinaconazole has a broad spectrum of antifungal activity in vitro and is more potent in vivo than ciclopirox and amorolfine against common onychomycosis pathogens. As a result, efinaconazole solution 10% should be ideally suited for topical treatment of dermatophyte, nondermatophyte, and mixed infections.

Successful topical treatment of onychomycosis has been a challenge. Reported mycologic (32%) and complete cure (7.5%) rates with ciclopirox have been disappointing.<sup>24</sup>

The physicochemical properties of the uniquely formulated efinaconazole solution 10% undoubtedly contribute to its efficacy in the topical treatment of onychomycosis. Efinaconazole solution 10% provides a viable alternative to oral therapy. Mycologic and complete cure rates are comparable to those seen with oral itraconazole and have been shown to be 2- to 3-fold greater than those reported with ciclopirox lacquer.<sup>24</sup>

**Acknowledgment**—The author would like to thank Brian Bulley, MSc, of Inergy Limited, Lindfield, West Sussex, England, for his assistance with the preparation of the manuscript. Medicis, a division of Valeant Pharmaceuticals North America LLC, funded Inergy Limited's activities pertaining to this manuscript.

**REFERENCES**

- Gupta AK, Jain HC, Lynde CW, et al. Prevalence and epidemiology of onychomycosis in patients visiting physicians' offices: a multicenter Canadian survey of 15,000 patients. *J Am Acad Dermatol.* 2000;43(2, pt 1): 244-248.
- Szepietowski JC, Reich A, Garlowska E, et al. Factors influencing coexistence of toenail onychomycosis with tinea pedis and other dermatomycoses: a survey of 2761 patients. *Arch Dermatol.* 2006;142:1279-1284.
- Seebacher C, Brasch J, Abeck D, et al. Onychomycosis. *Mycoses.* 2007;50:321-327.
- Schein JR, Gause D, Stier DM, et al. Onychomycosis. baseline results of an observational study. *J Am Pod Med Assoc.* 1997;87:512-519.
- Scher RK. Onychomycosis: a significant medical disorder. *J Am Acad Dermatol.* 1996;35(3, pt 2):S2-S5.
- Milobratović D, Janković S, Vukičević J, et al. Quality of life in patients with toenail onychomycosis [published online ahead of print March 18, 2013]. *Mycoses.* 2013;56:543-551.
- Assaf RR, Elewski BE. Intermittent fluconazole dosing in patients with onychomycosis: results of a pilot study. *J Am Acad Dermatol.* 1996;35(2, pt 1):216-219.
- Drake L. Quality of life issues for patients with fungal nail infections. *AIDS Patient Care.* 1995;9(suppl 1):S15-S17.
- Loo DS. Onychomycosis in the elderly: drug treatment options. *Drugs Aging.* 2007;24:293-302.
- Foster KW, Ghannoum MA, Elewski BE. Epidemiologic surveillance of cutaneous fungal infection in the United States from 1999 to 2002. *J Am Acad Dermatol.* 2004;50:748-752.
- Vender RB, Lynde CW, Poulin Y. Prevalence and epidemiology of onychomycosis. *J Cutan Med Surg.* 2006;10 (suppl 2):S28-S33.
- Gupta AK, Drummond-Main C, Cooper EA, et al. Systematic review of nondermatophyte mold onychomycosis: diagnosis, clinical types, epidemiology, and treatment [published online ahead of print August 4, 2011]. *J Am Acad Dermatol.* 2012;66:494-502.
- Hay RJ, Baran R. Onychomycosis: a proposed revision of the clinical classification [published online ahead of print April 17, 2011]. *J Am Acad Dermatol.* 2011;65:1219-1227.
- Rogers P, Bassler M. Treating onychomycosis. *Am Fam Physician.* 2001;63:663-672, 677-678.

15. Piraccini BM, Tosti A. White superficial onychomycosis: epidemiological, clinical, and pathological study of 79 patients. *Arch Dermatol.* 2004;140:696-701.
16. Iorizzo M, Piraccini BM, Tosti A. Today's treatments options for onychomycosis [in English, German][published online ahead of print August 25, 2010]. *J Dtsch Dermatol Ges.* 2010;8:875-879.
17. Carney C, Tosti A, Daniel R, et al. A new classification system for grading the severity of onychomycosis: Onychomycosis Severity Index. *Arch Dermatol.* 2011;147:1277-1282.
18. Gupta AK, Simpson FC. New therapeutic options for onychomycosis [published online ahead of print April 25, 2012]. *Expert Opin Pharmacother.* 2012;13:1131-1142.
19. Baran R, Sigurgeirsson B, de Berker D, et al. A multicentre, randomized, controlled study of the efficacy, safety and cost-effectiveness of a combination therapy with amorolfine nail lacquer and oral terbinafine compared with oral terbinafine alone for the treatment of onychomycosis with matrix involvement [published online ahead of print June 6, 2007]. *Br J Dermatol.* 2007;157:149-157.
20. Fungal nail infections: diagnosis and management. *Prescribe Int.* 2009;18:26-30.
21. Lahfa M, Bulai-Livideanu C, Baran R, et al. Efficacy, safety and tolerability of an optimized avulsion technique with onyster® (40% urea ointment with plastic dressing) ointment compared to bifonazole-urea ointment for removal of the clinically infected nail in toenail onychomycosis: a randomized evaluator-blinded controlled study [published online ahead of print March 1, 2013]. *Dermatology.* 2013;226:5-12.
22. Jennings MB, Pollak R, Harkless LB, et al. Treatment of toenail onychomycosis with oral terbinafine plus aggressive debridement: IRON-CLAD, a large, randomized, open-label, multicenter trial. *J Am Podiatr Med Assoc.* 2006;96:465-473.
23. Tosti A. Onychomycosis treatment & management. <http://emedicine.medscape.com/article/1105828-treatment>. Updated February 15, 2013. Accessed August 21, 2013.
24. Gupta AK, Joseph WS. Ciclopirox 8% nail lacquer in the treatment of onychomycosis of the toenails in the United States. *J Am Podiatr Med Assoc.* 2000;90:495-501.
25. Bohn M, Kraemer K. The dermatopharmacologic profile of ciclopirox 8% nail lacquer. *J Am Podiatr Med Assoc.* 2000;90:491-494.
26. Tschen EH, Bucko AD, Oizumi N, et al. Efinaconazole solution in the treatment of toenail onychomycosis: a phase 2 multicenter, randomized, double-blind study. *J Drugs Dermatol.* 2013;12:186-192.
27. Elewski BE, Rich P, Pollak R, et al. Efinaconazole 10% solution in the treatment of toenail onychomycosis: two phase III multicenter, randomized, double-blind studies [published online ahead of print November 20, 2012]. *J Am Acad Dermatol.* 2013;68:600-608.
28. Hashiguchi T. Retention capacity of topical imidazole antifungal agents in the skin. *Int J Pharm.* 1998;161:195-204.
29. Narasimha Murthy S, Wiskirchen DE, Bowers CP. Iontophoretic drug delivery across human nail. *J Pharm Sci.* 2007;96:305-311.
30. Tatsumi Y, Yokoo M, Arika T, et al. In vitro antifungal activity of KP-103, a novel triazole derivative, and its therapeutic efficacy against experimental plantar tinea pedis and cutaneous candidiasis in guinea pigs. *Antimicrob Agents Chemother.* 2001;45:1493-1499.
31. Crean C, Aoyama A, Oh A, et al. Minimal systemic exposure of a topical triazole antifungal, efinaconazole 10% solution, in patients with severe onychomycosis following 28-day treatment. Poster presented at: 71st Annual Meeting of the American Academy of Dermatology; March 1-5, 2013; Miami, FL.
32. Jarratt M, Siu WJ, Yamakawa E, et al. Safety and pharmacokinetics of efinaconazole 10% solution in healthy volunteers and patients with severe onychomycosis: low systemic exposure suggests remote drug-drug interaction potential. *J Drugs Dermatol.* 2013;12:1010-1016.
33. Tatsumi Y, Nagashima M, Shibanushi T, et al. Mechanism of antifungal action of efinaconazole, a novel triazole agent [published online ahead of print March 4, 2013]. *Antimicrob Agents Chemother.* 2013;57:2405-2409.
34. Jo Siu WJ, Tatsumi Y, Senda H, et al. Comparison of in vitro antifungal activities of efinaconazole and currently available antifungal agents against a variety of pathogenic fungi associated with onychomycosis [published online ahead of print January 14, 2013]. *Antimicrob Agents Chemother.* 2013;57:1610-1616.
35. Jo W, Iwata A, Senda H, et al. Drug susceptibility and resistance of fungal isolates in onychomycosis against efinaconazole. Poster presented at: 71st Annual Meeting of the American Academy of Dermatology; March 1-5, 2013; Miami, FL.
36. Glynn M, Nejishima H, Sanada H, et al. Efinaconazole 10% solution: nonclinical safety supports topical use in onychomycosis. Poster presented at: 71st Annual Meeting of the American Academy of Dermatology; March 1-5, 2013; Miami, FL.
37. Jo W, Glynn M, Minowa K, et al. Efinaconazole: Developmental and Reproductive Toxicity Potential [abstract]. *Int J Toxicology.* 2013;32:58-88.
38. Joseph W, Vlahovic T, Pillai R, et al. Efinaconazole 10% solution in the treatment of onychomycosis of the toenail. *J Am Podiatr Assoc.* In press.