

# Case Letter

## In-Office Diagnosis of Cutaneous Mycosis: A Comparison of Potassium Hydroxide, Swartz-Lamkins, and Chlorazol Black E Fungal Stains

To the Editor:

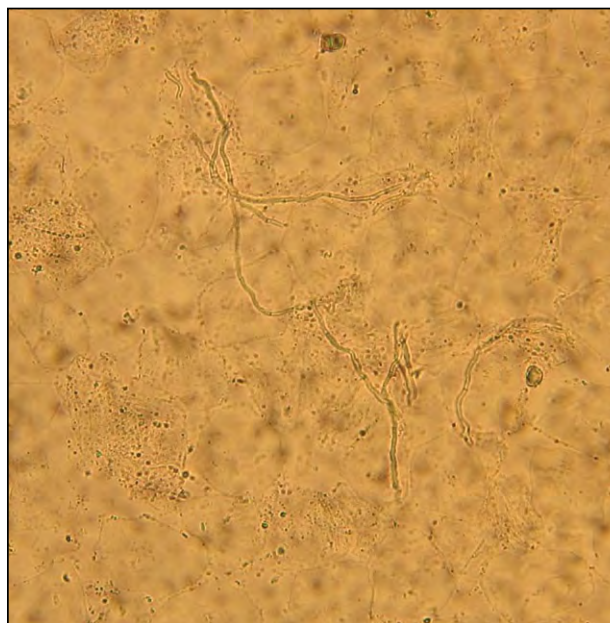
Cutaneous mycosis represents the most common type of skin infection<sup>1</sup> and accounts for up to 17% of dermatology office visits.<sup>2</sup> Wet-mount examination using direct microscopy is routinely used in the office to rapidly and cost-effectively detect fungal elements in dermatophytosis, pityriasis versicolor, and candidiasis. Three commonly used solutions for fungal preparation are potassium hydroxide (KOH), Swartz-Lamkins, and chlorazol black E. Although many experienced clinicians support a favorite stain, no analysis has been conducted to illustrate the differences between these stains. We present 3 photomicrographs of the fungal preparation from a patient with tinea corporis and highlight the characteristic features of each reagent.

In a patient with tinea corporis, a skin scraping was equally divided and used for 3 fungal preparations. Skin scrapings were taken from the active border of a tinea corporis lesion with a no. 15 scalpel blade, placed onto a microscope slide, and mounted with a coverslip. Two drops of plain KOH 20%, Swartz-Lamkins, or chlorazol black E solutions were applied to the respective slides and allowed to distribute by capillary action. The slides were gently heated and excess solution was blotted before examination under direct microscopy. In each case, multiple images were taken with different lighting, condenser position, and diaphragm settings to maximize the contrast and clarity of the photograph to best capture the experience at the microscope.

As a clearing agent, KOH rapidly lyses keratin to allow visualization of fungal elements. Although

using KOH (10%–20%) alone is the least expensive option, it has been shown that this technique lacks specificity and sensitivity,<sup>3-7</sup> especially when hyphae are sparse in the specimen. The inconsistency is most likely due to the lack of color contrast between fungal and surrounding elements (Figure 1). In our experience, KOH excels in cases with more florid hyphal forms.

The addition of counterstains to KOH, such as Parker blue ink or chlorazol black E, preferentially highlights hyphae and spores against the surrounding cellular component. The contrast further enhances fungal visualization and also aids in teaching and learning. The use of counterstain decreases the need



**Figure 1.** In a potassium hydroxide 20% wet mount, potassium hydroxide dissolves keratin and leaves fungal elements intact, revealing numerous septate branching hyphae among epithelial cells. There is a lack of contrast between fungi and cellular debris (original magnification  $\times 400$ ).

Dr. Shi is from the Department of Dermatology, University of California at Davis. Dr. Lio is from Northwestern University, Feinberg School of Medicine, Chicago.


The authors report no conflict of interest.

Correspondence: Peter A. Lio, MD, 1455 N Milwaukee Ave, 2nd Floor, Chicago, IL 60622 (p-lio@northwestern.edu).

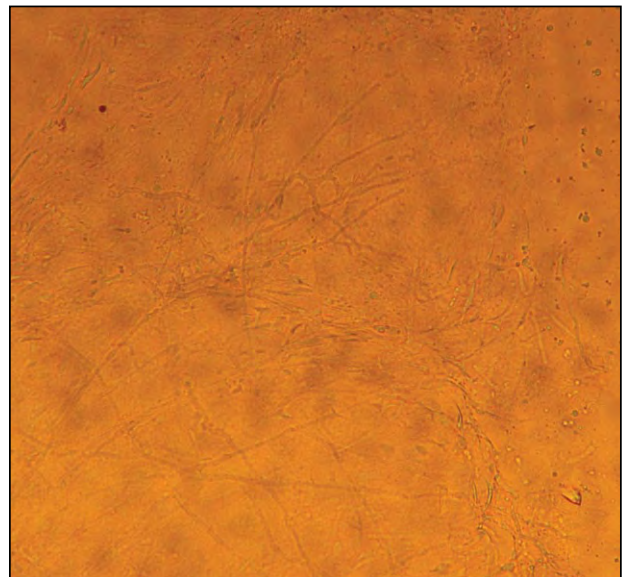
for high concentrations of KOH required for clearing, which may damage the microscope optical lens and may produce artifacts mistaken for fungi.<sup>8</sup> The use of Parker fountain pen ink for staining superficial fungi was first described by Cohen<sup>9</sup> in 1954, consisting of a 1:2 mixture of Parker 51 superchrome blue-black ink and dimethyl sulfoxide 20%.<sup>10</sup> Today, a commercially available formulation of Parker blue ink and KOH, also known as the Swartz-Lamkins fungal stain, contains KOH 2.5%, blue ink 0.5%, and surfactant.<sup>11</sup> The preparations typically will last until the fungal culture results are known. However, this stain is not entirely selective for fungi. Although fungal elements are stained dark blue, both cellular backgrounds and clothing fibers also may take up the stain, making it more challenging to pick out fungal components in thicker sections (Figure 2). In addition, a bluish precipitate is common in Parker-KOH stains.<sup>8</sup>

Chlorazol black E is an acid trisazo dye that was originally described by Cannon<sup>12</sup> in 1937. The stain is selective for chitin, the main component of fungal cell walls, which should diminish the amount of background artifact. Fungi are stained green, leaving cellular background a tan color (Figure 3), thus providing a clear distinction between fungal component and cellular debris; it is a good choice for an inexperienced observer. Additionally, it also can provide a clear distinction of the fungal nuclei and cytoplasmic structures.<sup>13</sup> Similar to plain KOH and Swartz-Lamkins, young hyphae are stained more rapidly than old hyphae. The commercially available chlorazol black E fungal stain is an alkaline solution containing chlorazol black E, dimethyl sulfoxide 10%, and KOH 5%.<sup>14</sup> Slides will retain staining for nearly 12 months when protected from light exposure. In our experience, this method had the most background staining and was more difficult to photograph. Chlorazol black E stains require a brighter light source from the microscope when scanning the slide,<sup>13</sup> which may be a limiting factor for some clinicians, particularly those with older microscopes.

Due to the lack of sensitivity, specificity, and consistency in plain KOH staining, for the inexperienced observer we recommend the use of either Swartz-Lamkins or chlorazol black E stain to facilitate the identification of fungal elements from cytoplasmic components of keratinocytes. Although these stains are useful in highlighting fungal elements, they do not differentiate between living and necrotic hyphal elements. Vital stains or viability assays are needed to distinguish live and necrotic hyphae in a specimen. An example of the former includes trypan blue, which selectively colors apoptotic cells with disrupted cell membrane; the tetrazolium salt reduction assay to measure fungal reductase and dehydrogenase activity



**Figure 2.** With the Swartz-Lamkins stain, hyphae appear blue against a light brown background of cellular debris and clothing fibers (original magnification  $\times 400$ ).



**Figure 3.** Chlorazol black E selectively stains chitin green, cytoplasm gray, and nuclei components black, while staining the background a tan color (original magnification  $\times 400$ ).

is an example of the latter. Nevertheless, both vital stains and viability assays require more advanced laboratory equipment and thus are beyond the scope of easy in-office diagnosis of superficial cutaneous mycosis. Although in-office fungal preparation for

direct microscopy does not provide definitive species identification or evidence of its pathogenicity,<sup>15</sup> it remains a quick and cost-effective test that allows for rapid diagnosis by an experienced operator.

Vivian Y. Shi, MD

Peter A. Lio, MD

## REFERENCES

1. dos Santos MM, Amaral S, Harmen SP, et al. The prevalence of common skin infections in four districts in Timor-Leste: a cross-sectional survey. *BMC Infect Dis*. 2010;10:61.
2. Ertam I, Babur Y, Unal I, et al. The frequency of skin diseases among students in a university clinic. *Skinmed*. 2010;8:261-263.
3. Côbo EC, Silva JC, Cota UA, et al. Evaluation of a modified microscopic direct diagnosis of dermatophytosis [published online ahead of print March 6, 2010]. *J Microbiol Methods*. 2010;81:205-207.
4. Tampieri MP. Update on the diagnosis of dermatomycosis [in Italian]. *Parassitologia*. 2004;46:183-186.
5. Hainer BL. Dermatophyte infections. *Am Fam Physician*. 2003;67:101-108.
6. Haldane DJ, Robart E. A comparison of calcofluor white, potassium hydroxide, and culture for the laboratory diagnosis of superficial fungal infection. *Diagn Microbiol Infect Dis*. 1990;13:337-339.
7. Weinberg JM, Koestenblatt EK, Tutrone WD, et al. Comparison of diagnostic methods in the evaluation of onychomycosis. *J Am Acad Dermatol*. 2003;49:193-197.
8. Swartz JH, Lamkins BE. A rapid, simple stain for fungi in skin, nail scrapings, and hairs. *Arch Dermatol*. 1964;89:89-94.
9. Cohen MM. A simple procedure for staining tinea versicolor (*M. furfur*) with fountain pen ink. *J Invest Dermatol*. 1954;22:9-10.
10. Cohen MM. An easy office procedure for staining superficial fungi with fountain pen ink. *Bull Sch Med Univ Md*. 1958;43:20-21.
11. Delasco Dermatologic Lab & Supply, Inc. Material safety data sheet: Swartz-Lamkins fungal stain. <http://www.delasco.com/pcat/pdf/swartz-l.pdf>. Published December 2010. Accessed November 13, 2013.
12. Cannon HG. A new biological stain for general purposes. *Nature*. 1937;139:549.
13. Burke WA, Jones BE. A simple stain for rapid office diagnosis of fungus infections of the skin. *Arch Dermatol*. 1984;120:1519-1520.
14. Delasco Dermatologic Lab & Supply, Inc. Material safety data sheet: chlorazol fungal stain. <http://www.delasco.com/pcat/pdf/chlorazo.pdf>. Published December 2010. Accessed November 13, 2013.
15. Piérard GE, Arrese JE, De Doncker P, et al. Present and potential diagnostic techniques in onychomycosis. *J Am Acad Dermatol*. 1996;34(2, pt 1):273-277.