

Case Letter

Perforating Folliculitis–Like Reaction Related to Sorafenib

To the Editor:

Sorafenib, an oral multitargeted kinase inhibitor affecting tumor cell angiogenesis and proliferation, is approved for the treatment of advanced renal cell carcinoma, unresectable hepatocellular carcinoma, and differentiated thyroid carcinoma. However, approximately 70% to 80% of patients may experience cutaneous side effects with sorafenib,^{1,4} including hand-foot skin reaction (HFSR), rash and/or desquamation, alopecia, pruritus, xerosis, facial erythema, and subungual splinter hemorrhage. An increasing number of reports have shed light on a potential alteration in the keratinocyte differentiation and/or proliferation pathways induced by sorafenib.² We report a case of a patient who developed a perforating folliculitis–like reaction while taking sorafenib.

A 55-year-old man with metastatic hepatocarcinoma presented with a chronic cutaneous eruption while taking sorafenib. Four months prior to presentation, pulmonary metastases prompted the initiation of sorafenib 200 mg twice daily. The dose was increased to 400 mg twice daily 15 days prior to consultation. Two weeks after sorafenib initiation, the patient began to develop HFSR with hyperesthesia, painful symmetric palmar and plantar erythema, and hyperkeratosis on the feet. Large, painful, erythematous papules developed on the legs and buttocks 6 weeks later. Examination revealed approximately 30 large, painful, erythematous papules with central follicular hyperkeratosis on the legs and buttocks (Figures 1 and 2). The eruption spared the face, the trunk, and the upper limbs. He also displayed painful palmar and

plantar erythema with a notable patchy keratoderma, with inflammatory borders restricted to pressure areas (Figure 3) and multiple painless splinter subungual hemorrhages. Cutaneous swabs were negative, ruling out infectious folliculitis. Histologic examination showed excess keratin in the follicular orifice with a horny plug dilatating the follicle's infundibulum. A discrete inflammatory infiltrate was noted in the perifollicular area. The epidermis demonstrated hyperkeratosis and follicular plugging (Figure 4). Because of its clinical efficacy on hepatocarcinoma, sorafenib was maintained at the same dosage. Topical corticosteroid ointments with salicylic acid provided relief for HFSR symptoms. Local antibiotherapy with erythromycin did not improve folliculitis. A combination of topical corticosteroid and tretinoin was applied. The patient refused oral isotretinoin.

The frequency of papular, pustular, cystic, and/or keratotic eruption while taking sorafenib remains unknown² but may be underreported. Hyperkeratotic folliculitis,^{2,5} keratosis pilaris,⁴ eruptive keratoacanthomas,^{6,7} and spiny follicular hyperkeratosis⁸ have been reported with sorafenib. Wolber et al⁹ reported a case of perforating folliculitis 5 months after initiation of sorafenib in a patient with renal cell carcinoma. Lesions improved with oral isotretinoin and cleared when sorafenib was withdrawn.⁹ Minami-Hori et al¹⁰ reported a similar case of perforating

Drs. Eberst, Pageaux, and Guillot are from and Dr. Kluger was from the Université Montpellier I, Hôpital Saint-Eloi, CHU de Montpellier, France. Drs. Eberst and Guillot are from and Dr. Kluger was from the Service de Dermatologie, and Dr. Pageaux is from the Service d'Hépatogastroentérologie et Transplantation Hépatique. Dr. Rigau is from the Université Montpellier I, Service d'anatomo-pathologie, Hôpital Gui-de-Chauliac, CHU de Montpellier, France. Dr. Kluger currently is from the Departments of Dermatology, Allergology, and Venereology, Skin and Allergy Hospital, The Hospital District of Helsinki and Uusima, Finland.

The authors report no conflict of interest.

Correspondence: Nicolas Kluger, MD, Skin and Allergy Hospital, HUS, PO Box 160, Helsinki, Finland 00029 (nicolaskluger@yahoo.fr).

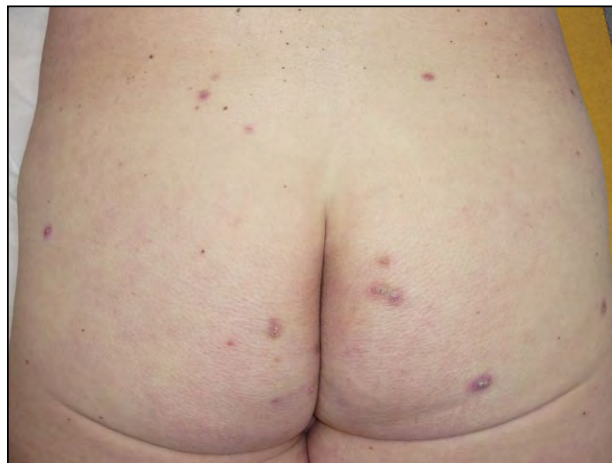

Figure 1. Inflammatory, hyperkeratotic, follicular papules on the buttocks.

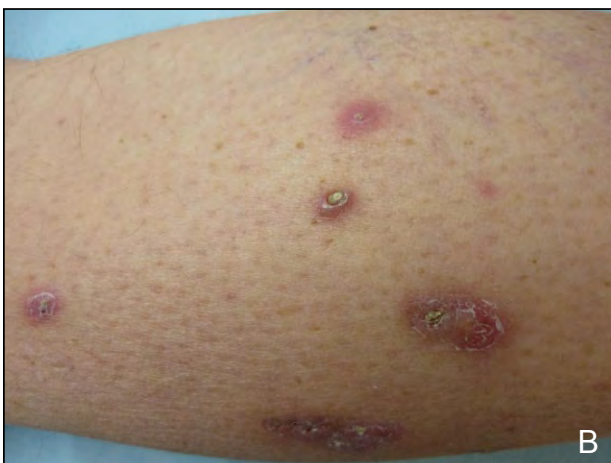
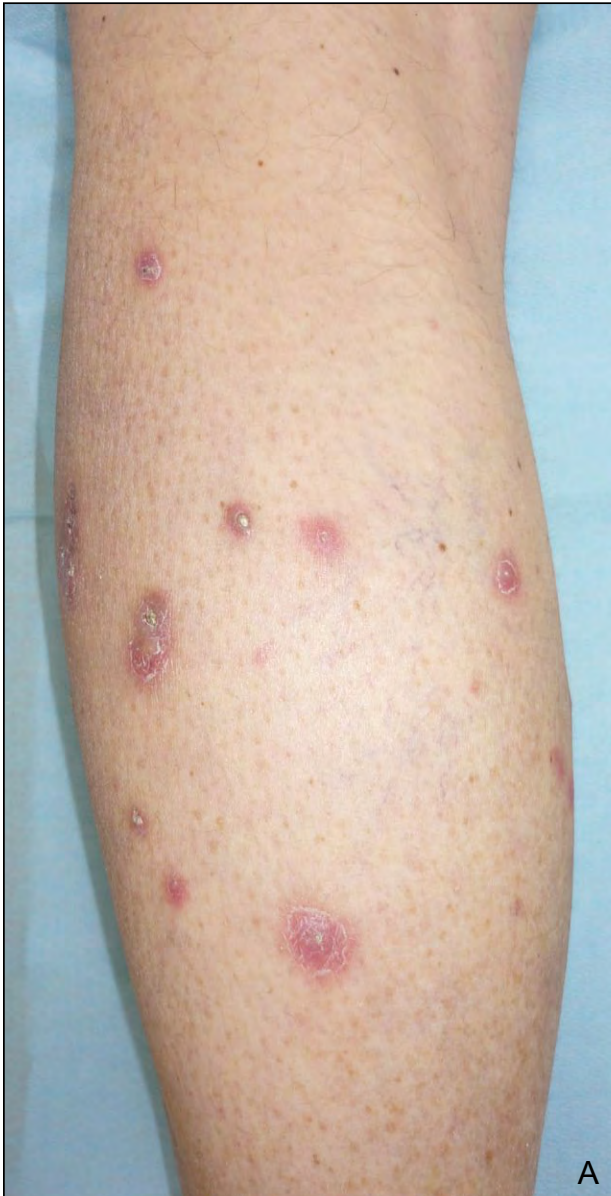
Figure 2. Inflammatory papules on the leg with a central keratotic plug (A and B).

folliculitis 7 weeks after beginning treatment; however, the authors observed spontaneous regression of the lesions. Cutaneous lesions in both cases were strikingly similar to ours, with multiple painful, mildly pruritic, papular lesions with extruding material.^{9,10} In our case, the histology was consistent with keratosis

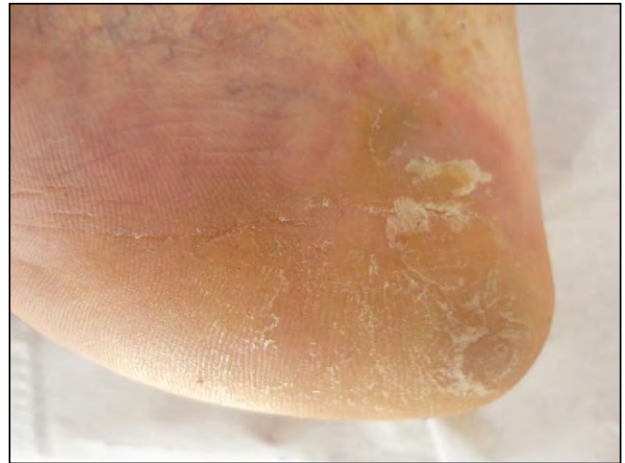

Figure 3. Plantar keratoderma restricted to the heel with inflammatory borders.

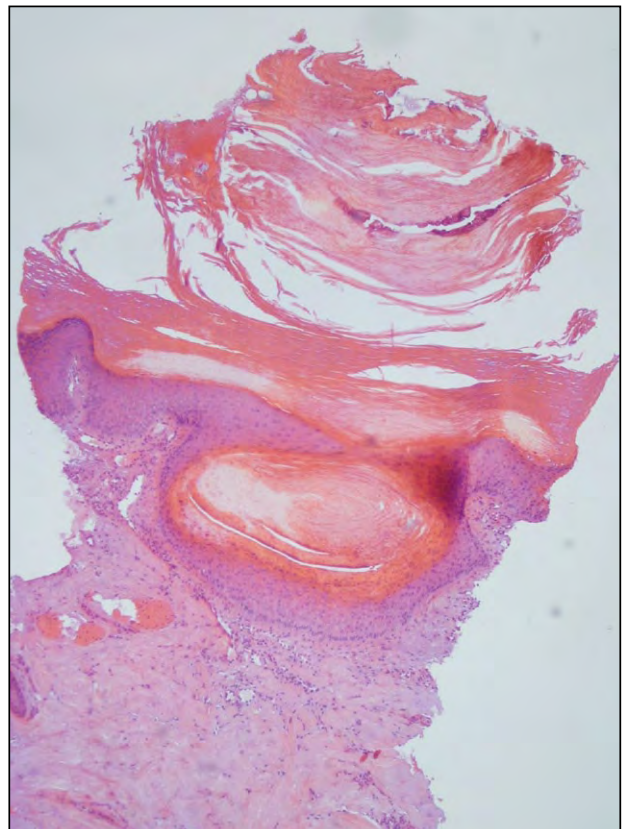


Figure 4. Dilatated follicular infundibulum filled by keratotic plugging (H&E, original magnification $\times 50$).

pilaris, as previously reported.⁴ However, the clinical presentation was more in favor of perforating folliculitis; therefore, we considered our patient to have a perforating folliculitis-like reaction. Hyperkeratotic folliculitis, perforating folliculitis, keratoacanthomas, keratosis pilaris, and spiny follicular hyperkeratosis may represent various aspects of the same spectrum of sorafenib-related cutaneous side effects. Sorafenib may affect keratinocyte differentiation and/or proliferation pathways.² Treatment relies first on topical therapies, including a combination of keratolytic and corticosteroid ointments. In case of inefficacy, isotretinoin (0.3 mg/kg daily) has shown some effects.⁹ However, sorafenib should be maintained as long as it is working on the metastatic disease and the patient can handle the cutaneous eruption.

Eleonore Eberst, MD
Valérie Rigau, MD
Georges-Philippe Pageaux, MD
Bernard Guillot, MD
Nicolas Kluger, MD

REFERENCES

1. Autier J, Escudier B, Wechsler J, et al. Prospective study of the cutaneous adverse effects of sorafenib, a novel multikinase inhibitor. *Arch Dermatol*. 2008;144:886-892.
2. Robert C, Mateus C, Spatz A, et al. Dermatologic symptoms associated with the multikinase inhibitor sorafenib [published online ahead of print November 25, 2008]. *J Am Acad Dermatol*. 2009;60:299-305.
3. Kong HH, Turner ML. Array of cutaneous adverse effects associated with sorafenib. *J Am Acad Dermatol*. 2009;61:360-361.
4. Lee WJ, Lee JL, Chang SE, et al. Cutaneous adverse effects in patients treated with the multitargeted kinase inhibitors sorafenib and sunitinib [published online ahead of print May 5, 2009]. *Br J Dermatol*. 2009;161:1045-1051.
5. Sahai S, Swick BL. Hyperkeratotic eruption, hand-foot skin reaction, facial erythema, and stomatitis secondary to multi-targeted kinase inhibitor sorafenib. *Int J Dermatol*. 2010;49:1203-1206.
6. Kong HH, Cowen EW, Azad NS, et al. Keratoacanthomas associated with sorafenib therapy. *J Am Acad Dermatol*. 2007;56:171-172.
7. Arnault JP, Wechsler J, Escudier B, et al. Keratoacanthomas and squamous cell carcinomas in patients receiving sorafenib [published online ahead of print July 13, 2009]. *J Clin Oncol*. 2009;27:e59-e61.
8. Franck N, Barete S, Moguelet P, et al. Spiny follicular hyperkeratosis eruption: a new cutaneous adverse effect of sorafenib [published online ahead of print September 20, 2010]. *J Clin Oncol*. 2010;28:e640-e642.
9. Wolber C, Udvardi A, Tatzreiter G, et al. Perforating folliculitis, angioedema, hand-foot syndrome—multiple cutaneous side effects in a patient treated with sorafenib [in English, German][published online ahead of print January 29, 2009]. *J Dtsch Dermatol Ges*. 2009;7:449-452.
10. Minami-Hori M, Ishida-Yamamoto A, Komatsu S, et al. Transient perforating folliculitis induced by sorafenib. *J Dermatol*. 2010;37:833-834.