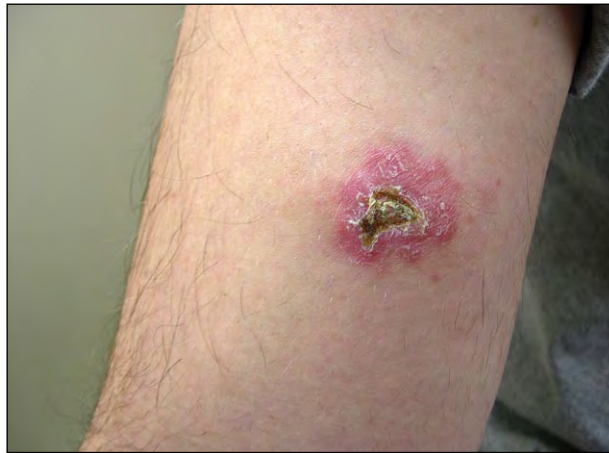

## What Is Your Diagnosis?



A 22-year-old man who was an army veteran presented with a persistent, tender, ulcerated plaque on the right bicep of 4 months' duration. The lesion originally developed 6 to 8 weeks after his return from a military tour of duty in Iraq and had progressed in size, most recently becoming spontaneously ulcerated. A 2-week course of oral cephalexin resulted in no improvement.

PLEASE TURN TO PAGE 69 FOR DISCUSSION

Ryan M. Hegg, MD; Theodore J. Alkousakis, MD; Brian L. Swick, MD

Dr. Hegg is from the Department of Radiology, Mayo Clinic, Rochester, Minnesota. Dr. Alkousakis is from the Department of Dermatology, University of Colorado, Aurora. Dr. Swick is from the Departments of Dermatology and Pathology, University of Iowa, Iowa City.

The authors report no conflict of interest.

Correspondence: Brian L. Swick, MD, Department of Dermatology, University of Iowa, 200 Hawkins Dr, 40025 PFP, Iowa City, IA 52245 (swickbrian@yahoo.com).

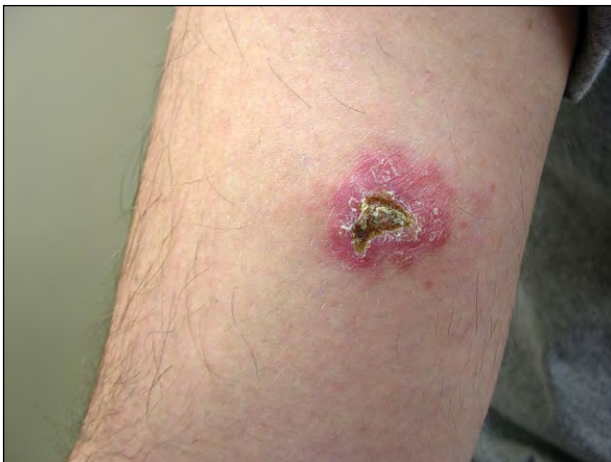## The Diagnosis: Old World Cutaneous Leishmaniasis

Physical examination revealed a 3-cm erythematous plaque on the right bicep with a central, depressed, shallow, 1-cm ulcer with no evidence of lymphadenopathy or hepatosplenomegaly (Figure 1). The patient was in good health and reported no fever, chills, weight loss, or other systemic symptoms. Additional history revealed that he had only spent time in Iraq during his tour of duty and had not visited Saudi Arabia, Kuwait, Afghanistan, or the Mediterranean Basin.

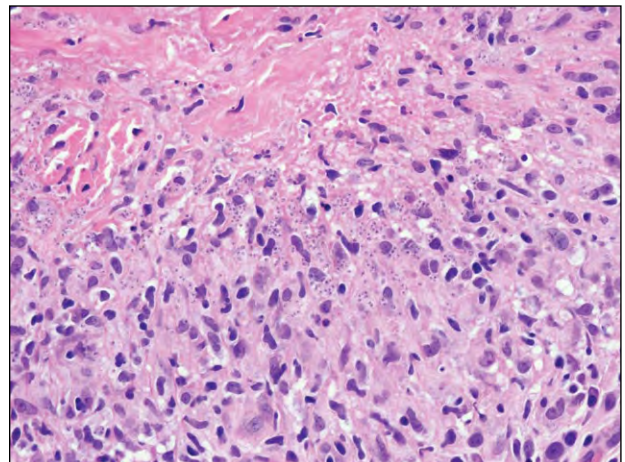
Histopathologic examination of a punch biopsy specimen revealed a superficial and deep perivascular and interstitial mixed infiltrate of lymphocytes, histiocytes, numerous plasma cells, and rare neutrophils,

as well as well-formed granulomas (Figure 2). High-power view demonstrated parasitized histiocytes that contained multiple 2- to 4- $\mu\text{m}$  round bodies (Figure 3) highlighted on Giemsa-stained sections (Figure 4). The round bodies exhibited a basophilic nucleus and a smaller rod-shaped kinetoplast. Given their morphology and staining properties, the intracellular organisms were consistent with amastigotes (Leishman-Donovan bodies). Tissue sent for sterile culture on Novy-MacNeal-Nicolle media at the Centers for Disease Control and Prevention in Atlanta, Georgia, grew *Leishmania major*.

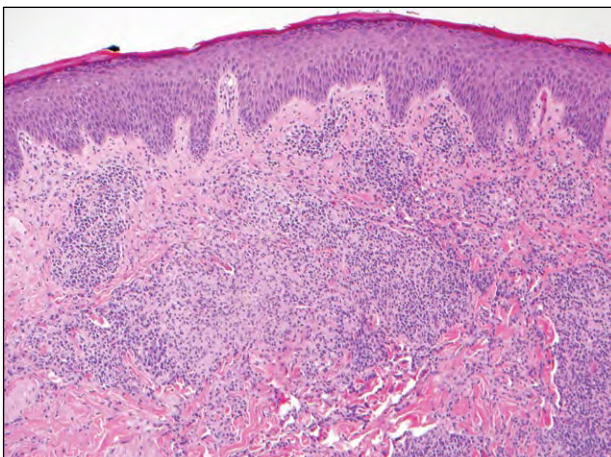
Due to discomfort associated with the ulcerated plaque, the patient was started on fluconazole



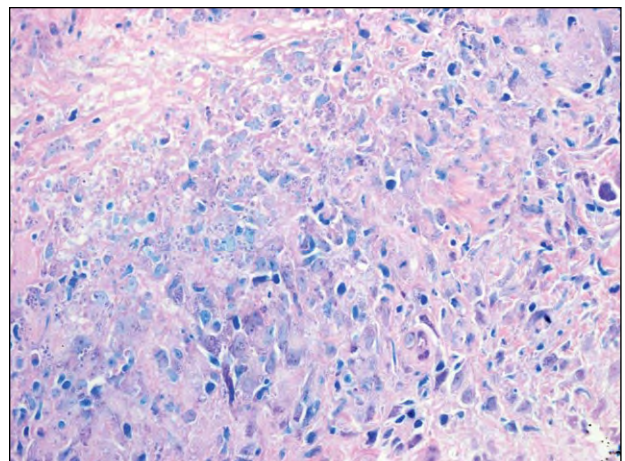
**Figure 1.** Ulcerated erythematous plaque on the right bicep.



**Figure 3.** Parasitized histiocytes containing Leishman-Donovan bodies (H&E, original magnification  $\times 60$ ).



**Figure 2.** Granulomatous and perivascular dermatitis with increased plasma cells (H&E, original magnification  $\times 10$ ).



**Figure 4.** Parasitized histiocytes containing purple Leishman-Donovan bodies (Giemsa, original magnification  $\times 60$ ).

200 mg daily as well as topical imiquimod applied daily to hasten resolution of the lesion; however, the plaque remained unchanged in size after 6 weeks of treatment. The patient then was treated with liquid nitrogen cryotherapy repeated at 3-week intervals, with complete resolution of the lesion following 2 treatments.

Leishmaniasis, a vector-borne obligate intracellular protozoan infection, is characterized by 3 clinical subtypes: cutaneous, mucocutaneous, and visceral. *Leishmania* species causing human disease include 21 members spread by phlebotomine sand fly species.<sup>1</sup> *Leishmania* promastigotes infect macrophages and transform into amastigotes that then replicate intracellularly in the dermis, nasopharyngeal mucosa, and reticuloendothelial system in cutaneous, mucocutaneous, and visceral leishmaniasis, respectively.<sup>1,2</sup> These 3 clinical subtypes can be further classified as Old World or New World leishmaniasis depending on geographic distribution.<sup>1</sup> Old World cutaneous leishmaniasis infections most commonly occur from *L major* and *Leishmania tropica* infection.

It has been reported that 1.5 to 2.0 million cases of leishmaniasis occur per year with increasing worldwide incidence, mostly in Middle Eastern countries.<sup>1,3</sup> During Operation Enduring Freedom and Operation Iraqi Freedom, many US troops and civilian workers in the Middle East were exposed to sand flies, which are abundant with few effective vector control measures available.<sup>2,4</sup> Approximately 1300 cases of leishmaniasis have been reported in US troops in Southwest Asia since 2001.<sup>5</sup> More than 90% of these cases have been cutaneous leishmaniasis due to *L major* in Iraq.<sup>6</sup> Incidences of cutaneous leishmaniasis in Afghanistan and Saudi Arabia also have included infection due to *L tropica*.<sup>7</sup> Most soldiers have presented with multiple cutaneous lesions, commonly on the arms and legs or other exposed skin.<sup>1,3,4</sup> The mean time to presentation for US troops with leishmaniasis is 9 weeks after initial discovery of cutaneous lesions, which often progress from erythematous papules or nodules to sharply demarcated plaques with eventual formation of ulcers that heal with scarring.<sup>1,3,4</sup>

Cutaneous leishmaniasis can be diagnosed both clinically and via demonstration of the parasite from a punch biopsy, scraping, or slit-skin smear from an active lesion. Cultures of aspirated material also may be used for diagnosis.<sup>1</sup> Giemsa-stained specimens with intracellular amastigotes within parasitized histiocytes (2–4  $\mu\text{m}$ , round-oval inclusions with nucleus and rod-shaped kinetoplast) are diagnostic for leishmaniasis. Speciation can be accomplished by sending a biopsy or aspirate specimen to the Centers for Disease Control and Prevention for culture on Novy-MacNeal-Nicolle media, polymerase chain reaction,

or isoenzyme analysis. Species identification is important for prognosis and determination of therapy.<sup>3</sup>

Although no consensus exists on the ideal treatment of cutaneous leishmaniasis, parenteral administration of pentavalent antimony compounds remains the gold standard<sup>1</sup>; however, the species and extent of the disease should determine whether to follow this treatment, to use another method such as second-line agents (eg, azole antibiotics) or local treatment modalities (eg, cryotherapy), or to administer no treatment.<sup>1,4,7,8</sup> *Leishmania major* infection generally resolves spontaneously over 2 to 12 months with no risk for recurrent or viscerotropic disease.<sup>1</sup> However, systemic treatment should be considered for lesions involving cosmetically sensitive areas (eg, the face), areas with functional concerns (eg, overlying joints, genitalia), locally disseminated disease, or immunocompromised patients.<sup>1,4,8</sup> Because *L tropica* infection has been associated with leishmaniasis recidivans, viscerotropic disease, and cutaneous lesions that may take longer than a year to resolve, systemic therapy also should be considered for these patients.<sup>4</sup>

Clinicians should not overlook leishmaniasis infection when treating nonhealing, desquamating, or nodular ulcers that are nonresponsive to antibiotics in patients who have served military tours of duty in endemic areas.

## REFERENCES

1. Herwaldt BL. Leishmaniasis. *Lancet*. 1999;354:1191-1199.
2. Reithinger R, Dujardin JC, Louzir H, et al. Cutaneous leishmaniasis. *Lancet Infect Dis*. 2007;7:581-596.
3. Grevelink SA, Lerner EA. Leishmaniasis. *J Am Acad Dermatol*. 1996;34(2, pt 1):257-272.
4. Weina PJ, Neafie RC, Wortmann G, et al. Old world leishmaniasis: an emerging infection among deployed US military and civilian workers [published online ahead of print November 9, 2004]. *Clin Infect Dis*. 2004;39:1674-1680.
5. Claborn D, Masuoka P, Morrow M, et al. Habitat analysis of North American sand flies near veterans returning from leishmania-endemic war zones. *Int J Health Geogr*. 2008;7:65.
6. Aronson NE. Leishmaniasis in relation to service in Iraq/Afghanistan, US Armed Forces, 2001-2006. *MSMR*. 2007;14:2-5.
7. Aronson NE, Sanders JW, Moran KA. In harm's way: infections in deployed American military forces [published correction in *Clin Infect Dis*. 2006;43:1498][published online ahead of print September 14, 2006]. *Clin Infect Dis*. 2006;43:1045-1051.
8. Willard RJ, Jeffcoat AM, Benson PM, et al. Cutaneous leishmaniasis in soldiers from Fort Campbell, Kentucky, returning from Operation Iraqi Freedom highlights diagnostic and therapeutic options. *J Am Acad Dermatol*. 2005;52:977-987.