

Series Editor: Camila K. Janniger, MD

Ulerythema Ophryogenes: Updates and Insights

Christopher M. Morton, MD; Chinmoy Bhate, MD; Camila K. Janniger, MD; Robert A. Schwartz, MD, MPH

Practice Points

- Ulerythema ophryogenes is an uncommon benign atrophic disorder of the skin that may occur in children and young adults in association with various congenital syndromes.
- It is important to reassure patients and their guardians that skin findings are likely to resolve with age.

Ulerythema ophryogenes is a rare cutaneous atrophic disorder that occasionally is associated with Noonan syndrome, de Lange syndrome, Rubinstein-Taybi syndrome, and cardiofaciocutaneous (CFC) syndrome. Often presenting in pediatric patients, the pathogenesis of ulerythema ophryogenes remains unclear, though several genetic causes have been suggested. Treatment recommendations remain anecdotal, but clearance has been noted as the patient ages. Although topical agents have been the mainstay of therapy, recent advancement in laser intervention for treatment of ulerythema ophryogenes is promising.

Cutis. 2014;93:83-87.

Ulerythema ophryogenes is a rare cutaneous disorder characterized by inflammatory keratotic papules on the face that may result in scars, atrophy, and alopecia.¹ Originally described by Tanzer² in 1889, the term *ulerythema ophryogenes* was first used by Unna³ in 1896 and has been reported in association with other rare congenital illnesses such as Noonan syndrome, de Lange syndrome, and

Rubinstein-Taybi syndrome (Table 1).⁴⁻⁶ Ulerythema ophryogenes falls within the broader category of keratosis pilaris atrophicans⁷ (Table 2).

Ulerythema ophryogenes also has been associated with cardiofaciocutaneous (CFC) syndrome, another rare disease that is classified as one of the RASopathies, a group of syndromes with overlapping clinical features that are defined by a defect in the Ras pathway.⁸ Cardiofaciocutaneous syndrome includes cardiac abnormalities (eg, atrial septal defects, ventricular septal defects, hypertrophic cardiomyopathy), valve abnormalities (eg, mitral valve dysplasia, tricuspid valve dysplasia, bicuspid aortic valve), dysmorphic facial features (eg, high forehead, downslanting palpebral fissures, short nose, hypoplasia of supraorbital ridges), and cutaneous abnormalities (eg, hyperkeratosis, ichthyosis, ulerythema ophryogenes).⁹

To our knowledge, accurate statistics regarding the prevalence of ulerythema ophryogenes are not available, and no racial, ethnic, or gender predilections have been noted. Children and young adults are most commonly affected. In most case studies, children have been aged 5 to 16 years on initial presentation. They have largely been fair-skinned males with blond hair.¹⁰

Pathogenesis

The pathogenesis of ulerythema ophryogenes usually is sporadic, though inherited cases presenting in an autosomal-dominant pattern have been reported.⁴

From the Departments of Dermatology and Pediatrics, Rutgers New Jersey Medical School, Newark.

The authors report no conflicts of interest.

Correspondence: Robert A. Schwartz, MD, MPH, Department of Dermatology, Rutgers New Jersey Medical School, Medical Science Building, H-576, Newark, NJ 07103 (roschwar@cal.berkeley.edu).

Table 1.

Syndromes Associated With Ulerythema Ophryogenes

Syndrome	Characteristics
Noonan syndrome	Developmental delays; congenital cardiac abnormalities; dysmorphic facial features including wide-spaced eyes and low-set ears; renal abnormalities; bleeding diathesis
de Lange syndrome	Dysmorphic facial features including synophrys, small head circumference, and low-set ears; psychomotor and mental retardation; gastrointestinal tract complications; visceral system involvement; behavioral difficulties
Rubinstein-Taybi syndrome	Genetic disorder; short stature; learning disabilities; broad thumbs and first toes
Cardiofaciocutaneous syndrome	Cardiac abnormalities; valve abnormalities; dysmorphic facial features including high forehead, downslanting palpebral fissures, short nose, and hypoplasia of the supraorbital ridges; other cutaneous abnormalities

Genetic factors are important, as there may be an association between partial monosomy of the chromosome arm 18p and the presentation of both keratosis pilaris and ulerythema ophryogenes.¹¹ It has been speculated that the genes responsible for follicular keratinization could be located on chromosome arm 18p. A study demonstrated that 80% (49/61) and 90% (55/61) of patients with CFC syndrome exhibited keratosis

Table 2.

Subtypes of Keratosis Pilaris

Subtype	Characteristics
Keratosis pilaris alba	Grayish white papules of keratosis pilaris without surrounding erythema
Keratosis pilaris rubra	Marked erythema surrounding an area of keratosis pilaris
Keratosis pilaris rubra faciei	Located on the face
Keratosis pilaris atrophicans	A set of related disorders described by keratosis pilaris followed by atrophy
Keratosis pilaris atrophicans faciei	Also referred to as ulerythema ophryogenes; keratosis pilaris atrophicans located on the face, notably the cheeks

Data from Chisholm et al.¹⁰

pilaris and ulerythema ophryogenes, respectively.¹² In a few families, this disorder has been inherited in an autosomal-dominant pattern.⁴

A molecular defect has not been elucidated in the pathogenesis of ulerythema ophryogenes, but clues are emerging, with the disorder appearing as a trait in different syndromes. A partial monosomy or deletion in chromosome arm 18p may contribute to the development of this disease.¹³⁻¹⁶ One potential molecular defect in ulerythema ophryogenes associated with Noonan syndrome or de Lange syndrome is the deletion of chromosome arm 18p caused by t(Y;18).^{14,16} The α_1 -laminin gene, *LAMA1*, may be involved.¹⁵ Its deletion may result in the disruption of the formation of laminin. The *LAMA1* gene is located on the chromosome arm 18p.¹⁷ Laminin, a major component of the basement membrane, is thought to be involved in processes of cell differentiation, adhesion, and migration.¹⁸ Its role in ulerythema ophryogenes has not been previously

investigated. Others propose a deletion of chromosome arm 12q as the cause of the condition.¹³

A viral etiology also has been proposed. One idiopathic case of ulerythema ophryogenes revealed human papillomavirus in a biopsy of a suspected papule. Standard karyotype and comparative genomic hybridization analysis did not reveal any genetic abnormalities.¹⁹

A competent Ras pathway also may be required for the development of ulerythema ophryogenes. The Ras proteins are involved in regulating the MAPK pathway, a critical component of cell differentiation and growth.²⁰ A study by Siegel et al²¹ compared the dermatologic features of Costello syndrome and CFC syndrome, as Costello syndrome shares many features with cutaneous paraneoplastic syndromes. Because both syndromes involve different genes associated with the MAPK pathway, they provide a basis for the comparison of gene mutations with relation to clinical features. Costello syndrome is marked by features of cardiomyopathy, coarse facial features, postnatal growth deficiency, acanthosis nigricans, and papillomata.²² Patients with Costello syndrome are less likely to develop ulerythema ophryogenes than those with CFC syndrome.²¹ All participants in the Siegel et al²¹ study had Costello syndrome confirmed by a mutation in the *H-ras* (Harvey rat sarcoma) gene. Cardiofaciocutaneous syndrome is associated with *BRAF* mutations approximately 75% of the time,²³ though it also may result from other mutations in genes involved with the MAPK pathway, such as *K-ras* (Kirsten rat sarcoma), *MEK1*, and *MEK2* (mitogen-activated extracellular signal-regulated kinase).^{24,25} Dysregulation of the Ras pathway through a mutated *H-ras* gene may be the cause of the decreased incidence of ulerythema ophryogenes in patients with Costello syndrome. Thus, it may be possible that although CFC syndrome is considered a RASopathy, its lack of an associated *H-ras* mutation denotes some form of competence in the Ras pathway such that the development of ulerythema ophryogenes is possible.

Diagnosis

The diagnosis of ulerythema ophryogenes is largely clinical. Histology often is nonspecific. Ulerythema ophryogenes can be divided into 2 histologic stages: (1) an early stage characterized by follicular hyperkeratosis, and (2) a later stage that may show the presence of fibrosis and atrophy.¹⁰ In the early stage, pilosebaceous follicles filled with keratotic plugs and a mild perifollicular inflammatory infiltrate are observed. Cystic dilatation of the hair follicles may be evident in specimens obtained from the cheeks. Later, atrophy or loss of hair follicles and sebaceous glands

as well as dermal fibrosis may appear. Perifollicular fibrosis may progress and become more extensive. There may be subsequent effacement of the epidermal rete ridges and an increase in dermal elastic tissue.¹⁰

Clinical Presentation

Children with ulerythema ophryogenes usually present with erythema and tiny follicular keratotic papules on the lateral parts of the eyebrows. Similar findings may develop on the lateral aspects of the forehead and cheeks. Later, atrophy and loss of eyebrows is seen. Discrete follicular papules may appear on the scalp as well as on the extensor surfaces of the arms and thighs. The affected areas may feel rough on gentle palpation. Generalized facial erythema with scattered open and closed comedones as well as milia may be present. Rarely, similar lesions may be seen on the extensor surfaces of the arms and legs. Additionally, hyperkeratotic follicular plugs with surrounding erythema can be seen on the cheeks, which evolve into coalescent follicular depressions in a honeycomb or worm-eaten pattern known as atrophoderma vermiculatum (Figures 1 and 2). The condition typically improves as the patient ages, but loss of lateral eyebrows and resultant scarring may be permanent.¹ This benign disorder has no known malignant potential.

Treatment

Spontaneous resolution with age is common; however, sun protection is pivotal, as ulerythema ophryogenes typically presents on sun-exposed skin in children, with UV radiation often exacerbating the condition.

A conservative approach similar to treatment of keratosis pilaris is most commonly utilized. Patients and their guardians should be instructed to use a mild soapless cleanser 1 to 2 times daily to prevent excessive skin dryness.²⁶ Mild keratolytics, such as

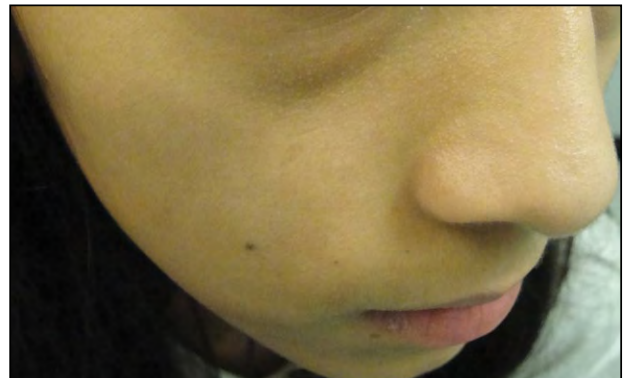

Figure 1. Scattered atrophic wormlike macules on the maxillary cheeks in a 13-year-old adolescent girl.

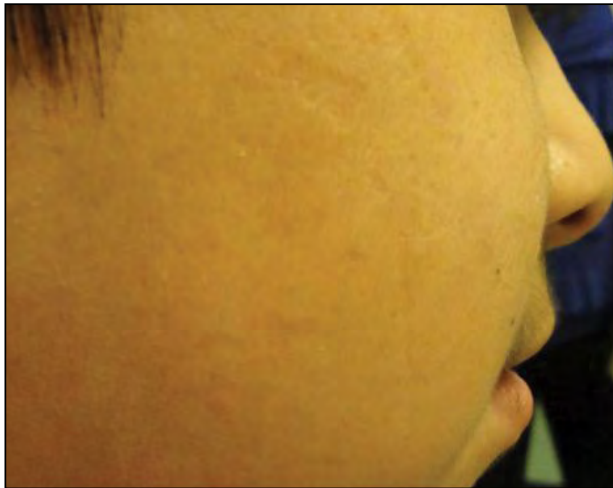


Figure 2. Pityriasis alba and wormlike depressed scars on the lateral zygomatic and buccal skin in an 8-year-old boy.

topical formulations of lactic acid 5%, urea 5%, or salicylic acid 2%–5%, can be applied twice daily and may be interchanged with low-potency topical corticosteroids. Low-potency steroids, such as triamcinolone acetonide 0.1%, can be used if the area is acutely inflamed for a 7- or 10-day course and may be applied twice daily.²⁶ A pilot study showed that application of tacrolimus ointment 0.1% or white petrolatum jelly may improve keratosis pilaris. Participants applied tacrolimus ointment 0.1% or white petrolatum twice daily for 4 weeks with an amount that was sufficient to cover the affected area.²⁷ This same practice may be applied to ulerythema ophryogenes; patients may apply an amount sufficient to cover the keratotic papules and plugs as well as any associated erythema. Topical retinoids are useful adjuncts in patients with comedones,²⁸ but the risk-benefit correlation does not support the use of systemic retinoids for the treatment of ulerythema ophryogenes.¹

Surgical treatment of ulerythema ophryogenes remains limited. In recent years, the efficacy of laser therapy has been documented. Keratosis pilaris rubra and keratosis pilaris atrophicans faciei may be treated with good results using the pulsed dye laser (PDL) at either a 585- or 595-nm wavelength.²⁹⁻³¹ Successful treatment with a CO₂ laser and 585-nm PDL was reported in 2 patients.³¹ One study of 10 patients examined the use of PDL at a 595-nm wavelength. In this study, more than 75% of erythema was cleared, with complete resolution of erythema in 3 patients.²⁹ A study of 12 cases of keratosis pilaris atrophicans treated with PDL at 585 nm

showed a significant reduction in erythema ($P < .05$); the majority of patients also exhibited a decrease in the rough texture of their skin.³⁰

Intense pulsed light also is an exciting treatment modality that warrants further study. In one study, 570-nm intense pulsed light was used in 4 patients with keratosis pilaris atrophicans. Erythema clearance of 75% to 100% was noted in each patient with no recurrence at 10-month follow-up.³² Laser therapy combined with microdermabrasion has been effective in the treatment of keratosis pilaris,³³ but its role in ulerythema ophryogenes has not been investigated. Hair transplant surgery may be considered for areas of hair loss, especially the eyebrows, and for aesthetic improvement by mitigating the appearance of scars.³⁴

Conclusion

Ulerythema ophryogenes is a rare, benign, cutaneous atrophic disorder that is commonly seen in children. Early identification may be crucial in the management of cases associated with other congenital systemic syndromes. The role of laser treatment and intense pulsed light requires further investigation. Therapy typically includes sun protection in conjunction with keratolytics, topical corticosteroids, and topical retinoids. It is critical to reassure patients and guardians that resolution with age is common in isolated cases.

REFERENCES

- Janniger CK. Ulerythema. <http://emedicine.medscape.com/article/1118415-overview>. Updated October 1, 2013. Accessed October 21, 2013.
- Tanzer P. Über das ulerythema ophryogenes, eine noch nicht beschriebene hautkrankheit. In: *Montatshefte für Praktische Dermatologie*. Hamburg, Germany: Verlag von Leopold Voss; 1889:197-208.
- Unna PG. *The Histopathology of the Diseases of the Skin*. New York, NY: Macmillan & Co; 1896.
- Burnett JW, Schwartz MF, Berberian BJ. Ulerythema ophryogenes with multiple congenital anomalies. *J Am Acad Dermatol*. 1988;18(2, pt 2):437-440.
- Gómez Centeno P, Rosón E, Peteiro C, et al. Rubinstein-Taybi syndrome and ulerythema ophryogenes in a 9-year-old boy. *Pediatr Dermatol*. 1999;16:134-136.
- Snell JA, Mallory SB. Ulerythema ophryogenes in Noonan syndrome. *Pediatr Dermatol*. 1990;7:77-78.
- Luria RB, Conologue T. Atrophoderma vermiculatum: a case report and review of the literature on keratosis pilaris atrophicans. *Cutis*. 2009;83:83-86.
- Tidyman WE, Rauen KA. The RASopathies: developmental syndromes of RAS/MAPK pathway dysregulation [published online ahead of print May 19, 2009]. *Curr Opin Genet Dev*. 2009;19:230-236.

9. Rauen KA. Cardiofaciocutaneous syndrome. *GeneReviews*. Seattle, WA: University of Washington; 1993. <http://www.ncbi.nlm.nih.gov/books/NBK11116/>. Published January 18, 2007. Updated September 6, 2012.
10. Chisholm C, Miedler J, Etufugh CN, et al. Unusual and recently described cutaneous atrophic disorders. *Int J Dermatol*. 2011;50:1506-1517.
11. Carvalho CA, Carvalho AV, Kiss A, et al. Keratosis pilaris and ulerythema ophryogenes in a woman with monosomy of the short arm of chromosome 18 [in English, Portuguese]. *An Bras Dermatol*. 2011;86:S42-S45.
12. Siegel DH, McKenzie J, Frieden IJ, et al. Dermatological findings in 61 mutation-positive individuals with cardiofaciocutaneous syndrome [published online ahead of print January 28, 2011]. *Br J Dermatol*. 2011;164:521-529.
13. Klein OD, Cotter PD, Schmidt AM, et al. Interstitial deletion of chromosome 12q: genotype-phenotype correlation of two patients utilizing array comparative genomic hybridization. *Am J Med Genet A*. 2005;138:349-354.
14. Nazarenko SA, Ostroverkhova NV, Vasiljeva EO, et al. Keratosis pilaris and ulerythema ophryogenes associated with an 18p deletion caused by a Y/18 translocation. *Am J Med Genet*. 1999;85:179-182.
15. Zouboulis CC, Stratakis CA, Gollnick HP, et al. Keratosis pilaris/ulerythema ophryogenes and 18p deletion: is it possible that the *LAMA1* gene is involved? *J Med Genet*. 2001;38:127-128.
16. Zouboulis CC, Stratakis CA, Rinck G, et al. Ulerythema ophryogenes and keratosis pilaris in a child with monosomy 18p. *Pediatr Dermatol*. 1994;11:172-175.
17. Nagayoshi T, Mattei MG, Passage E, et al. Human laminin A chain (*LAMA*) gene: chromosomal mapping to locus 18p11.3. *Genomics*. 1989;5:932-935.
18. Sasaki S, Ota M, Meguro A, et al. A single nucleotide polymorphism analysis of the *LAMA1* gene in Japanese patients with high myopia. *Clin Ophthalmol*. 2007;1:289-295.
19. Dianzani C, Pizzuti A, Gaspardini F, et al. Ulerythema ophryogenes, a rare and often misdiagnosed syndrome: analysis of an idiopathic case. *Int J Immunopathol Pharmacol*. 2011;24:523-527.
20. Hahn WC, Counter CM, Lundberg AS, et al. Creation of human tumour cells with defined genetic elements. *Nature*. 1999;400:464-468.
21. Siegel DH, Mann JA, Krol AL, et al. Dermatological phenotype in Costello syndrome: consequences of Ras dysregulation in development. *Br J Dermatol*. 2012;166:601-607.
22. Philip N, Sigaudy S. Costello syndrome. *J Med Genet*. 1998;35:238-240.
23. Rodriguez-Viciana P, Rauen KA. Biochemical characterization of novel germline *BRAF* and *MEK* mutations in cardio-facio-cutaneous syndrome. *Methods Enzymol*. 2008;438:277-289.
24. Narumi Y, Aoki Y, Niihori T, et al. Molecular and clinical characterization of cardio-facio-cutaneous (CFC) syndrome: overlapping clinical manifestations with Costello syndrome. *Am J Med Genet A*. 2007;143A:799-807.
25. Gripp KW, Lin AE, Nicholson L, et al. Further delineation of the phenotype resulting from *BRAF* or *MEK1* germline mutations helps differentiate cardio-facio-cutaneous syndrome from Costello syndrome. *Am J Med Genet A*. 2007;143A:1472-1480.
26. Hwang S, Schwartz RA. Keratosis pilaris: a common follicular hyperkeratosis. *Cutis*. 2008;82:177-180.
27. Breithaupt AD, Alio A, Friedlander SF. A comparative trial comparing the efficacy of tacrolimus 0.1% ointment with Aquaphor ointment for the treatment of keratosis pilaris. *Pediatr Dermatol*. 2011;28:459-460.
28. Layton AM, Cunliffe WJ. A case of ulerythema ophryogenes responding to isotretinoin. *Br J Dermatol*. 1993;129:645-646.
29. Alcántara González J, Boixeda P, Truchuelo Diez MT, et al. Keratosis pilaris rubra and keratosis pilaris atrophicans faciei treated with pulsed dye laser: report of 10 cases [published online ahead of print June 21, 2010]. *J Eur Acad Dermatol Venereol*. 2011;25:710-714.
30. Clark SM, Mills CM, Lanigan SW. Treatment of keratosis pilaris atrophicans with the pulsed tunable dye laser. *J Cutan Laser Ther*. 2000;2:151-156.
31. Handrick C, Alster TS. Laser treatment of atrophoderma vermiculata. *J Am Acad Dermatol*. 2001;44:693-695.
32. Rodriguez-Lojo R, Pozo JD, Barja JM, et al. Keratosis pilaris atrophicans: treatment with intense pulsed light in four patients. *J Cosmet Laser Ther*. 2010;12:188-190.
33. Lee SJ, Chung WS, Kim J, et al. Combination of 595-nm pulsed dye laser, long-pulsed 755-nm alexandrite laser and microdermabrasion treatment for keratosis pilaris [published online ahead of print October 5, 2011]. *J Dermatol*. 2012;39:479-480.
34. Miranda BH, Farjo N, Farjo B. Eyebrow reconstruction in dormant keratosis pilaris atrophicans [published online ahead of print July 2, 2011]. *J Plast Reconstr Aesthet Surg*. 2011;64:e303-e305.