

Microcystic Adnexal Carcinoma: Review of a Potential Diagnostic Pitfall and Management

Lana H. McKinley, DO; Stacey Seastrom, DO; Andrew J. Hanly, MD; Richard A. Miller, DO

Practice Points

- Microcystic adnexal carcinoma (MAC) is a rare, locally aggressive, malignant cutaneous neoplasm with pilar and eccrine gland differentiation.
- Microcystic adnexal carcinoma should be considered in the differential diagnosis for slow-growing tumors of the head and neck.
- Initial misdiagnosis of MAC is possible, as the superficial histologic findings often mimic benign follicular neoplasms.
- Mohs micrographic surgery is the treatment of choice for MAC.

Microcystic adnexal carcinoma (MAC) is an uncommon, locally aggressive cutaneous neoplasm that usually presents as a slow-growing, asymptomatic lesion on the head or neck. Microcystic adnexal carcinoma frequently is misdiagnosed due to its histologic appearance on superficial biopsy specimens mimicking other follicular neoplasms. Herein, we highlight a case in which a slow-growing lesion was initially diagnosed as a tricho-adenoma following superficial biopsy; however, after surgical excision the pathology revealed a locally aggressive MAC.

Cutis. 2014;93:162-165.

Microcystic adnexal carcinoma (MAC) is an uncommon, locally aggressive cutaneous neoplasm that was first identified as a distinct clinical entity by Goldstein et al¹ in 1982. The investigators concluded that this tumor is synonymous with malignant syringoma and sweat gland

carcinoma with syringomatous features.¹ Clinically, it presents as a slow-growing, asymptomatic lesion on the head or neck. Microcystic adnexal carcinoma has a predilection for white individuals and has a slight female predominance.² It frequently is misdiagnosed due to its histologic appearance on superficial biopsy specimens mimicking other follicular neoplasms.

Case Report

A 90-year-old white woman presented with a lesion on the left side of the upper lip of 1 year's duration. She denied pain, bleeding, pruritus, or history of a similar growth. Her medical history was remarkable for several nonmelanoma skin cancers. She denied history of visceral malignancy or facial radiation. Surgical history was positive for several cutaneous excisions. Her medications included daily aspirin. Family history was noncontributory. Review of systems was negative for facial pain, anesthesia, paresthesia, fasciculation, or constitutional symptoms.

Physical examination revealed a 1.2-cm, pink, well-circumscribed, nonindurated papule on the left side of the upper lip. A shave biopsy of the lesion revealed epithelial islands with central keratinous material surrounded by basaloid cells and a collagenous stroma (Figure 1). Based on these histologic features, the lesion was diagnosed as a benign tricho-adenoma with involved margins. Complete removal

Drs. McKinley, Seastrom, and Miller are from Nova Southeastern College of Osteopathic Medicine, Largo Medical Center, Florida. Dr. Hanly is from Global Pathology, Miami Lakes, Florida. The authors report no conflict of interest. Correspondence: Lana H. McKinley, DO, Largo Medical Center, Medical Education, 2025 Indian Rocks Rd, Largo, FL 33774 (lana.mckinley@gmail.com).

of the lesion to prevent local recurrence was recommended, and a full excision biopsy of the clinical margin was performed.

The excision specimen revealed deeply infiltrative, syringoid ducts consistent with an aggressive MAC (Figure 2). Perineural invasion was evident (Figure 3A) as well as skeletal muscle involvement extending to peripheral and deep margins (Figure 3B). Mohs micrographic surgery (MMS) was recommended, but because of the patient's advanced age, she and her family declined the procedure and elected for wide local excision, which resulted in successful removal of involved margins.

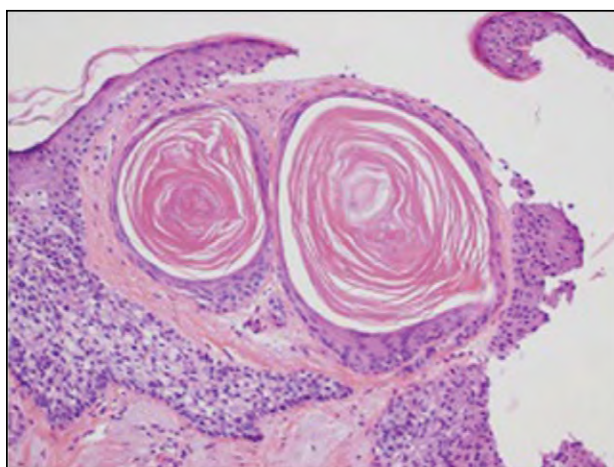


Figure 1. Shave biopsy of the lesion revealed epithelial islands with central keratinous material surrounded by basaloid cells and a collagenous stroma (H&E, original magnification $\times 10$).

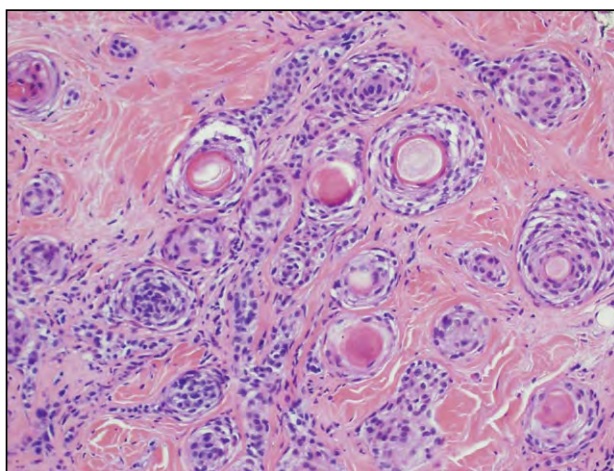


Figure 2. Excision specimen revealed deeply infiltrative, syringoid ducts consistent with an aggressive microcystic adnexal carcinoma (H&E, original magnification $\times 20$).

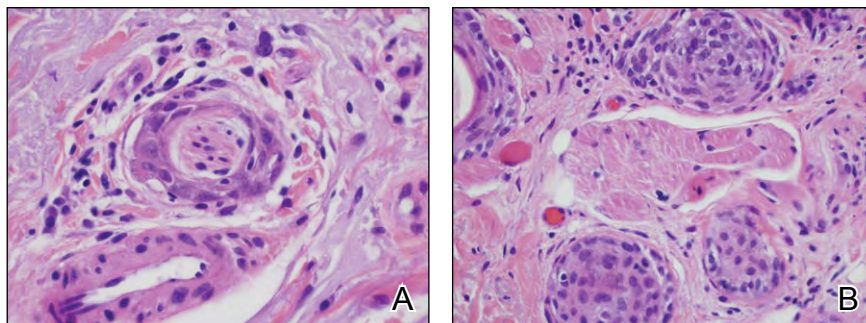
Comment

Microcystic adnexal carcinomas are rare, locally aggressive, malignant cutaneous neoplasms with pilar and eccrine gland differentiation that rarely metastasize. Fewer than 300 cases have been reported worldwide, according to an analysis by Yu et al² using the National Cancer Institute's Surveillance, Epidemiology, and End Results (SEER) database. Microcystic adnexal carcinomas have a predilection for the head and neck region, primarily the central face or T zone, with the age of onset being the second to ninth decades of life.³ They arise from pluripotent keratinocytes that possess the capability for adnexal differentiation.^{3,4} Predisposing factors include exposure to UV radiation, immunosuppression, and history of radiotherapy. Lesions typically have a benign histologic appearance, especially at the upper level of the tumor, and often can be confused with a syringoma or benign follicular neoplasm.

Clinically, MAC masquerades as a firm subcutaneous nodule, mimicking benign neoplasms. In the United States, there is a tendency for presentation of left-sided facial lesions due to greater UV exposure while driving an automobile, possibly indicating an etiologic role of exposure to UV radiation.⁵ Lesions typically are slow growing; however, one report highlighted the potential for abnormally fast growth and numerous MACs in an immunocompromised patient. The patient developed 10 tumors within 1 year.⁶ Despite their benign clinical appearance and slow growth, MACs display extensive local infiltration and commonly exhibit perineural invasion. When perineural invasion is present, patients often report paresthesia, discomfort, and burning at the tumor site.⁷

As illustrated in our patient, the initial superficial biopsy of an MAC usually is inadequate for diagnosis and may be misleading due to its bland microscopic appearance. One report of 48 patients found that 27% (13/48) of the cases were misdiagnosed on the first superficial biopsy.⁵ Histologically, MAC features a superficial dermis comprised of keratin horn cysts and islands or strands of basaloid keratinocytes with a deeper dermis consisting of ductal structures lined by 2 layers of cuboidal cells.¹ Stein et al⁸ observed that a biopsy of the superficial portion showing islands or strands of basaloid cells may be mistaken for a squamous cell carcinoma or infiltrative basal cell carcinoma, whereas an inadequate examination of deeper tissue composed of ductal or glandular structures may lead to an initial misdiagnosis of syringoma, trichoadenoma, or desmoplastic trichoepithelioma. Immunohistochemical studies for carcinoembryonic antigen, cytokeratin, and epithelial membrane antigen are not definitive in differentiating MAC from these neoplasms.⁹ Thus, light microscopy of an

Figure 3. Perineural invasion (A) and skeletal muscle involvement extending to peripheral and deep margins (B) was evident (H&E, original magnification $\times 40$ [both A and B]).



adequate deep biopsy specimen continues to be the gold standard for diagnosis.¹⁰ The microscopic diagnosis is supported by the lack of circumscription, deep dermal involvement, and perineural invasion.¹¹

Despite its locally aggressive behavior, MAC rarely metastasizes. From 1973 to 2004, SEER database identified 223 patients with MAC: 74% (163/223) of patients had skin-localized disease; 9% had disease that invaded underlying soft tissue, muscle, or bone; 1% had regional lymph node involvement; and less than 1% had metastatic disease.² Eisen and Zloty¹² reported 6 cases of metastatic MAC but there were no identifiable characteristics that could define the risk factors for metastases. Patients with MAC have a good prognosis, with a 97.7% survival rate at 10 years.² Due to the rarity of MAC and the excellent overall survival, various treatment modalities have been used, including surgical excision, radiation, chemotherapy, observation, and MMS.

Treatment with radiation therapy has been shown to be ineffective and can induce a more aggressive variant of the tumor.^{8,10} Prior radiation has been linked to an increased risk for MAC, as demonstrated in a case report of an 84-year-old man who developed MAC within the treatment field of radiation therapy for squamous cell carcinoma.¹³ Additionally, Abbate et al¹⁰ reported that 50% (5/10) of patients with MAC had prior radiation exposure, and Eisen and Zloty¹² found that patients developing MAC had a history of radiation exposure with an incidence rate of 19.5%. As a result, it is prudent to avoid radiation in most cases.

Mohs micrographic surgery is the treatment of choice. Due to the locally invasive nature of MACs, the tumor may extend centimeters beyond the clinical margins; a study that evaluated 26 cases of MAC found the difference between the mean area (square centimeter) of the lesion at presentation and the final mean defect area to be 15 cm² after an average of 3 stages.¹⁴ Chiller et al⁵ demonstrated that MMS accomplishes favorable cure rates with fewer procedures, as 30% (7/23) of patients treated with surgical

excision required additional procedures, while none of the 22 patients treated with MMS required additional treatment. Recurrence rates of MMS are lower than excision, ranging from 0% to 12% with MMS versus 60% with excision.^{11,15}

Congruent with prior reports, our case demonstrated perineural invasion. Salerno and Terrill¹⁶ reported that 59% (10/17) of patients exhibited perineural invasion. In a case report of 44 patients, Leibovitch et al¹⁷ identified that 85.7% (6/7) of cases with perineural invasion occurred in recurrent tumors. This feature of MAC further highlights the importance of complete tumor excision using modalities such as MMS.

Conclusion

Microcystic adnexal carcinoma may be clinically and histologically indistinguishable from follicular neoplasms. Practitioners should always consider MAC in the differential diagnosis of a slow-growing tumor, especially when located on the head and neck. It also is prudent to consider excision if there is any clinical suspicion for MAC, even in the presence of benign pathology. Radiation therapy should be discouraged, as it may promote tumor growth. Mohs microscopic surgery is the treatment of choice given its association with accurate surgical margins and low recurrence rates.

REFERENCES

1. Goldstein DJ, Barr RJ, Santa Cruz DJ. Microcystic adnexal carcinoma: a distinct clinicopathologic entity. *Cancer*. 1982;50:566-572.
2. Yu JB, Blitzblau RC, Patel SC, et al. Surveillance, Epidemiology, and End Results (SEER) database analysis of microcystic adnexal carcinoma (sclerosing sweat duct carcinoma) of the skin. *Am J Clin Oncol*. 2010;33:125-127.
3. Snow S, Madjar DD, Hardy S, et al. Microcystic adnexal carcinoma: report of 13 cases and review of the literature. *Dermatol Surg*. 2001;27:401-408.
4. Hamsch C, Hartschuh W. Microcystic adnexal carcinoma—aggressive infiltrative tumor often with innocent

- clinical appearance [in English, German][published online ahead of print September 24, 2009]. *J Dtsch Dermatol Ges.* 2010;8:275-278.
5. Chiller K, Passaro D, Scheuller M, et al. Microcystic adnexal carcinoma: forty-eight cases, their treatment, and their outcome. *Arch Dermatol.* 2000;136:1355-1359.
 6. Carroll P, Goldstein GD, Brown CW Jr. Metastatic microcystic adnexal carcinoma in an immunocompromised patient. *Dermatol Surg.* 2000;26:531-534.
 7. Yu Y, Finn DT, Rogers GS. Microcystic adnexal carcinoma: a rare, locally aggressive cutaneous tumor. *Am J Clin Oncol.* 2010;33:196-197.
 8. Stein JM, Ormsby A, Esclamado R, et al. The effect of radiation therapy on microcystic adnexal carcinoma: a case report. *Head Neck.* 2003;25:251-254.
 9. Wick MR, Cooper PH, Swanson PE, et al. Microcystic adnexal carcinoma: an immunohistochemical comparison with other cutaneous appendage tumors. *Arch Dermatol.* 1990;126:189-194.
 10. Abbate M, Zeitouni NC, Seyler M, et al. Clinical course, risk factors, and treatment of microcystic adnexal carcinoma: a short series report. *Dermatol Surg.* 2003;29:1035-1038.
 11. Wetter R, Goldstein GD. Microcystic adnexal carcinoma: a diagnostic and therapeutic challenge. *Dermatol Ther.* 2008;21:452-458.
 12. Eisen DB, Zloty D. Microcystic adnexal carcinoma involving a large portion of the face: when is surgery not reasonable? *Dermatol Surg.* 2005;31(11, pt 1): 1472-1478.
 13. Schwarze HP, Loche F, Lamant L, et al. Microcystic adnexal carcinoma induced by multiple radiation therapy. *Int J Dermatol.* 2000;39:369-372.
 14. Thomas CJ, Wood GC, Marks VJ. Mohs micrographic surgery in the treatment of rare aggressive cutaneous tumors: the Geisinger experience. *Dermatol Surg.* 2007;33: 333-339.
 15. Sebastien TS, Nelson BR, Lowe L, et al. Microcystic adnexal carcinoma. *J Am Acad Dermatol.* 1993;29(5, pt 2):840-845.
 16. Salerno S, Terrill P. Will MAC be back? *ANZ J Surg.* 2003;73:830-832.
 17. Leibovitch I, Huilgol SC, Selva D, et al. Microcystic adnexal carcinoma: treatment with Mohs micrographic surgery. *J Am Acad Dermatol.* 2005;52:295-300.