

Xanthoma Striatum Palmare Associated With Nonsyndromic Paucity of the Interlobular Bile Ducts

To the Editor:

A 1-year-old adopted boy presented to the dermatology clinic for evaluation of pruritus and yellow papules on his palms. The patient was born at term without complications. The medical history of his biological parents was unknown. He developed jaundice at 10 weeks of age. Laboratory evaluation revealed coagulopathy, hypercholesterolemia (total cholesterol, 1362 mg/dL [reference range, <200 mg/dL]; low-density lipoprotein, 1294 mg/dL [reference range, 65–180 mg/dL]; high-density lipoprotein, 20 mg/dL [reference range, 30–70 mg/dL]; triglycerides, 242 mg/dL [reference range, 45–155 mg/dL]) and abnormal liver function tests (alkaline phosphatase, 813 U/L [reference range, 33–131 U/L]; γ -glutamyltransferase, 1066 U/L [reference range, <65 U/L]; aspartate aminotransferase, 97 U/L [reference range, 20–48 U/L]; alanine aminotransferase, 194 U/L [reference range, <35 U/L]; total bilirubin, 19 mg/dL [reference range, 0.1–1.2 mg/dL]). A liver biopsy revealed pathologic findings worrisome for biliary atresia, and a Kasai procedure (hepatoportoenterostomy) was performed. Unfortunately, the Kasai procedure did not result in clinical improvement. His degree of hypercholesterolemia also was inconsistent with a diagnosis of biliary atresia, leading to an evaluation for Alagille syndrome. An extensive evaluation for Alagille syndrome was undertaken and was negative for triangular facies as well as abnormalities of the cardiovascular system, pulmonary vessels, vertebrae, or eyes.

Cutaneous examination revealed jaundice and scleral icterus. Figure 1 illustrates the white and yellow, soft, 3- to 6-mm papules over the extensor surfaces of the elbows consistent with tuberous xanthoma. Figure 2 shows the white 2- to 3-mm papules

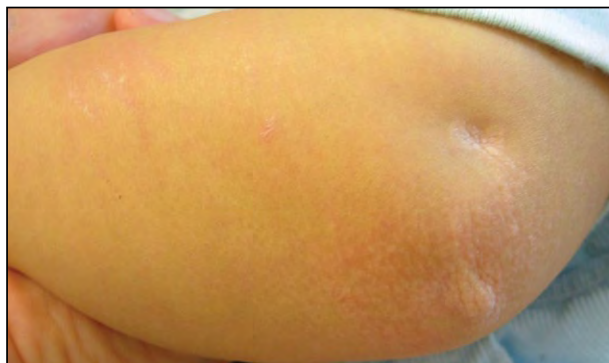

Figure 1. Soft, 3- to 6-mm, white and yellow papules on the extensor surfaces of the elbows consistent with tuberous xanthoma.

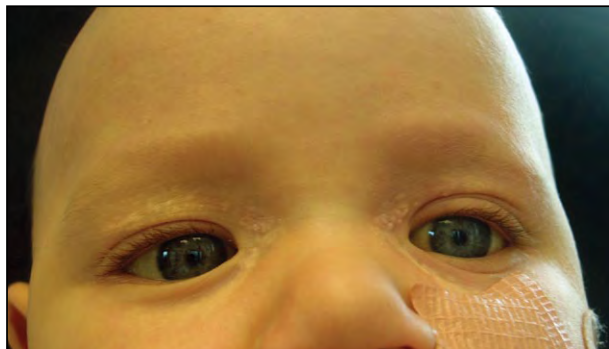


Figure 2. White 2- to 3-mm papules on the bilateral inner canthi consistent with xanthomas.

on the bilateral inner canthi. Figure 3 reveals the linear white plaques filling the palmar creases, consistent with xanthoma striatum palmare.

The patient underwent a liver transplant shortly thereafter. Within four months of his transplant he had complete resolution of the xanthomas. Pathologic examination of his native liver revealed severe cholestasis, duct loss with a lower than normal interlobular duct to portal tract ratio, and fibrosis.

Based on the histologic finding of paucity of the interlobular bile ducts and the absence of clinical features of Alagille syndrome, the patient was diagnosed with nonsyndromic paucity of the interlobular bile ducts (NS-PILBD). The family decided

Dr. Fett is from the Department of Dermatology, Oregon Health & Science University, Portland. Dr. Teng is from the Department of Dermatology, Stanford University, California.

The authors report no conflict of interest.

Correspondence: Nicole Fett, MD, Department of Dermatology, Oregon Health & Science University, 3303 SW Bond Ave, Portland, OR 97239 (fett@ohsu.edu).

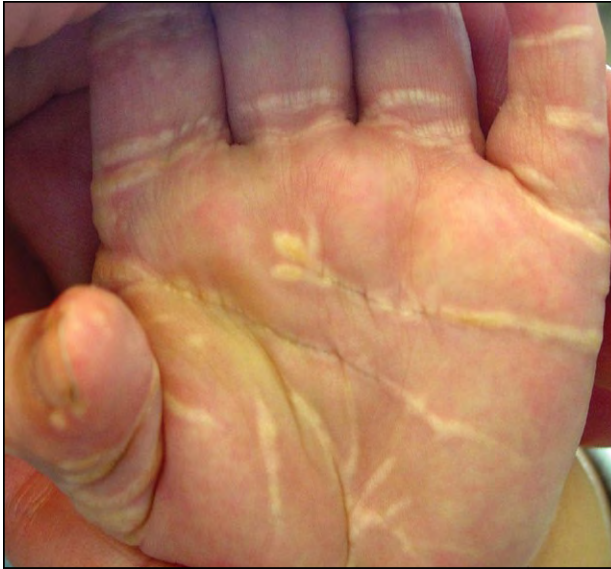

Figure 3. Linear white plaques filling the palmar creases consistent with xanthoma striatum palmare.

to postpone genetic testing for mutations of *JAG1* (jagged 1) and *NOTCH2* (notch 2), known etiologic mutations in Alagille syndrome.

Paucity of the interlobular ducts is divided into 2 categories: (1) syndromic paucity of the interlobular bile ducts, also known as Alagille syndrome, and (2) NS-PILBD. Alagille syndrome is an autosomal-dominant disorder with variable penetration resulting from mutations in the notch ligand *JAG1* or the notch receptor *NOTCH2*, encoded on chromosome 1 and 20, respectively.^{1,2} Seventy percent of cases result from sporadic mutations.^{1,3} In addition to histologic documentation of paucity of interlobular ducts, diagnosis of Alagille syndrome requires 3 of 5 additional criteria: chronic cholestasis, triangular facies, cardiovascular or pulmonary vascular abnormalities, vertebral arch defects, and posterior embryotoxon.^{1,3,4} Children with Alagille syndrome have increased levels of total cholesterol; triglycerides; phospholipids; low-density lipoprotein cholesterol; apolipoprotein E; and a lipoprotein unique to cholestatic states, lipoprotein-X.^{5,6} Xanthomas, including xanthoma striatum palmare, have been reported to occur in children with Alagille syndrome, and reports of complete resolution of xanthoma following a liver transplant also have been published.^{3,5,7-11} Although the etiologic mutations in Alagille syndrome are known, they are not currently included in the diagnostic criteria.⁷

Nonsyndromic paucity of the interlobular bile ducts is a less well-defined entity that has been associated with congenital metabolic diseases; viral

infections; congenital syphilis; trisomy 18 and 21; cystic fibrosis; α_1 -antitrypsin deficiency; and Ivemark syndrome, which has been linked to congenital asplenia and heterotaxy without characteristic cutaneous features.¹² Approximately 50% of NS-PILBD cases are considered idiopathic.¹²⁻¹⁴ None of the case series of NS-PILBD to date described xanthomas in their patients. None of the patients diagnosed with idiopathic NS-PILBD had genetic testing for the *JAG1* or *NOTCH2*, the etiologic mutations of Alagille syndrome. Therefore, it is unknown if idiopathic NS-PILBD is a subclinical variant of Alagille syndrome or a separate disease entity.

Nicole Fett, MD

Joyce M. Teng, MD, PhD

REFERENCES

- Li L, Krantz ID, Deng Y, et al. Alagille syndrome is caused by mutations in human Jagged1, which encodes a ligand for Notch1. *Nat Genet.* 1997;16:243-251.
- McDaniell R, Warthen DM, Sanchez-Lara PA, et al. *NOTCH2* mutations cause Alagille syndrome, a heterogeneous disorder of the notch signaling pathway. *Am J Hum Genet.* 2006;79:169-173.
- Garcia MA, Ramonet M, Ciocca M, et al. Alagille syndrome: cutaneous manifestations in 38 children. *Pediatr Dermatol.* 2005;22:11-14.
- Alagille D, Estrada A, Hadchouel M, et al. Syndromic paucity of interlobular bile ducts (Alagille syndrome or arteriohepatic dysplasia): review of 80 cases. *J Pediatr.* 1987;110:195-200.
- Gottrand F, Clavey V, Fruchart JC, et al. Lipoprotein pattern and plasma lecithin cholesterol acyl transferase activity in children with Alagille syndrome. *Atherosclerosis.* 1995;115:233-241.
- Nagasaka H, Kikuta H, Komatsu H, et al. Apolipoprotein E (ApoE) and ApoE-rich high-density cholesterol as potential early diagnostic markers of congenital biliary tract anomalies. *J Pediatr.* 2003;143:411.
- Buckley DA, Higgins EM, du Vivier AW. Resolution of xanthomas in Alagille syndrome after liver transplantation. *Pediatr Dermatol.* 1998;15:199-202.
- Cardona J, Houssin D, Gauthier F, et al. Liver transplantation in children with Alagille syndrome—a study of twelve cases. *Transplantation.* 1995;60:339-342.
- Emerick KM, Whittington PF. Partial external biliary diversion for intractable pruritus and xanthomas in Alagille syndrome. *Hepatology.* 2002;35:1501-1506.
- Ho NC, Lacbawan F, Francomano CA, et al. Severe hypodontia and oral xanthomas in Alagille syndrome. *Am J Med Genet.* 2000;93:250-252.
- Weston CF, Burton JL. Xanthomas in the Watson-Alagille syndrome. *J Am Acad Dermatol.* 1987;16(5, pt 2):1117-1121.

Case Letter

12. Kahn E, Daum F, Markowitz J, et al. Nonsyndromic paucity of interlobular bile ducts: light and electron microscopic evaluation of sequential liver biopsies in early childhood. *Hepatology*. 1986;6:890-901.
13. Kocak N, Gurakan F, Yuce A, et al. Nonsyndromic paucity of interlobular bile ducts: clinical and laboratory findings of 10 cases. *J Pediatr Gastroenterol Nutr*. 1997;24:44-48.
14. Yehezkely-Schildkraut V, Munichor M, Mandel H, et al. Nonsyndromic paucity of interlobular bile ducts: report of 10 patients. *J Pediatr Gastroenterol Nutr*. 2003;37:546-549.