

# Disseminated Verruciform Xanthoma: A Case Report

Randy Tang, MD; Sandra A. Kopp, MD; Carrie Cobb, MD; Analisa V. Halpern, MD

## Practice Points

- Verruciform xanthoma (VX) is a rare benign lesion typically found on the oral mucosa but can rarely be found in other cutaneous locations.
- The etiology of VX remains an enigma; some lesions may be the result of reactive phenomena to trauma or chronic local irritation, while others harbor a mutation in the *NSDHL* (NAD[P] dependent steroid dehydrogenaselike) gene that encodes for 3 $\beta$ -hydroxysteroid dehydrogenase cholesterol synthesis enzyme.
- Patients with VX may have associated systemic diseases or metabolic abnormalities including lymphedema, pemphigus vulgaris, lichen planus, systemic lipid storage disease, epidermolysis bullosa, or CHILD syndrome (congenital hemidysplasia with ichthyosiform erythroderma and limb defects).

*Verruciform xanthomas (VXs) are rare mucocutaneous lesions that can appear in isolation or in association with chronic inflammation, systemic diseases, or metabolic abnormalities. We report the case of a patient who presented with disseminated VX with oral, cutaneous, and genital involvement without an obvious underlying cause. Treatments including salicylic acid 40%, high-potency topical corticosteroids, antibiotics, and chlorhexidine failed to improve the lesions; however, the patient was satisfied with the cosmetic results of serial shave excisions. This case highlights a rare entity of unknown etiology. Further studies are needed to determine the cause of this mucocutaneous entity so that more effective treatment modalities can be elucidated.*

*Cutis.* 2014;93:307-310.

Verruciform xanthoma (VX) is a rare benign mucocutaneous lesion that was first reported in 1971.<sup>1</sup> It most commonly occurs in the oral cavity<sup>2</sup> but can appear on other mucosal surfaces, such as the anogenital region.<sup>3-6</sup> Clinically,

VX typically presents as a white, yellow-white, or red verrucous papule or plaque mimicking verrucous hyperplasia, verrucous carcinoma, or squamous cell carcinoma. Histologically, VX is characterized by the presence of foam cells, or xanthoma cells, within the papillary dermis between elongated parakeratinized epithelial rete ridges with varying degrees of both surface keratinization and subepithelial connective tissue inflammatory infiltrates. Unlike other types of xanthomata, there is no association with disorders of lipid metabolism.

The etiology of VX remains unclear, but its association with a spectrum of disorders suggests that it may be a reactive phenomenon. It has been hypothesized that chronic local irritation or trauma induces epidermal degeneration, allowing keratinocyte lipids to be phagocytosed by dermal histiocytes.<sup>7,8</sup> Organism colonization, cutaneous trauma, genetic predisposition, and inflammatory disorders all may play a role in VX formation.

## Case Report

A 44-year-old woman presented with gradually enlarging, pink, asymptomatic, hyperkeratotic papules and plaques of 20 years' duration on the anterior aspect of the left leg extending to the knee. She had been treated with unknown creams by a physician in El Salvador 7 years prior with no improvement of the lesions. Her medical history was remarkable for type 2 diabetes mellitus.

From the Division of Dermatology, Cooper University Hospital, Robert Wood Johnson Medical School, Camden, New Jersey.

The authors report no conflict of interest.

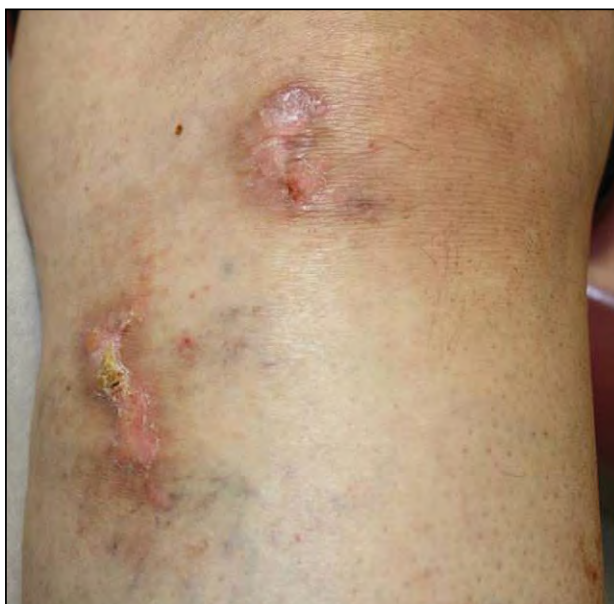Correspondence: Randy Tang, MD, 161 Ft Washington Ave, 12th Floor, New York, NY 10032 (rt2486@columbia.edu).

On clinical examination, multiple 0.5- to 1-cm pink, slightly raised, discrete, hyperkeratotic plaques with surrounding hyperpigmentation were noted on the dorsal aspect of the left foot, medial calf, and medial and lateral knee (Figure 1). Initial punch biopsies taken from the left medial and lateral knee revealed inconclusive pathologic results. Periodic acid-Schiff and Alcian blue staining revealed no fungi or basement membrane changes but highlighted mild dermal mucin deposition. Application of liquid nitrogen followed by a trial of salicylic acid 40% in petrolatum failed to resolve the lesions.

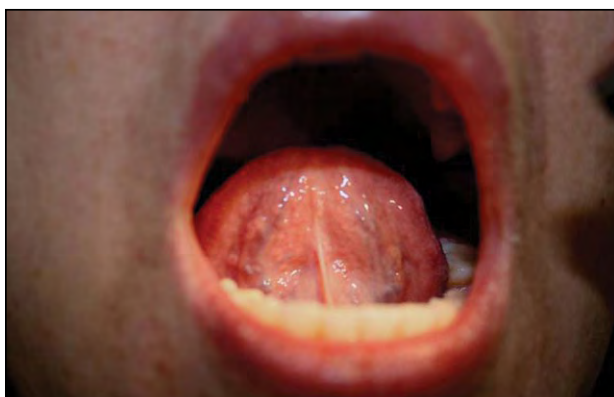Similar lesions were noted on the plantar aspect of the left foot and shin at a follow-up visit 1 month later. Additionally, several 2- to 3-mm pink papules were discovered in a sublingual distribution (Figure 2), on the buccal mucosa, hard palate, and left axilla. A 3- to 4-mm pink scaly plaque also was

observed along the border of the left labia majora. Shave biopsies from 2 separate lesions on the left knee were sent for hematoxylin and eosin staining; immunofluorescence; and bacterial, fungal, and mycobacterial cultures.

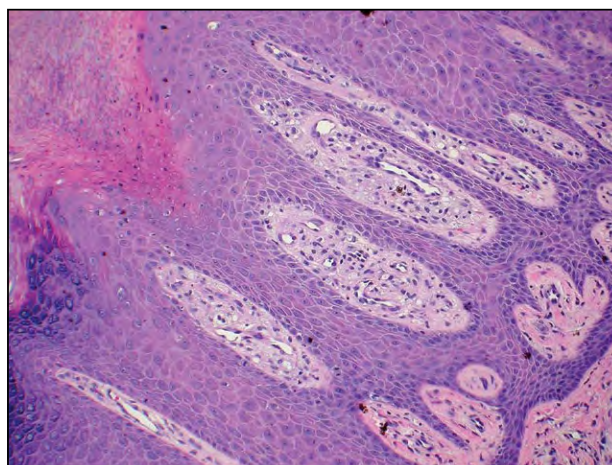
Routine light microscopy revealed hyperkeratosis, parakeratosis, hypogranulosis, papillomatosis, and acanthosis with elongation of rete ridges (Figure 3). Neutrophils were present in the stratum corneum, and the papillary dermis had a mild lymphocytic perivascular inflammatory infiltrate with collections of foam cells (Figure 4). These features were consistent with a diagnosis of VX. IgG, IgM, IgA, and C3 antibodies were not observed on immunofluorescence. Mycobacterial and fungal cultures grew



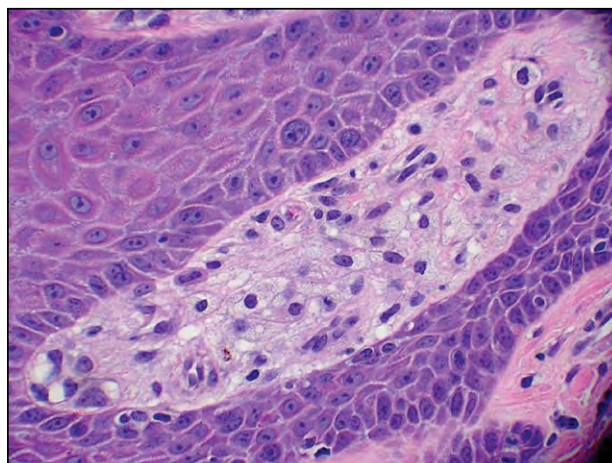
**Figure 1.** Hyperkeratotic pink plaques on the knee.



**Figure 2.** Sublingual 2- to 3-mm pink papules.



**Figure 3.** Low-power view revealed hyperkeratosis, parakeratosis, hypogranulosis, papillomatosis, and acanthosis with elongation of the rete ridges. The papillary dermis contained foam cell collections (H&E, original magnification  $\times 10$ ).



**Figure 4.** High-power view demonstrated the collection of foam cells in the papillary dermis (H&E, original magnification  $\times 40$ ).

no organisms after 6 weeks. There was scant growth of methicillin-resistant *Staphylococcus aureus*, which was sensitive to tetracycline. Antinuclear antibodies and lipid studies were normal. The patient was treated with twice-daily clobetasol dipropionate ointment 0.05% and oral doxycycline.

After 3 months, there seemed to be no subjective improvement of the lesions with the use of topical corticosteroids and oral antibiotics; however, the patient reported improvement in the appearance of the plaques at the sites of prior shave biopsies. A trial of chlorhexidine cleanser was initiated based on a prior report of success with antiseptic washes.<sup>9</sup> After 2 months of this treatment, the patient still reported no subjective improvement. Because the patient was happy with the results of the previously biopsied areas, she opted for serial excision of the remaining lesions.

### Comment

Verruciform xanthoma classically presents in the oral cavity as an asymptomatic solitary verrucous papule. Although extraoral involvement is uncommon, multifocal involvement is rarer and typically occurs in conjunction with preexisting inflammatory processes.<sup>10</sup> Nonmucosal cutaneous VX has been reported in association with metabolic abnormalities,<sup>7</sup> lymphedema,<sup>11</sup> and chronic inflammation and trauma,<sup>12</sup> as well as in conjunction with rare disorders such as CHILD syndrome (congenital hemidysplasia with ichthyosiform erythroderma and limb defects)<sup>13</sup> and capillary leak syndrome.<sup>14</sup> Verruciform xanthoma also has been associated with various systemic diseases such as pemphigus vulgaris,<sup>15</sup> lichen planus,<sup>16</sup> discoid lupus erythematosus,<sup>17</sup> dystrophic epidermolysis bullosa,<sup>18,19</sup> and systemic lipid storage disorder.<sup>20</sup>

Some investigators have postulated that the accumulation of foam cells is the primary event in the formation of VX, and the epidermal hyperplasia and inflammation occur secondarily.<sup>21</sup> In patients with lymphedema and associated VX, it is believed that the obstruction of lymphatic flow allows the exudation and accumulation of lipids in the subcutaneous tissue, which are subsequently scavenged by macrophages, thereby producing xanthomas.<sup>22</sup> An association with human papillomavirus infection largely has been disproven, as a multitude of studies have failed to detect human papillomavirus DNA by immunohistochemistry, in situ hybridization, or electron microscopy.<sup>23-25</sup>

In our case, there was suspicion that the development of VX changes was a reactive response to preexisting seborrheic keratoses; however, when similar lesions were discovered on the labia majora and in

the oral cavity, de novo growth from normal skin was suspected. The patient had no history of trauma, lymphedema, or inflammatory disease; therefore, the etiology of the lesions remained unclear.

We hypothesize that several different mechanisms may incite a cascade of events that ultimately converge into a common pathway leading to the formation of VX. Beyond the aforementioned inciting events, a genetic missense mutation in the *NSDHL* (NAD[P] dependent steroid dehydrogenaselike) gene that encodes for the 3 $\beta$ -hydroxysteroid dehydrogenase cholesterol synthesis enzyme has been discovered in a few VX cases.<sup>26</sup> Interestingly, patients with CHILD syndrome, a rare disorder characterized by mutational inactivation of the 3 $\beta$ -hydroxysteroid dehydrogenase cholesterol synthesis enzyme, have been reported to have concomitant VX lesions.

Although excision of isolated oral lesions is curative in most cases,<sup>27</sup> results from current treatment options for extraoral VX are relatively unsatisfactory. Reports of individuals with VX changes related to lymphedema have been successfully managed with leg compression, curettage, and electrodesiccation.<sup>11,14</sup> Connolly et al<sup>9</sup> reported a case of cutaneous VX that completely resolved with daily application of a chloroxylenol scrub for 8 weeks followed by 6 months of cleansing with povidone-iodine solution 10% after failed treatment with wire loop electrosection debridement, a 585-nm pulsed dye laser, and radiation therapy. Based on this report, we attempted a trial of chlorhexidine washes in our case. Ultimately, the patient reported satisfactory cosmetic results only with serial excisions.<sup>9</sup>

### Conclusion

Verruciform xanthoma is a rare, benign, asymptomatic lesion histologically characterized by papillary dermal foam cells and hyperkeratosis. Concurrent oral, genital, and cutaneous VX is an extremely rare finding. In 2004, Sopena et al<sup>28</sup> reported the first case of disseminated VX in a 42-year-old woman with multiple concomitant cutaneous, oral, and genital lesions arising from normal skin. Treatment of disseminated cases includes managing any underlying abnormalities such as leg compression for chronic lymphedema, as well as excision, electrodesiccation, or curettage of specific lesions.

### REFERENCES

1. Shafer WG. Verruciform xanthoma. *Oral Surg Oral Med Oral Pathol.* 1971;31:784-789.
2. Neville BW, Weathers DR. Verruciform xanthoma. *Oral Surg Oral Med Oral Pathol.* 1980;49:429-434.
3. Santa Cruz DJ, Martin SA. Verruciform xanthoma of the vulva. report of two cases. *Am J Clin Pathol.* 1979;71:224-228.

4. Requena L, Sarasa JL, Martin L, et al. Verruciform xanthoma of the penis with acantholytic cells. *Clin Exp Dermatol*. 1995;20:504-508.
5. Kimura S. Verruciform xanthoma of the scrotum. *Arch Dermatol*. 1984;120:1378-1379.
6. George WM, Azadeh B. Verruciform xanthoma of the penis. *Cutis*. 1989;44:167-170.
7. Zegarelli DJ, Zegarelli-Schmidt EC, Zegarelli EV. Verruciform xanthoma. further light and electron microscopic studies, with the addition of a third case. *Oral Surg Oral Med Oral Pathol*. 1975;40:246-256.
8. Balus S, Breathnach AS, O'Grady AJ. Ultrastructural observations on 'foam cells' and the source of their lipid in verruciform xanthoma. *J Am Acad Dermatol*. 1991;24(5, pt 1):760-764.
9. Connolly SB, Lewis EJ, Lindholm JS, et al. Management of cutaneous verruciform xanthoma. *J Am Acad Dermatol*. 2000;42(2, pt 2):343-347.
10. Mannes KD, Dekle CL, Requena L, et al. Verruciform xanthoma associated with squamous cell carcinoma. *Am J Dermatopathol*. 1999;21:66-69.
11. Snider RL. Verruciform xanthomas and lymphedema. *J Am Acad Dermatol*. 1992;27(6, pt 1):1021-1023.
12. Cumberland L, Dana A, Resh B, et al. Verruciform xanthoma in the setting of cutaneous trauma and chronic inflammation: report of a patient and a brief review of the literature. *J Cutan Pathol*. 2010;37:895-900.
13. Bittar M, Happle R. CHILD syndrome avant la lettre. *J Am Acad Dermatol*. 2004;50(2 suppl):s34-s37.
14. Wu JJ, Wagner AM. Verruciform xanthoma in association with milroy disease and leaky capillary syndrome. *Pediatr Dermatol*. 2003;20:44-47.
15. Gehrig RD, Baughman RA, Collins JF. Verruciform xanthoma in a young male patient with a past history of pemphigus vulgaris. *Oral Surg Oral Med Oral Pathol*. 1983;55:58-61.
16. Polonowita AD, Firth NA, Rich AM. Verruciform xanthoma and concomitant lichen planus of the oral mucosa. a report of three cases. *Int J Oral Maxillofac Surg*. 1999;28:62-66.
17. Pouloupoulos AK, Epivatianos A, Zaraboukas T, et al. Verruciform xanthoma coexisting with oral discoid lupus erythematosus. *Br J Oral Maxillofac Surg*. 2007;45:159-160.
18. Cooper TW, Santa Cruz DJ, Bauer EA. Verruciform xanthoma. occurrence in eroded skin in a patient with recessive dystrophic epidermolysis bullosa. *J Am Acad Dermatol*. 1983;8:463-467.
19. Orpin SD, Scott IC, Rajaratnam R, et al. A rare case of recessive dystrophic epidermolysis bullosa and verruciform xanthoma. *Clin Exp Dermatol*. 2009;34:49-51.
20. Travis WD, Davis GE, Tsokos M, et al. Multifocal verruciform xanthoma of the upper aerodigestive tract in a child with a systemic lipid storage disease. *Am J Surg Pathol*. 1989;13:309-316.
21. Mohsin SK, Lee MW, Amin MB, et al. Cutaneous verruciform xanthoma: a report of five cases investigating the etiology and nature of xanthomatous cells. *Am J Surg Pathol*. 1998;22:479-487.
22. Hunter JA, Morley WN, Peterkin GA. Xanthomatosis secondary to lymphoedema. *Trans St Johns Hosp Dermatol Soc*. 1970;56:143-148.
23. Ide F, Obara K, Yamada H, et al. Cellular basis of verruciform xanthoma: immunohistochemical and ultrastructural characterization. *Oral Dis*. 2008;14:150-157.
24. Iamaroon A, Vickers RA. Characterization of verruciform xanthoma by in situ hybridization and immunohistochemistry. *J Oral Pathol Med*. 1996;25:395-400.
25. Zegarelli DJ, Zegarelli-Schmidt EC, Zegarelli EV. Verruciform xanthoma. a clinical, light microscopic, and electron microscopic study of two cases. *Oral Surg Oral Med Oral Pathol*. 1974;38:725-734.
26. Mehra S, Li L, Fan CY, et al. A novel somatic mutation of the 3 $\beta$ -hydroxysteroid dehydrogenase gene in sporadic cutaneous verruciform xanthoma. *Arch Dermatol*. 2005;141:1263-1267.
27. Yu CH, Tsai TC, Wang JT, et al. Oral verruciform xanthoma: a clinicopathologic study of 15 cases. *J Formos Med Assoc*. 2007;106:141-147.
28. Sopena J, Gamo R, Iglesias L, et al. Disseminated verruciform xanthoma. *Br J Dermatol*. 2004;151:717-719.