

Acquired Progressive Lymphangioma in the Inguinal Area Mimicking Giant Condyloma Acuminatum

Jian-Wei Zhu, MD, PhD; Zhong-Fa Lu, MD, PhD; Min Zheng, MD, PhD

Practice Points

- Acquired progressive lymphangioma in the genital area is easily misdiagnosed and therefore requires careful examination.
- Wide excision of acquired progressive lymphangioma is suggested to prevent recurrence.

Lymphangioma is a benign proliferation of the lymphatic vessels that accounts for approximately 4% of vascular malformations and 26% of benign vascular tumors. Compared to those arising in nongenital areas, lymphangiomas of the vulva and genital areas are more hyperplastic, possibly due to the loose connective tissue, which can cause a cauliflowerlike appearance and may easily be misdiagnosed as genital warts or molluscum contagiosum. We report a case of acquired progressive lymphangioma (APL) of the inguinal area that mimicked giant condyloma acuminatum and showed favorable results following surgical excision. We also provide a review of the literature regarding the pathogenesis, diagnosis, differential diagnosis, and treatment of APL.

Cutis. 2014;93:316-319.

Lymphangioma is a benign proliferation of the lymphatic vessels that accounts for approximately 4% of vascular malformations and 26% of benign vascular tumors. It is considered to develop from sequestered lymphatic sacs that fail to

communicate with the peripheral draining channels.¹ Based on the clinical and pathologic characteristics, lymphangiomas are broadly classified as superficial (lymphangioma circumscriptum) or deep (cavernous lymphangioma).² There is no clear distinction between these 2 classifications, but the sole difference appears to be the extent of the malformation.³ Lymphangiomas also may be classified as simple, cavernous, or cystic according to the size of the vessels.

Congenital and acquired lymphangiomas also may be differentiated by cutaneous localization. Congenital lymphangiomas result from a hamartomatous malformation of lymphatic vessels, while acquired lymphangiomas are the result of acquired obstruction of lymphatic vessels induced by surgery, trauma, infection (eg, erysipelas, tuberculosis), cancer, radiation therapy, chronic inflammation, and other unknown causes. Compared to those arising in nongenital areas, lymphangiomas of the vulva and genital areas are more hyperplastic, possibly due to the loose connective tissue, which can cause a cauliflowerlike appearance and may easily be misdiagnosed as genital warts or molluscum contagiosum.⁴ We report a case of acquired progressive lymphangioma (APL) of the inguinal region that mimicked giant condyloma acuminatum and showed favorable results following surgical excision.

Case Report

A 38-year-old man presented with an asymptomatic excrescence on the right side of the inguinal region of 13 months' duration. The patient reported a

Dr. Zhu is from the Department of Dermatology, Sir Run Run Shaw Hospital, Zhejiang University School of Medicine, Hangzhou, China. Drs. Lu and Zheng are from the Department of Dermatology, The Second Affiliated Hospital, Zhejiang University School of Medicine. The authors report no conflict of interest.

Correspondence: Min Zheng, MD, PhD, The Second Affiliated Hospital, Zhejiang University School of Medicine, 88 Jiefang Rd, Hangzhou, Zhejiang 310009, China (minz@zju.edu.cn).

history of sexual activity approximately 1.5 years prior to presentation; 5 months later, small reddish papules developed on the right side of the inguinal region and on the glans penis with a typical condyloma appearance. Acetowhitening of the lesions was positive for condyloma acuminatum. Potent treatment was administered with electrodesiccation and subsequent use of interferon alfa-2b ointment (1,000,000 IU/5 g), with a dosage of approximately 1 g per day for 1 month.

The patient was free of disease for 4 months; then reddish papules reappeared in the same location in the inguinal region and gradually increased in size and number, overlapping to form a large cauliflower-like mass. New lesions also developed around the scrotum but not on the glans penis. The large mass had a frequent outflow of mucinous fluid that soiled the patient's clothing. On physical examination a 2×2×5-cm neoplasm with a smooth lustrous surface and slight oozing was noted on the right side of the inguinal region, mimicking giant condyloma acuminatum (Figure 1). The lesion was composed of many single pedunculated cystic papules; separation of the individual papules yielded bloody sticky secretions, and puncture of lesions led to a large outflow of thick clear fluid. There were scattered isolated lesions around the scrotum, but no involvement of the penis was noted.

Unlike the results from his initial presentation, repeat acetowhitening of the lesions was negative. Peripheral edema and enlarged inguinal lymph nodes were not detected. Computed tomography of the abdomen was normal. Pathologic evaluation of a biopsy from a sample lesion showed epidermal

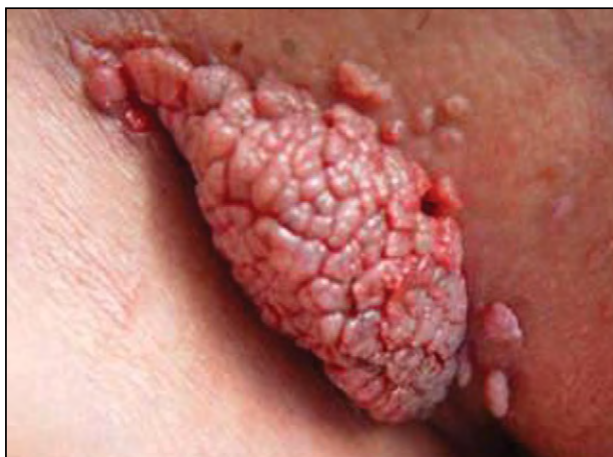

Figure 1. A 2×2×5-cm neoplasm with a smooth lustrous surface and cauliflowerlike appearance on the right side of the inguinal region.

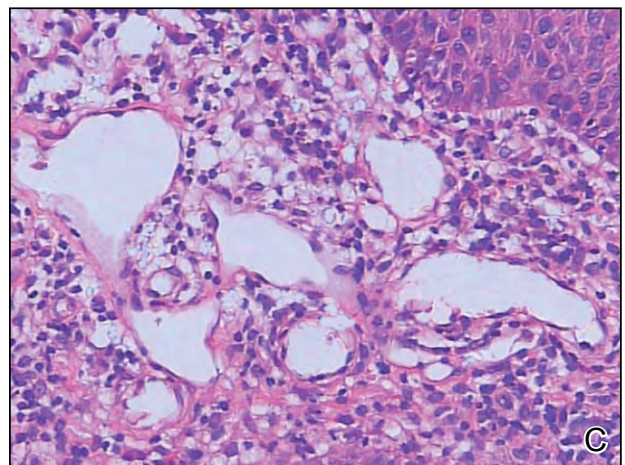
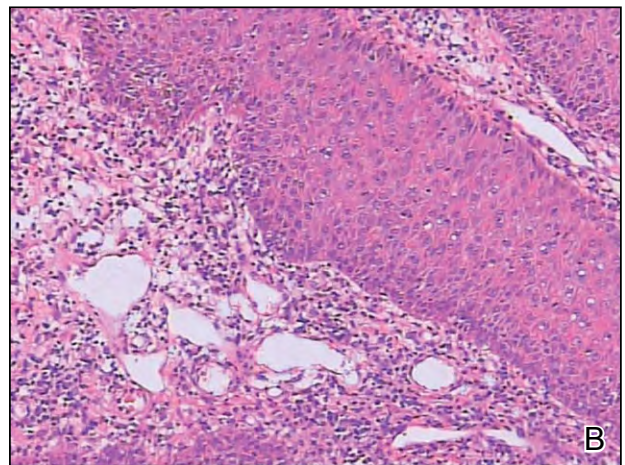
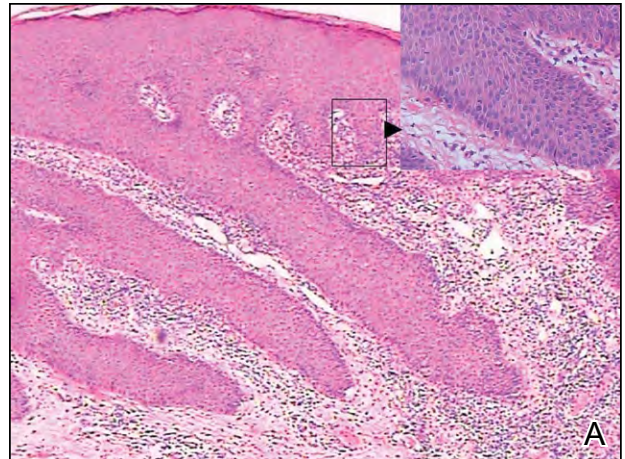


Figure 2. Pathologic examination revealed epidermal hyperplasia; acanthosis without koilocytes or atypical cells; and substantially dilated, thin-walled lymphatic vessels containing lymph fluid and some red blood cells in the dermis with moderate inflammatory cell infiltration (A–C)(H&E; original magnifications ×40 (×200 [inset]), ×100, and ×200, respectively).

hyperplasia; acanthosis without koilocytes; and substantially dilated, thin-walled lymphatic vessels containing lymph fluid and some red blood cells in the dermis with moderate infiltration of inflammatory cells (Figure 2).

Immunohistochemical staining of the dilated vessels for D2-40 antibody was positive, which indicated that the channels were lymphatic vessels (Figure 3). Staining was negative for Kaposi sarcoma–associated herpesvirus and human papillomavirus 6 and 11. Based on the clinical and histopathologic findings, a diagnosis of APL was made. Wide excision of the primary neoplasm was performed, and the smaller surrounding lesions were treated with cryotherapy. The patient was symptom free 5 years after treatment and follow-up is ongoing.

Comment

Acquired progressive lymphangioma, also known as benign lymphangioendothelioma, is a rare benign proliferation of lymphatic vessels caused by lymphatic malformation.³ Clinically, APL usually presents as a solitary, asymptomatic, erythematous patch or plaque on the trunk and limbs and occurs most commonly in adolescents and young adults,⁵ suggesting that a reactive process plays a role in the development of APL. One report described a 44-year-old woman with a history of Crohn disease and recurrent genital cellulitis who presented with a lymphangioma resembling genital warts. This case suggests that these 2 conditions—Crohn disease and recurrent cellulitis—likely are the main causes of genital lymphatic destruction, lymphedema, and lymphangioma.⁶ In our patient, the causative factor of

disease may have been due to the fulguration treatment, not a primary human papillomavirus infection.

Histopathologically, APL exhibits many dilated, tortuous, thin-walled lymphatic channels in the dermis.⁷ The vascular channels may have scanty proteinaceous material and some red blood cells. Immunohistochemically, the endothelial cells of APL variably stain positive for factor VIII, CD31, and CD34. D2-40 is the most sensitive and specific marker of lymphatic endothelium, which can further confirm the vascular vessels to be of lymphatic origin.⁷

Prior to surgery, careful consideration of the differential diagnosis of APL is important to exclude other potential gastrointestinal or genitourinary conditions (eg, cystic hygroma, hernia, hydrocele of the spermatic cord, torsion of an undescended testicle, genital warts [as in our patient]). Well-differentiated angiosarcoma and the patch stage or lymphangiomatous variant of Kaposi sarcoma should be considered, especially in high-risk populations prone to developing malignant neoplasms (eg, patients with human immunodeficiency virus, those with a history of radiotherapy or chronic lymphedema).^{8,9} Histologic features such as a lack of cellular atypia and mitotic figures or scanty inflammatory cells can exclude a diagnosis of an angiosarcoma.¹⁰

Verrucous hemangiomas are congenital vascular malformations that present histologically with reactive epidermal changes of hyperkeratosis, acanthosis, papillomatosis, and numerous dilated capillaries in the papillary dermis. These growths usually are located on the lower extremities and involvement generally is unilateral.¹¹

Various treatment modalities including cryotherapy, laser therapy, radiotherapy, and surgery have been suggested. In one report, 66% of cases (8/12) were treated by surgical excision with an excellent prognosis.¹⁰ Sclerotherapy also may be considered an alternative treatment. Because the individual lesions in our patient developed into one large neoplasm, surgery was the preferred treatment method. Due to the complex anatomical structure, wide excision, including subcutaneous tissues, was adopted to reduce recurrence.

Conclusion

We achieved a satisfying outcome in our patient with surgery. Our case serves to remind physicians of the rare clinical features of APL that are easily misdiagnosed as genital warts or malignant neoplasms.

REFERENCES

1. Kim JK, Yoo KS, Moon JH, et al. Gallbladder lymphangioma: a case report and review of the literature. *World J Gastroenterol.* 2007;13:320-323.
2. Flanagan BP, Helwig EB. Cutaneous lymphangioma. *Arch Dermatol.* 1977;113:24-30.

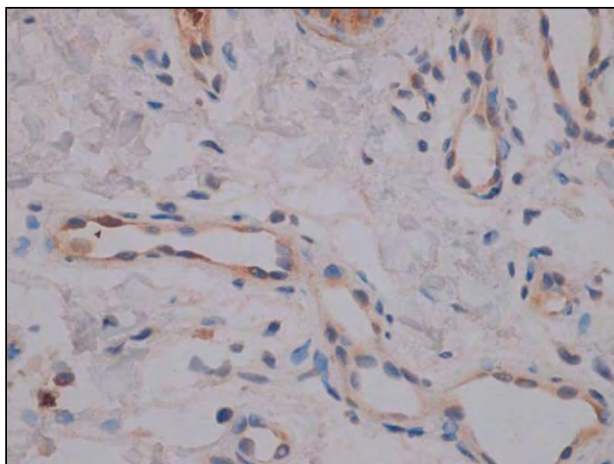


Figure 3. Immunohistochemically, the endothelial cells of the dilated vessels stained positive for D2-40, which is a sensitive and specific marker of lymphatic endothelium, indicating that the channels were of lymphatic origin (original magnification $\times 200$).

3. Rao R, Shenoi SD. Diseases of arteries, veins and lymphatics. In: Valia RG, Valia A, eds. *IADVL Textbook of Dermatology*. 3rd ed. Mumbai, India: Bhalani Publishing House; 2008:729-731.
4. Akimoto K, Nogita T, Kawashima M. A case of acquired lymphangioma of the vulva. *J Dermatol*. 1993;20:449-451.
5. Kato H, Kadoya A. Acquired progressive lymphangioma occurring following femoral arteriography. *Clin Exp Dermatol*. 1996;21:159-162.
6. Mu XC, Tran TA, Dupree M, et al. Acquired vulvar lymphangioma mimicking genital warts. a case report and review of the literature. *J Cutan Pathol*. 1999;26:150-154.
7. Lin SS, Wang KH, Lin YH, et al. Acquired progressive lymphangioma in the groin area successfully treated with surgery [published online ahead of print June 1, 2009]. *Clin Exp Dermatol*. 2009;34:e341-e342.
8. Rosso R, Gianelli U, Carnevali L. Acquired progressive lymphangioma of the skin following radiotherapy for breast carcinoma. *J Cutan Pathol*. 1995;22:164-167.
9. Paik AS, Lee PH, O'Grady TC. Acquired progressive lymphangioma in an HIV-positive patient. *J Cutan Pathol*. 2007;34:882-885.
10. Guillou L, Fletcher CD. Benign lymphangioendothelioma (acquired progressive lymphangioma): a lesion not to be confused with well-differentiated angiosarcoma and patch stage Kaposi's sarcoma: clinicopathologic analysis of a series. *Am J Surg Pathol*. 2000;24:1047-1057.
11. Tennant LB, Mulliken JB, Perez-Atayde AR, et al. Verrucous hemangioma revisited. *Pediatr Dermatol*. 2006;23:208-215.