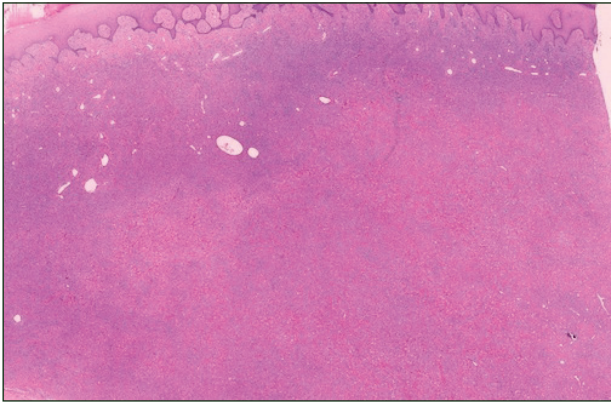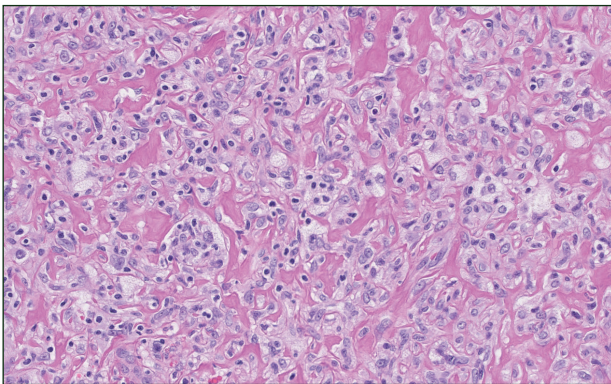


H&E, original magnification $\times 1.5$.



H&E, original magnification $\times 20$.

The best diagnosis is:

- a. eruptive xanthoma
- b. granular cell tumor
- c. lipidized dermatofibroma
- d. tuberous xanthoma
- e. xanthogranuloma

PLEASE TURN TO PAGE 187 FOR DERMATOPATHOLOGY DIAGNOSIS DISCUSSION

Amanda F. Marsch, MD; Ramayee Periakaruppan, MD; Marylee Braniecki, MD

From the University of Illinois at Chicago. Dr. Marsch is from the Department of Dermatology and Drs. Periakaruppan and Braniecki are from the Department of Pathology.

The authors report no conflict of interest.

Correspondence: Amanda F. Marsch, MD, University of Illinois at Chicago, 808 S Wood St, Chicago, IL 60612 (amandafmarsch@gmail.com).

Lipidized Dermatofibroma

Lipidized dermatofibromas most commonly are found on the ankles, which has led some authors to refer to these lesions as ankle-type fibrous histiocytomas.¹ Compared to ordinary dermatofibromas, patients with lipidized dermatofibromas tend to be older, most commonly presenting in the fifth or sixth decades of life, and are predominantly male. Lipidized dermatofibromas typically present as well-circumscribed solitary nodules in the dermis. Characteristic features include numerous xanthomatous cells dissected by distinctive hyalinized wiry collagen fibers (Figures 1 and 2).¹ Xanthomatous cells can be round, polygonal, or stellate in shape. These characteristic

features in combination with others of dermatofibromas (eg, epidermal acanthosis [Figure 1]) fulfill the criteria for diagnosis of a lipidized dermatofibroma. Additionally, lipidized dermatofibromas tend to be larger than ordinary dermatofibromas, which typically are less than 2 cm in diameter.¹

Eruptive xanthomas are characterized by a lace-like infiltrate of extravascular lipid deposits between collagen bundles (Figure 3).² Granular cell tumors are composed of sheets and/or nests of large cells with abundant eosinophilic cytoplasm and may be confused with lipidized dermatofibromas, as they also may induce overlying pseudoepitheliomatous hyperplasia³; however, on closer examination of the cells, the cytoplasm is found to be granular (Figure 4), which contrasts the finely vacuolated cytoplasm of xanthomatous cells found in

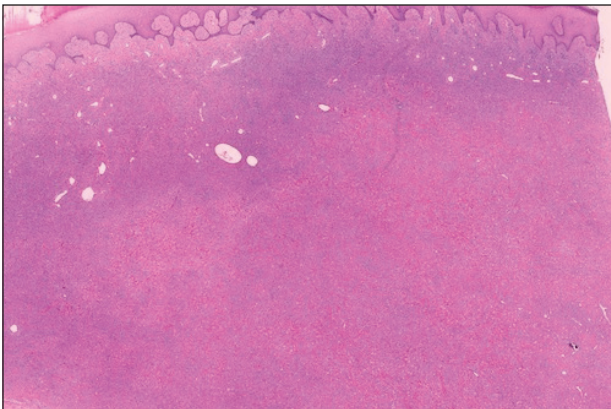


Figure 1. Lipidized dermatofibromas are characterized by classic epidermal features of dermatofibromas, such as acanthosis, along with numerous foam cells and extensive stromal hyalinization (H&E, original magnification $\times 1.5$).

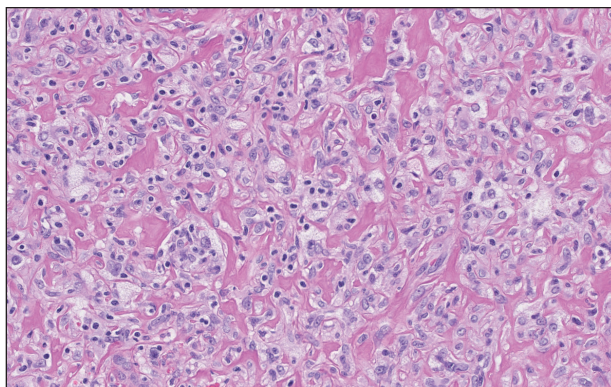


Figure 2. Higher-power view of a lipidized dermatofibroma shows the characteristic irregular dissection of hyalinized wiry collagen fibers between the xanthomatous cells (H&E, original magnification $\times 20$).

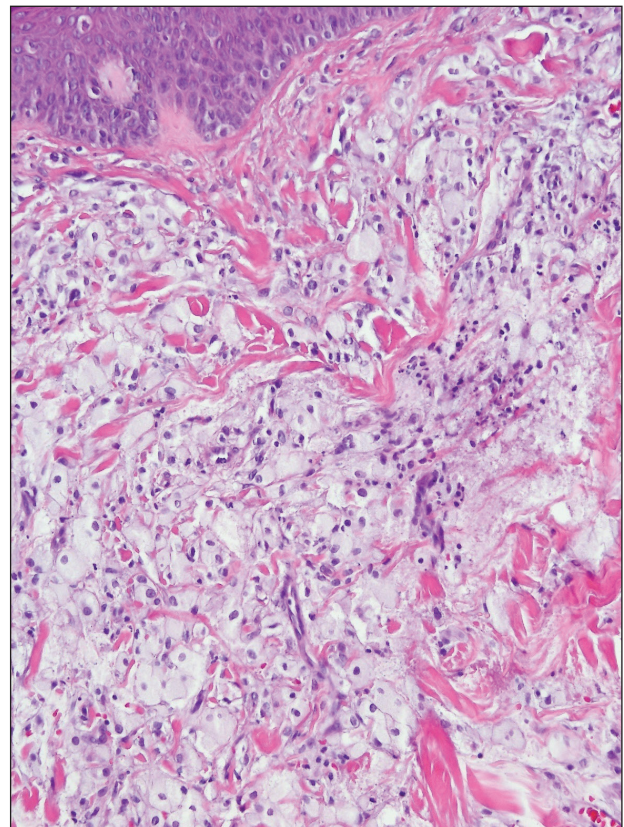


Figure 3. Lacelike deposition of extravascular lipid deposits is seen infiltrating between collagen bundles in an eruptive xanthoma (H&E, original magnification $\times 20$).

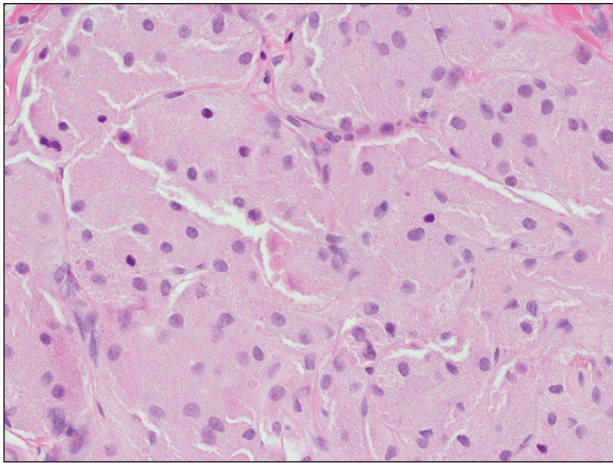


Figure 4. An abundant eosinophilic, finely granular cytoplasm is characteristic of granular cell tumor (H&E, original magnification $\times 40$).

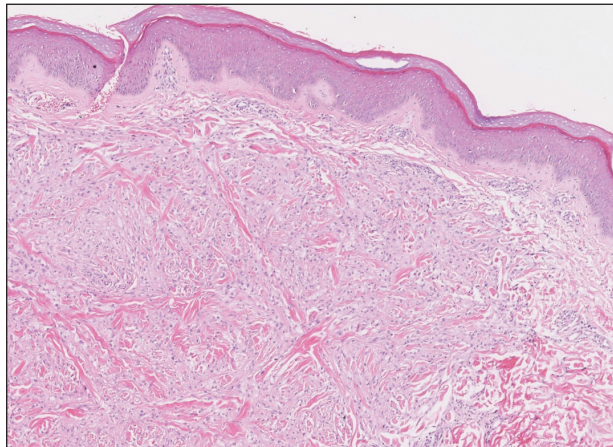


Figure 5. Large aggregates of foam cells separated by fibrous bands of a tuberous xanthoma (H&E, original magnification $\times 5$).

lipidized dermatofibromas. Giant lysosomal granules (eg, pustulo-ovoid bodies of Milian) are present in some cases.² Of note, an unusual variant of dermatofibroma exists that features prominent granular cells.⁴

Tuberous xanthomas most commonly occur around the pressure areas, such as the knees, elbows, and buttocks. Foam cells are a main feature of tuberous xanthomas and are arranged in large aggregates throughout the dermis.² Tuberous xanthomas lack Touton giant cells or inflammatory cells. Older lesions tend to develop substantial fibrosis

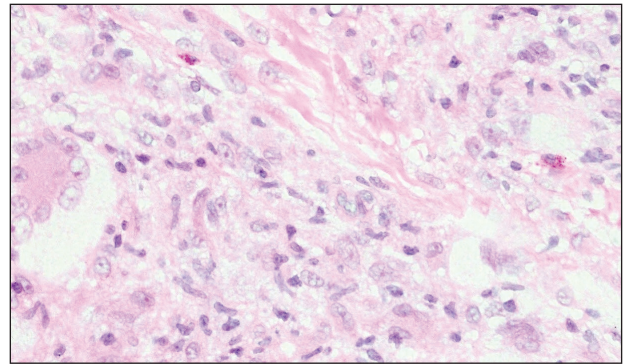


Figure 6. Touton giant cells, some surrounded by a peripheral rim of foamy cytoplasm, as well as scattered eosinophils are both features of xanthogranuloma (H&E, original magnification $\times 40$).

(Figure 5). Although foam cells can be present in older lesions, they are never as conspicuous as those found in other xanthomas.

Xanthogranulomas commonly occur on the head and neck. Findings noted on low magnification include a well-circumscribed exophytic nodule and an epidermal collarette, which help to easily distinguish xanthogranulomas from lipidized dermatofibromas. Additionally, the presence of a more prominent inflammatory infiltrate, which often includes eosinophils, as well as multinucleated Touton giant cells (Figure 6) and histiocytes with more eosinophilic and less xanthomatous cytoplasm can help distinguish between the lesions.^{1,5} Notably, Touton giant cells also can be seen in lipidized dermatofibromas,¹ but the presence of unique features such as distinctive stromal hyalinization are clues to the correct diagnosis of a lipidized dermatofibroma.

REFERENCES

1. Iwata J, Fletcher CD. Lipidized fibrous histiocytoma: clinicopathologic analysis of 22 cases. *Am J Dermatopathol.* 2000;22:126-134.
2. Weedon D. *Weedon's Skin Pathology.* 3rd ed. Edinburgh, Scotland: Elsevier Health Sciences; 2009.
3. Elston DM, Ferringer T. *Dermatopathology.* Philadelphia, PA: Saunders Elsevier; 2009.
4. Yogesh TL, Sowmya SV. Granules in granular cell lesions of the head and neck: a review. *ISRN Pathol.* 2011;2011:10.
5. Fujita Y, Tsunemi Y, Kadono T, et al. Lipidized fibrous histiocytoma on the left condyle of the tibia. *Int J Dermatol.* 2011;50:634-636.