

Sulfur Spring Dermatitis

Chieh-Chi Lee, MD; Yu-Hung Wu, MD

Practice Points

- The clinical findings of sulfur spring dermatitis are similar to those of a superficial second-degree burn.
- Careful evaluation of the patient's clinical history and recognition of characteristic findings are important for correct diagnosis.
- Patients with preexisting skin disorders who engage in thermal sulfur baths should be aware of the potential adverse effect of sulfur spring dermatitis.

Thermal sulfur baths are a form of balneotherapy promoted in many cultures for improvement of skin conditions; however, certain uncommon skin problems may occur after bathing in hot sulfur springs. We report the case of a 65-year-old man who presented with multiple confluent, punched-out, round ulcers with peripheral erythema on the thighs and shins after bathing in a hot sulfur spring. Histopathologic examination revealed homogeneous coagulation necrosis of the epidermis and papillary dermis. Tissue cultures showed no evidence of a microbial infection. The histopathologic findings and clinical course were consistent with a superficial second-degree burn. When patients present with these findings, sulfur spring dermatitis should be considered in the differential diagnosis. Moreover, the patient's clinical history is crucial for correct diagnosis.

Cutis. 2014;94:223-225.

Sulfur spring dermatitis is characterized by multiple punched-out erosions and pits. In prior case reports, patients often presented with painful swollen lesions that developed within 24 hours of bathing in hot sulfur springs.¹ Because spa therapy and thermal spring baths are common in modern society, dermatologists should be aware of sulfur spring dermatitis as a potential adverse effect.

Case Report

A healthy 65-year-old man presented with painful skin lesions on the legs that developed after bathing for 25 minutes in a hot sulfur spring 1 day prior. The patient had no history of dermatologic disease. He reported a 10-year history of bathing in a hot sulfur spring for 20 minutes every 3 days in the winter. This time, he bathed 5 minutes longer than usual. No skin condition was noted prior to bathing, but he reported feeling a tickling sensation and scratching the legs while he was immersed in the water. One hour after bathing, he noted confluent, punched-out, round ulcers with peripheral erythema on the thighs and shins (Figure 1).

A skin biopsy revealed sharply demarcated, homogeneous coagulation necrosis of the epidermis. Many neutrophils were present under the necrosis (Figure 2). Periodic acid-Schiff and acid-fast stains were negative for infectious organisms, and a skin tissue culture yielded negative results. Intensive wound care was started with nitrofurazone ointment 0.2%. The ulcers healed gradually

From the Department of Dermatology, Mackay Memorial Hospital, Taipei, Taiwan. Dr. Wu also is from Mackay Medical College, New Taipei City, Taiwan.

The authors report no conflict of interest.

Correspondence: Yu-Hung Wu, MD, Department of Dermatology, Mackay Memorial Hospital, 92, Sec 2, Zhongshan N Rd, Taipei City 10449, Taiwan (yuhung_wu@yahoo.com).

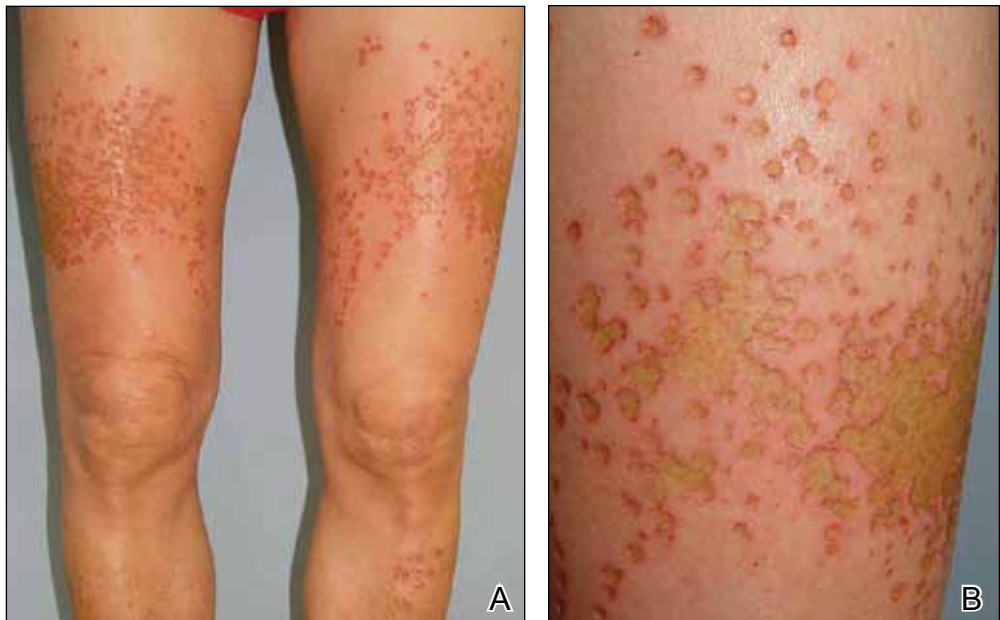

Figure 1. Multiple confluent, punched-out, round ulcers with peripheral erythema on the thighs and shins (A and B).

in the following months with scar formation and hyperpigmentation.

Comment

Thermal sulfur baths are a form of balneotherapy promoted in many cultures for improvement of skin conditions; however, certain uncommon skin problems may occur after bathing in hot sulfur springs.² In particular, sulfur spring dermatitis is a potential adverse effect.

Thermal sulfur water is known to exert anti-inflammatory, keratoplastic, and antipruriginous effects. As a result, it often is used in many cultures as an alternative treatment of various skin conditions.²⁻⁴ Moreover, thermal sulfur baths are popular in northeastern Asian countries for their effects on mental health.⁵ Hot springs in northern Taiwan, which contain large amounts of hydrogen sulfide, sulfate, and sulfur differ from other thermal springs in that they are rather acidic in nature and release geothermal energy from volcanic activity.⁶ In addition to hot sulfur springs, there are neutral salt and CO₂ springs in Taiwan.⁵ However, spring dermatitis has only been associated with bathing in hot sulfur springs due to high concentrations of hydrogen sulfide that break down keratin and cause dissolution of the stratum corneum.⁷

The incidence of sulfur spring dermatitis is unknown. Although the largest known case series reported 44 cases occurring within a decade in Taiwan,¹ it is rarely seen in our daily practice. Previously reported cases of sulfur spring dermatitis

noted clinical findings of swelling of the affected area followed by punched-out erosions with surrounding erythema. Most lesions gradually healed with dry brownish crusts. A patch test with sulfur spring water and sulfur compounds showed negative results; therefore, the mechanism is unlikely to be allergic reaction.¹ The clinical differential diagnosis includes factitious ulcers as well as viral and fungal infections. A tissue culture should be performed to exclude infectious conditions.

This characteristic skin disease does not present in all individuals after bathing in hot sulfur springs. Lesions may present anywhere on the body with a predilection for skin folds, including the penis and scrotum. Preexisting skin conditions such as pruritus and xerosis are considered to be contributing factors. The possible etiology of sulfur spring dermatitis may be acid irritation from the unstable amount of soluble sulfur in the water, which is enhanced by the heat.¹ In our patient, no prior skin disease was noted, but he scratched the skin on the thighs while bathing, which may have contributed to the development of lesions in this area rather than in the skin folds.

The skin biopsy specimen demonstrated epidermal coagulation necrosis, mild superficial dermal damage, and preservation of the pilosebaceous appendages. The ulcers were painful during healing and resolved with scarring and hyperpigmentation. The histopathologic findings and clinical course in our patient were similar to cases of superficial second-degree burns.⁸ It is possible that the

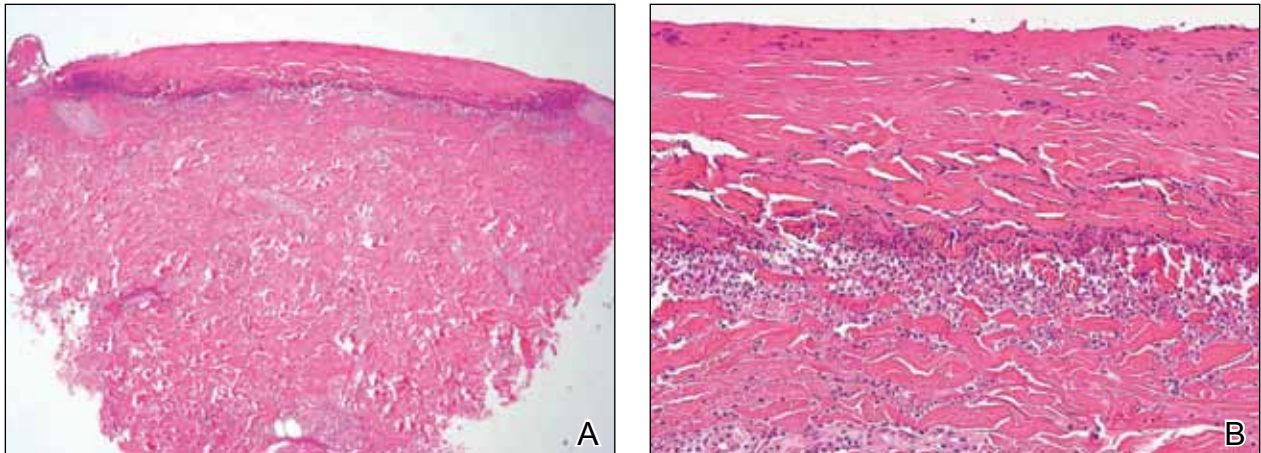


Figure 2. The epidermis showed sharply demarcated, homogeneous necrosis (A)(H&E, original magnification $\times 40$). Higher magnification demonstrated homogeneous coagulation necrosis of the epidermis, with many neutrophils present under the necrosis (B)(H&E, original magnification $\times 200$).

keratoplastic effect of sulfur at high concentrations along with thermal water caused the skin condition.

Conclusion

Individuals who engage in thermal sulfur baths should be aware of potential adverse effects such as sulfur spring dermatitis, especially those with preexisting skin disorders.

REFERENCES

1. Sun CC, Sue MS. Sulfur spring dermatitis. *Contact Dermatitis*. 1995;32:31-34.
2. Matz H, Orion E, Wolf R. Balneotherapy in dermatology. *Dermatol Ther*. 2003;16:132-140.
3. Leslie KS, Millington GW, Levell NJ. Sulphur and skin: from Satan to Saddam! *J Cosmet Dermatol*. 2004;3:94-98.
4. Millikan LE. Unapproved treatments or indications in dermatology: physical therapy including balneotherapy. *Clin Dermatol*. 2000;18:125-129.
5. Nirei H, Furuno K, Kusuda T. Medical geology in Japan. In: Selinus O, Finkelman RB, Centeno JA, eds. *Medical Geology: A Regional Synthesis*. New York, NY: Springer; 2010:329-354.
6. Liu CM, Song SR, Chen YL, et al. Characteristics and origins of hot springs in the Tatun Volcano Group in northern Taiwan. *Terr Atmos Ocean Sci*. 2011;22:475-489.
7. Lin AN, Reimer RJ, Carter DM. Sulfur revisited. *J Am Acad Dermatol*. 1988;18:553-558.
8. Weedon D. Reaction to physical agents. In: Weedon D. *Weedon's Skin Pathology*. 3rd ed. London, England: Churchill Livingstone, Elsevier Health; 2010:525-540.