

A Novel Technique for Reducing Intertrochanteric Hip Fractures

Anthony Andrés R. DePalma, MD, Kevin O'Halloran, MD, Kartik Shenoy, MD, Konrad I. Gruson, MD, and Alok D. Sharan, MD

Abstract

Intertrochanteric hip fractures typically become deformed by the muscular and gravitational forces acting on the 2 main bony fragments. Traditional use of a fracture table for anatomical reduction normally corrects for the varus angulation, external rotation, and posterior sag that can occur, but, in select unstable and comminuted fractures, reduction may not be possible because of posterior sag and external rotation of the proximal fragment.

These aspects of malreduction have been addressed in multiple ways, including use of unscrubbed assistants, crutches, internal rotation of the distal fragment by internal rotation of the foot, bumps and pads, and even intraoperative techniques. However, these techniques tend to adjust only 1 aspect of malreduction and may require intraoperative adjustment.

In this article, we describe a novel surgical device, the pneumatic patient positioner, that can be used to address these deformities without the need for intraoperative adjustment.

Intertrochanteric fractures are common hip fractures.¹ With the over-65 population continually increasing, the number of procedures a surgeon is expected to perform is likely to increase.² Obtaining adequate reduction is crucial, as intertrochanteric hip fractures with poor reductions are more than three times likely to progress to failure.³ Traditionally, intertrochanteric hip fractures are reduced on a fracture table. Applying longitudinal traction and internal rotation to the injured limb restores the length. However, doing so may not necessarily reduce the fracture, as in certain intertrochanteric fractures the proximal fragment can be pulled into or can fall into external rotation because of the forces applied by the short external rotators of the hip—thus complicating the reduction. Furthermore, internal rotation of the distal fragment during surgery is associated with malunion and

deformity, sometimes requiring revision surgery.⁴ Ideally, the distal fragment should be in the neutral or slightly externally rotated position during fixation, though this may complicate implant placement. This is especially common with comminuted and unstable intertrochanteric hip fractures, specifically type 31A2 fractures (Orthopaedic Trauma Association classification), where there is a posteromedial fragment.

In this article, we present a novel device, the pneumatic patient positioner (PPP), that can be used to correct for the external rotation and posterior sag of the proximal fragment in repairs of intertrochanteric hip fractures using traction on the fracture table. The PPP is noninvasive and simple to set up and use, and it requires no intraoperative adjustment. The patient described here provided written informed consent for print and electronic publication of this case report.

Technique

After intubation on the stretcher, the patient is placed supine on the fracture table. The well leg is then placed in the well-leg holder with the hip and knee flexed, externally rotated, and abducted, allowing C-arm access to the operative hip. A padded perineal post is placed at the groin so as not to compress the labia or scrotum. The foot of the operative leg is placed in the boot at the end of the fracture table, and the distal portion of the fracture table is removed. At this point, the PPP is used. An inflatable axillary roll device (Shoulder-Float; Ethox, Buffalo, New York) is placed deflated under the patient's buttocks on the operative side (Figure 1). A lateral film is subsequently taken by the C-arm (Figures 2A, 2B). The PPP is then sufficiently inflated to position the femoral neck parallel with the floor (position verified with lateral fluoroscopy), thereby ensuring that the intramedullary and cephalic guide wires will be parallel with the floor, easing placement. The operative site is then sterilely prepared and draped.

Discussion

Obtaining a closed anatomical reduction for intertrochanteric hip fractures can be technically difficult. Complicating the procedure are the deforming forces of gravity and the musculature of the hip. Depending on the fracture pattern, the proximal fragment can be pulled into external rotation secondary to the action of the short external rotators, while

Authors' Disclosure Statement: The authors report no actual or potential conflict of interest in relation to this article.

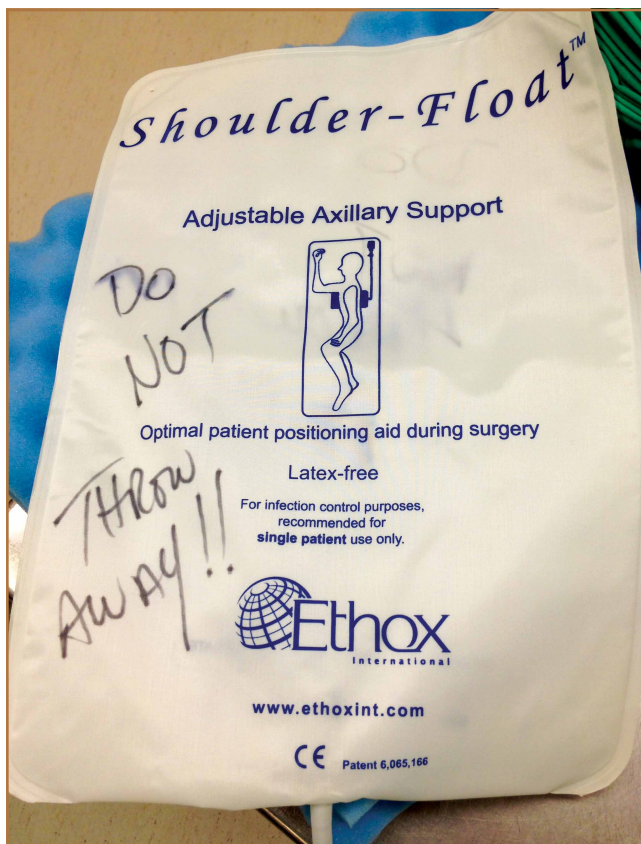


Figure 1. Adjustable axillary float (Shoulder-Float; Ethox, Buffalo, New York) before placement under patient's buttocks.

the distal fragment is pulled proximally and medially by the adductors and the hip flexors/extensors still attached to the distal fragment, resulting in a limb that is both shortened and in varus.⁴

Traditionally, intertrochanteric fractures are reduced on the fracture table. Placing the injured leg under traction returns appropriate limb length. However, another result is that the neutrally positioned distal fragment lies in internal rotation relative to the externally rotated proximal fragment. The surgeon can externally rotate the foot to obtain the reduction, but this leaves the entire extremity in external rotation.⁴ The surgeon must then negotiate the external rotation and the neck–shaft angle of the femoral neck simultaneously, complicating placement of the guide wire for the cephalic portion of the device. Proper guide-wire insertion would require an excessive drop of the surgeon's hand to account for the external rotation, and simultaneous negotiation of the neck–shaft angle and the anterior-to-posterior placement of the guide wire in the femoral neck. A common practice is to internally rotate the distal fragment with the intent to reduce the fracture and bring the femoral neck parallel with the floor. This technique, however, is suitable only for fractures in which the proximal and distal fragments move as one.⁴ Fractures with 2 independently moving fragments,

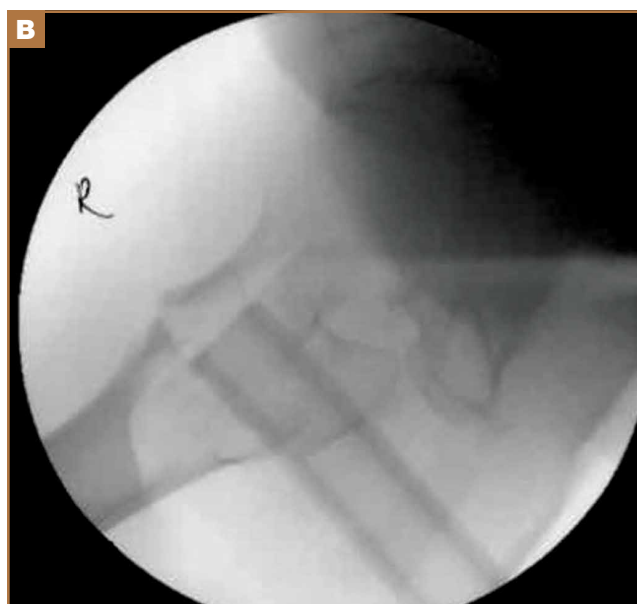
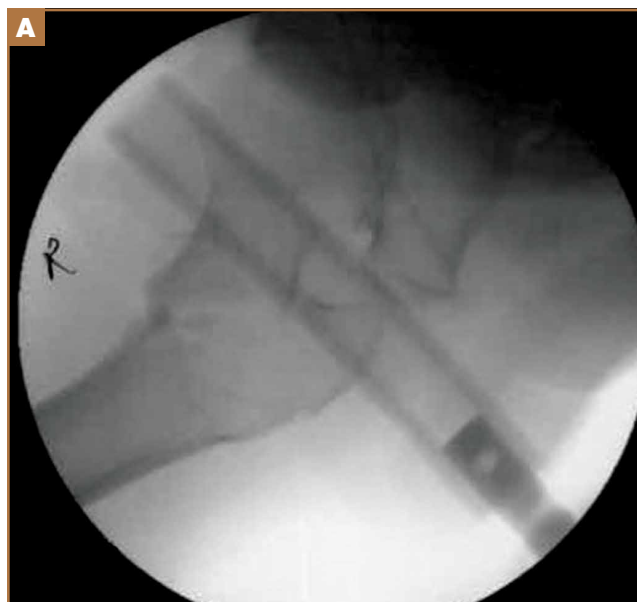
Figure 2. Intraoperative lateral fluoroscopy shows (A) external rotation of proximal fracture fragment and (B) internal rotation of proximal fragment after placement and inflation of pneumatic patient positioner with femoral neck now parallel with floor facilitating placement of intramedullary nail and ensuring optimal positioning of fracture fragments.

if fixed after internal rotation, often end up with a malrotation deformity that must be corrected.⁴ With our technique, there is no need to excessively rotate the distal fragment. Inflating the PPP internally rotates the proximal fragment until the femoral neck lies parallel with the floor. Doing so allows the femoral neck guide wire to also lie parallel with the floor, easing placement. The surgeon then has to negotiate the neck–shaft angle and the anterior-to-posterior placement of the guide wire within the femoral neck.

Potentially complicating the procedure is the downward force of gravity on the limb. Gravity may force both the distal and proximal fragments to slide posteriorly, resulting in a posterior sag. If not corrected, this displacement can lead to malpositioning of the cephalic hip screw and may even lead to iatrogenic fracture of the lateral trochanteric wall.^{5,6}

Many preoperative and intraoperative methods have been used to control for this defect. The most common is placement of a crutch below the thigh.^{4,7,8} This can elevate the distal fragment; if the 2 fragments happen to move together, the crutch can elevate both fragments. The limb's downward pressure on the crutch keeps it in place; however, slipping has been known to occur during the procedure and requires realignment by an unscrubbed assistant.⁹ In addition, the crutch may inhibit use of the C-arm by obstructing the space below the limb. Langford and Burgess⁶ advocated using a posterior reduction device (PORD) to improve the posterior sag. The PORD attaches to the fracture table and does not obstruct the C-arm. Similar to the crutch, the PORD cannot be positioned proximally enough to provide control over the proximal fragment. To completely reduce posterior sag while elevating only the distal fragment, the PORD relies on the proximal and distal fragments moving together to some extent.⁶ Occasionally, posterior sag is actually a manifestation of the overriding of the cortices of the proximal and distal fragments. This may necessitate an open reduction, as detailed by Carr.⁷ Bumps and pads have also been used for posterior sag, but they do not provide as precise or adjustable a lift as our technique does. Intraoperative management may also include lifting on the insertion handle during nail insertion or during pinning of the proximal fragment to the acetabulum, allowing independent movement of the distal fragment.⁴ The surgeon using the PPP can correct any external rotation, and varus angulation is corrected by traction on the distal fragment. The device can also correct for posterior sag, as it can raise the proximal and distal fragments simultaneously. There is also no need to intraoperatively correct the PPP. However, if needed, it can be inflated or deflated with ease by any of the unscrubbed staff in the room.

Conclusion

Intertrochanteric hip fractures are increasing in incidence but continue to present surgeons with technical challenges. Varus angulation, posterior sag, and malrotation, if not appropriately corrected for, can lead to postoperative deformity,

loss of function, and iatrogenic fracture.⁷ Crutches, bumps, unscrubbed assistants, and invasive techniques have all been used in the management of these complications.

The PPP quickly, easily, and cost-effectively addresses common impediments to reduction. Our device does not interfere with intraoperative radiography and does not require intraoperative manipulation (should manipulation become necessary, however, it can easily be performed). In addition, easy femoral neck guide-wire placement reduces the need for excessive intraoperative fluoroscopy. We have had no complications using this device. The PPP is another tool in the armamentarium for reducing intertrochanteric fractures.

Dr. DePalma is Resident, Department of Radiology, Rutgers Robert Wood Johnson Medical School, Piscataway, New Jersey. Dr. O'Halloran is Fellow, R. Adams Cowley Shock Trauma Center, Baltimore, Maryland. Dr. Shenoy is Resident, NYU Hospital for Joint Diseases, New York, New York. Dr. Gruson is Attending Physician, Department of Orthopaedic Surgery, and Dr. Sharan is Chief, Orthopaedic Spine Service, Montefiore Medical Center, Albert Einstein College of Medicine, Bronx, New York.

Address correspondence to: Alok D. Sharan, MD, Orthopaedic Spine Service, Montefiore Medical Center, Albert Einstein College of Medicine, 1250 Waters Place, 11th Floor, Bronx, NY (tel, 347-577-4559; fax, 347-577-4428; e-mail, asharan@montefiore.org).

Am J Orthop. 2014;43(9):402-404. Copyright Frontline Medical Communications Inc. 2014. All rights reserved.

References

1. Nieves JW, Bilezikian JP, Lane JM, et al. Fragility fractures of the hip and femur: incidence and patient characteristics. *Osteoporos Int.* 2010;21(3):399-408.
2. Brown CA, Starr AZ, Nunley JA. Analysis of past secular trends of hip fractures and predicted number in the future 2010–2050. *J Orthop Trauma.* 2012;26(2):117-122.
3. Baumgaertner MR, Curtin SL, Lindskog DM, Keggi JM. The value of the tip-apex distance in predicting failure of fixation of peritrochanteric fractures of the hip. *J Bone Joint Surg Am.* 1995;77(7):1058-1064.
4. Riehl JT, Widmaier JC. Techniques of obtaining and maintaining reduction during nailing of femur fractures. *Orthopedics.* 2009;32(8):581.
5. Joseph TN, Chen AL, Kummer FJ, Koval KJ. The effect of posterior sag on the fixation stability of intertrochanteric hip fractures. *J Trauma.* 2002;52(3):544-547.
6. Langford J, Burgess A. Nailing of proximal and distal fractures of the femur: limitations and techniques. *J Orthop Trauma.* 2009;23(5 suppl):S22-S25.
7. Carr JB. The anterior and medial reduction of intertrochanteric fractures: a simple method to obtain a stable reduction. *J Orthop Trauma.* 2007;21(7):485-489.
8. Koval KJ, Zuckerman JD. Hip fractures: II. Evaluation and treatment of intertrochanteric fractures. *J Am Acad Orthop Surg.* 1994;2(3):150-156.
9. Pape HC, Tarkin IS. Intraoperative reduction techniques for difficult femoral fractures. *J Orthop Trauma.* 2009;23(5 suppl):S6-S11.

This paper will be judged for the Resident Writer's Award.
