

Reliability of 3-Dimensional Glenoid Component Templating and Correlation to Intraoperative Component Selection

Comron Saifi, MD, Manish S. Noticewala, MD, R. Michael Greiwe, MD, Jonathan D. Lester, MD, Thomas R. Gardner, MCE, Edwin Cadet, MD, William N. Levine, MD, Louis U. Bigliani, MD, and Christopher S. Ahmad, MD

Abstract

Although implant-specific intraoperative targeting devices for glenoid sizing exist, a validated method for preoperatively templating glenoid component size in primary total shoulder arthroplasty (TSA) based on digital imaging does not.

We conducted a study to determine if 3-dimensional (3-D) digital imaging could be used for preoperative templating of glenoid component size and to compare templated glenoid sizes with implanted glenoid sizes. We created 3-D digital models from 3 glenoid component implant sizes and preoperative scapular computed tomography scans of 24 patients who underwent primary TSA. In study arm 1, surgeons templated the 3-D components using only 2 *df* (superior-inferior and anterior-posterior planes). In study arm 2, surgeons templated

the 3-D components using 6 *df* (superior-inferior, anterior-posterior, and rotational planes).

Overall intraobserver agreement was substantial (0.67) in study arm 1 ($P < .001$) and moderate (0.58) in study arm 2 ($P < .001$). In arm 1, overall interobserver agreement was fair (0.36) for trial 1 ($P < .001$) and fair (0.32) for trial 2 ($P < .001$). In arm 2, overall interobserver agreement was moderate (0.54) for trial 1 ($P < .001$) and moderate (0.43) for trial 2 ($P < .001$). In both arms, surgeons tended to template glenoid components smaller than those implanted intraoperatively, particularly for female patients.

Our findings show that 3-D digital models can be consistently and reliably used for preoperative templating of glenoid component size.

Take-Home Points

- Guidelines regarding glenoid component size selection for primary TSA are lacking.
- Intraoperative in situ glenoid sizing may not be ideal.
- 3-D digital models may be utilized for preoperative templating of glenoid component size in primary TSA.
- 3-D templating that allows for superior-inferior, anterior-posterior, and rotational translation can lead to consistent and reproducible templating of glenoid component size.
- 3-D templating may reduce the risks of implant overhang, peg penetration, and decreased stability ratio.

In 1974, Neer¹ introduced the shoulder prosthesis. In 1982, Neer and colleagues² found significant improvement in shoulder pain and function in patients with glenohumeral osteoarthritis treated with the Neer prosthesis. Since then, use of total shoulder arthroplasty (TSA) has increased. Between 1993 and 2007, TSA use increased 319% in the United States.³ Long-term outcomes studies have found implant survivorship ranging from 87% to 93% at 10 to 15 years.⁴

Although TSA is a successful procedure, glenoid component failure is the most common

Authors' Disclosure Statement: The authors report no actual or potential conflict of interest in relation to this article.

complication.⁵⁻¹⁰ Outcomes of revision surgery for glenoid instability are inferior to those of primary TSA.¹¹ Recent research findings highlight the effect of glenoid size on TSA complications.¹² A larger glenoid component increases the stability ratio (peak subluxation force divided by compression load).¹² However, insufficient glenoid bone stock, small glenoid diameter, and inability to fit a properly sized reamer owing to soft-tissue constraints may lead surgeons to choose a smaller glenoid component in order to avoid peg penetration, overhang, and soft-tissue damage, respectively. Therefore, preoperative templating of glenoid size is a potential strategy for minimizing complications.

Templating is performed for proximal humeral components, but glenoid sizing typically is deferred to intraoperative in situ sizing with implant-specific targeting guides. This glenoid sizing practice arose out of a lack of standard digital glenoid templates and difficulty in selecting glenoid size based on plain radiographs and/or 2-dimensional (2-D) computed tomography (CT) scans. However, targeting devices are sporadically used during surgery, and intraoperative glenoid vault dimension estimates derived from visualization and palpation are often inaccurate. Often, rather than directly assess glenoid morphology, surgeons infer glenoid size from the size and sex of patients.¹³

Three-dimensional (3-D) CT can be used to accurately assess glenoid version, bone loss, and implant fit.¹⁴⁻¹⁹ We conducted a study to determine if 3-D digital imaging can be consistently and reproducibly used for preoperative templating of glenoid component size and to determine if glenoid sizes derived from templating correlate with the sizes of subsequently implanted glenoids.

Materials and Methods

This retrospective study was conducted at the Center for Shoulder, Elbow, and Sports Medicine at Columbia University Medical Center in New York City and was approved by our Institutional Review Board. Included in the study were all patients who underwent primary TSA for primary glenohumeral osteoarthritis over a 12-month period. Patients were required to have preoperative CT performed according to our study protocol. The CT protocol consisted of 0.5-mm axial cuts of the entire scapula and 3-D reconstruction of the scapula, glenoid, glenohumeral articulation, and proximal humerus. Patients were excluded from the study for primary TSA for a secondary cause of glenohumeral osteoarthritis, inflammatory ar-

thritis, connective tissue disease, prior contralateral TSA, and prior ipsilateral scapula, glenoid, and proximal humerus surgery. Ultimately, 24 patients were included in the study.

CT data were formatted for preoperative templating. The CT images of each patient's scapula were uploaded into Materialise Interactive Medical Image Control System (Mimics) software. Mimics allows 3-D image rendering and editing from various imaging modalities and formats. The software was used to create the 3-D scapula models for templating. Prior studies have validated the anatomical precision of 3-D models created with Mimics.²⁰

Mimics was also used to digitize in 3-D the glenoid components from the Bigliani-Flatow Shoulder System (Zimmer Biomet). Glenoid components of 3 different sizes (40 mm, 46 mm, 52 mm) were used. (The Bigliani glenoid component was digitized, as this implant system was used for primary TSA in all 24 patients.) Each glenoid component was traced in 3-D with a Gage 2000 coordinate-measuring machine (Brown & Sharpe) and was processed with custom software. The custom software, cited in previous work by our group,¹⁷ created the same coordinate system for each scapula based on anatomical reference points. These digitized 3-D images of glenoid components were uploaded with the digitized 3-D scapulae derived from patients' CT scans to the Magics software. Magics allows for manipulation and interaction of multiple 3-D models by creating electronic stereolithography files that provide 3-D surface geometry.

Three fellowship-trained shoulder surgeons and 4 shoulder fellows templated the most appropriately sized glenoid component for each of the 24 patients. At the time of templating, the surgeon was blinded to the size of the glenoid implant used in the surgery. In Magics, each scapula was positioned in 3-D similar to how it would appear with the patient in the beach-chair position during surgery. In both study arms, surgeons selected the largest component that maximized the area of contact while avoiding peg penetration of the glenoid vault or component overhang. In addition, surgeons were instructed to correct glenoid version to as near neutral as possible with component positioning but were not permitted to remove glenoid bone stock to correct deformity. All surgeons based placement of the glenoid component on the patient's actual bone stock and not on osteophytes, which are readily appreciable on 3-D CT.

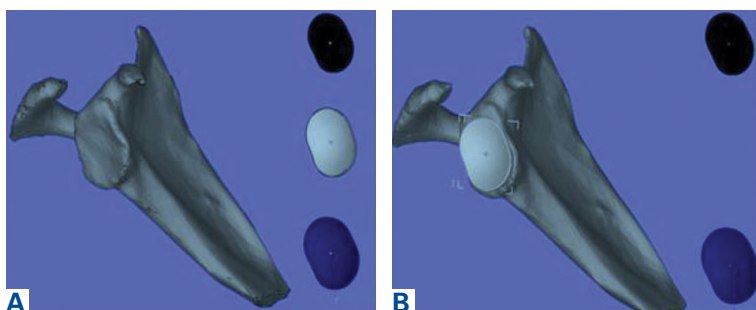


Figure 1. (A) Three-dimensional computer modeling for study arm 1 with (B) 2-dimensional translation of size a 46 three-dimensional glenoid component template.

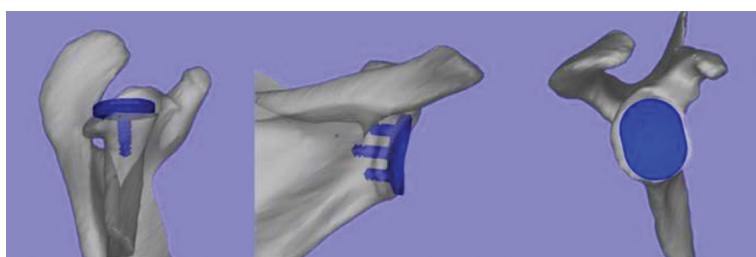

Figure 2. Three-dimensional (3-D) computer modeling for study arm 2 shows 3-D rotation of scapula and glenoid component during positioning of a size 52 glenoid component template.

Table 1. Agreement Categorization Based on κ Coefficients

Agreement	κ
Slight	0.00-0.20
Fair	0.21-0.40
Moderate	0.41-0.60
Substantial	0.61-0.80
Excellent	0.81-1.00

In study arm 1, the 3-D view of the glenoid was restricted to the initial view in the beach-chair position. The surgeon then manipulated the 3-D glenoid component template across a single 2-D plane, either the superior-inferior plane or the anterior-posterior plane, over the surface of the 3-D glenoid (Figure 1). This allowed 2 *df*: translation in the superior-inferior plane and translation in the anterior-posterior plane. This templating simulation was thought analogous to intraoperative component size selection under ideal circumstances of complete glenoid exposure.

In study arm 2, surgeons were permitted to rotate the 3-D glenoid template and scapula in any manner (Figure 2). Hence, this arm allowed for 6

df: superior-inferior translation, anterior-posterior translation, clockwise-counterclockwise rotation, anteversion-retroversion, superior-inferior tilt, and medial-lateral tilt. This added maneuverability allowed complete visualization of glenoid component peg containment and overhang as well as desired version correction.

Interobserver agreement was determined by comparing prosthetic glenoid component size selection among all study surgeons, and intraobserver agreement was determined by comparing glenoid size selection during 2 sessions separated by at least 3 weeks. After each trial, the order of patients' scapula images was randomly rearranged to reduce recall bias. Kappa (κ) coefficients were calculated for interobserver and intraobserver agreement. Kappas ranged from -1.0 (least agreement) to $+1.0$ (complete agreement). A κ of 0 indicated an observer selection was equivalent to random chance. The level of agreement was categorized according to κ using a system described by Landis and Koch²¹ (Table 1). Statistical significance for differences in glenoid size selection during surgery and during preoperative templating as a function of male and female patients was determined with χ^2 test. All statistical tests were run with SAS software (SAS Institute).

Results

The group of 24 patients consisted of 15 men and 9 women. Mean age was 70.3 years (range, 56-88 years). Primary TSA was performed in 14 right shoulders and 10 left shoulders. Of the 24 patients, 20 (83%) had a 46-mm glenoid component implanted, 3 male patients had a 52-mm glenoid component implanted, and 1 female patient had a 40-mm glenoid component implanted.

Study Arm 1: Glenoid Templating Based on 2 *df*

In study arm 1 (see Figure 3 for study design), a mean correlation of 0.49 (moderate agreement) was found between glenoid component size in 3-D templating with 2 *df* (translation in superior-inferior and anterior-posterior planes) and the glenoid component size ultimately selected during surgery (Table 2). Subanalysis of the TSA surgeons' intraoperative decisions relative to their 3-D templating selections revealed a mean correlation of 0.60 (substantial agreement). In 35% of patients, the component selected during templating was smaller than the component selected during surgery; in 16% of patients, the component was larger. Subanalysis of the TSA surgeons' decisions revealed that, during

templating, a smaller component was selected in 32% of patients and a larger component in 7%. During surgery, a smaller component was selected in 23% of male patients and 4% of female patients, and a larger component in 23% of male patients and 54% of female patients ($P < .001$).

In study arm 1, overall intraobserver agreement was substantial, as defined in the statistical literature.²¹ Among all surgeons who participated, intraobserver agreement was 0.76 (substantial), 0.60 (substantial), and 0.58 (moderate) for the 40-mm, 46-mm, and 52-mm glenoid components, respectively (overall $\kappa = 0.67$, substantial agreement). Trial 1 interobserver agreement was 0.56 (moderate) ($P < .001$), 0.25 (fair) ($P < .001$), and 0.21 (fair) ($P < .001$) for the 40-mm, 46-mm, and 52-mm glenoid components, respectively (overall $\kappa = 0.36$, fair agreement) ($P < .001$), and trial 2 interobserver agreement was 0.58 (moderate) ($P < .001$), 0.18 (poor) ($P = .003$), and 0.24 (fair) ($P < .001$) for the 40-mm, 46-mm, and 52-mm glenoid components, respectively (overall $\kappa = 0.32$, fair agreement) ($P < .001$). In study arm 1, therefore, trials 1 and 2 both showed fair interobserver agreement.

Study Arm 2: Glenoid Templating Based on 6 df

In study arm 2, a mean correlation of 0.42 (moderate agreement) was found between glenoid component size in 3-D templating and the glenoid component size ultimately selected during surgery (Table 3). Subanalysis of the TSA surgeons' intraoperative decisions relative to their templating selections revealed a mean correlation of 0.54 (moderate agreement). In 30% of patients, the component selected during templating was smaller than the component selected during surgery; in 28% of patients, the component was larger. Subanalysis of the TSA surgeons' decisions revealed that, during templating, a smaller component was selected in 27% of patients and a larger component in 16%. During surgery, a smaller component was selected in 42% of male patients and 4.8% of female patients, and a larger component in 17% of male patients and 52% of female patients ($P < .001$).

In study arm 2, overall intraobserver agreement was moderate. Among all surgeons who participated, intraobserver agreement was 0.80 (excellent), 0.43 (moderate), and 0.47 (moderate) for the 40-mm, 46-mm, and 52-mm glenoid components, respectively (overall $\kappa = 0.58$, moderate agreement). Trial 1 interobserver agreement was 0.75 (substantial) ($P < .001$), 0.39 (fair) ($P < .001$), and 0.50

Table 2. Intraobserver Agreement (κ) for Study Arm 1: Three-Dimensional (3-D) Glenoid Component Templating Without 3-D Manipulation

Agreement	Glenoid Component Size			Overall
	40 mm	46 mm	52 mm	
Study arm 1	0.76	0.60	0.58	0.67
Trial 1	0.56	0.25	0.21	0.36
Trial 2	0.58	0.18	0.24	0.32

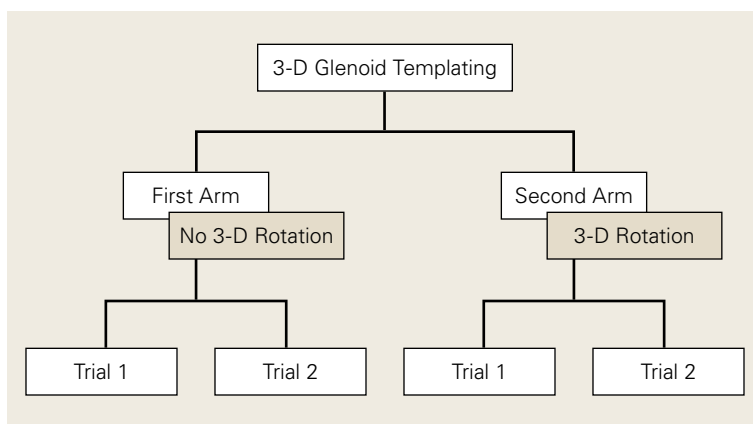


Figure 3. Diagram of study design.

(moderate) ($P < .001$) for the 40-mm, 46-mm, and 52-mm glenoid components, respectively (overall $\kappa = 0.54$, moderate agreement) ($P < .001$), and trial 2 interobserver agreement was 0.66 (substantial) ($P < .001$), 0.28 (fair) ($P = .003$), and 0.40 (moderate) ($P < .001$) for the 40-mm, 46-mm, and 52-mm glenoid components, respectively (overall $\kappa = 0.43$, moderate agreement) ($P < .001$).

Discussion

Our results showed that 3-D glenoid templating had reproducible intraobserver and interobserver

Table 3. Intraobserver Agreement (κ) for Study Arm 2: Three-Dimensional Glenoid Component Templating With 3-D Manipulation

Agreement	Glenoid Component Size			Overall
	40 mm	46 mm	52 mm	
Study arm 2	0.80	0.43	0.47	0.58
Trial 1	0.75	0.39	0.50	0.54
Trial 2	0.66	0.28	0.40	0.43

agreement. Overall intraobserver agreement was substantial ($\kappa = 0.67$) for study arm 1 and moderate ($\kappa = 0.58$) for study arm 2. Interobserver agreement was fair for trials 1 and 2 ($\kappa = 0.36$ and 0.32) in arm 1 and moderate for trials 1 and 2 ($\kappa = 0.54$ and 0.43) in arm 2.

Intraobserver and interobserver agreement values, particularly in study arm 2, which incorporated rotation (6 *df*), are consistent with values in commonly used classification systems, such as the Neer system for proximal humerus fractures, the Frykman system for distal radius fractures, and the King system for adolescent idiopathic scoliosis.²²⁻³⁰ Sidor and colleagues²⁷ found overall interobserver agreement of 0.50 and overall intraobserver agreement of 0.66 for the Neer system, and Illarramendi and colleagues²⁴ found overall interobserver agreement of 0.43 and overall intraobserver agreement of 0.61 for the Frykman system.

In study arm 2, overall interobserver and intraobserver agreement was moderate. A higher level of surgeon agreement is unlikely given the lack of well-defined parameters for determining glenoid component size. Therefore, glenoid size selection is largely a matter of surgeon preference. More research is needed to establish concrete guidelines for glenoid component size selection. Once guidelines are adopted, interobserver agreement in templating may increase.

In both study arms, the component that surgeons selected during templating tended to be smaller than the component they selected during surgery. In study arm 1, 32% of patients had a smaller component selected based on computer modeling, and 7% had a larger component selected. In study arm 2, the difference was narrower: 27% of patients had a smaller component selected during templating, and 16% had a larger component selected. A statistically significant difference ($P < .001$) in templated and implanted component sizes was found between men and women: Templated glenoid components were smaller than implanted components in 53% of women and larger than implanted components in 33% of men. Differences between templated and implanted components may be attributable to visualization differences. During templating, the entire glenoid can be visualized and the slightest peg penetration or component overhang detected; in contrast, during surgery, anatomical constraints preclude such a comprehensive assessment.

Differences in agreement between templated and implanted glenoid components suggest that

the size of implanted components may not be ideal. In this study, the distribution of the templated glenoid sizes was much wider than that of the implanted glenoid sizes. During templating, each glenoid component can be definitively visualized and assessed for possible peg penetration and overhang. Visualization allows surgeons to base glenoid size selection solely on glenoid morphology, as opposed to factors such as patient sex and height. In addition, interobserver and intraobserver agreement values for the 40-mm glenoid component were considerably higher than those for components of other sizes, indicating that the 40-mm component was consistently and reproducibly selected for the same patients. Hence, templating may particularly help prevent peg penetration and component overhang for patients with a smaller diameter glenoid.

More research on 3-D templating is warranted given the results of this study and other studies.^{12,17,31} Scalise and colleagues³¹ found that, in TSA planning, surgeons' use of 2-D (vs 3-D) imaging led them to overestimate glenoid component sizes ($P = .006$). In our study, the glenoid size selected during 3-D templating was, in many cases, smaller than the size selected during surgery. In order to avoid peg penetration and glenoid overhang, anecdotal guidelines commonly used in glenoid size selection, likely was the driving force in selecting smaller glenoid components during templating. Although anterior, superior, and inferior glenoid overhang typically can be assessed during surgery, posterior overhang is more difficult to evaluate. Three-dimensional modeling allows surgeons to determine optimal glenoid component size and position. In addition, intraoperative evaluation of glenoid component peg penetration is challenging, and peg penetration becomes evident only after it has occurred. During templating, however, surgeons were able to easily assess for peg penetration, and smaller glenoid components were selected.

A limitation of this study is that intraoperative glenoid version correction or peg containment was not quantified. More research is needed on the relationship between glenoid size selection and component overhang and peg penetration. Another limitation was use of only 1 TSA system (with 3 glenoid sizes, all with inline pegs); reliability of 3-D templating was not evaluated across different component designs. Last, given the absence of guidelines for glenoid component size selection, there was surgeon bias in preoperative templating and in intraoperative selection of glenoid size. Surgeons had differing opinions on the importance of

maximizing the contact area of the component and correcting glenoid deformity and version.

Our study results showed that preoperative 3-D templating that allows for superior-inferior, anterior-posterior, and rotational translation was consistent and reproducible in determining glenoid component size, and use of this templating may reduce the risks of implant overhang, peg penetration, and decreased stability ratio. These results highlight the possibility that glenoid component sizes selected during surgery may not be ideal. More research is needed to determine if intraoperative glenoid size selection leads to adequate version correction and peg containment. The present study supports use of 3-D templating in primary TSA planning.

Dr. Saifi and Dr. Noticewala are Orthopaedic Surgery Residents, Center for Shoulder, Elbow, and Sports Medicine, Department of Orthopaedic Surgery, Columbia University Medical Center, New York, New York. Dr. Greiwe is an Orthopaedic Surgeon, Commonwealth Orthopaedic Centers, Edgewood, Kentucky. Dr. Lester is an Orthopaedic Surgery Resident, Department of Orthopaedic Surgery, University of Illinois, Chicago, Illinois. Mr. Gardner is Associate Director, Biomechanics Research Laboratory, Center for Orthopaedic Research, Department of Orthopaedic Surgery, Columbia University Medical Center, New York, New York. Dr. Cadet is an Orthopaedic Surgeon, Raleigh Orthopaedic Clinic, Raleigh, North Carolina. Dr. Levine is Chairman of Orthopaedic Surgery, Head Team Physician for Columbia University Athletics, Chief of Shoulder Service, and Co-Director of Center for Shoulder, Elbow, and Sports Medicine, Department of Orthopaedic Surgery, Columbia University Medical Center, New York, New York. Dr. Bigliani is Retired Chairman of Orthopaedic Surgery, Center for Shoulder, Elbow, and Sports Medicine, Department of Orthopaedic Surgery, Columbia University Medical Center, New York, New York. Dr. Ahmad is Professor of Orthopaedic Surgery, Vice Chair of Research, Head Team Physician of New York Yankees, and Head Team Physician of New York City Football Club, Center for Shoulder, Elbow, and Sports Medicine, Department of Orthopaedic Surgery, Columbia University Medical Center, New York, New York.

Address correspondence to: Manish S. Noticewala, MD, Center for Shoulder, Elbow, and Sports Medicine, Department of Orthopaedic Surgery, Columbia University Medical Center, New York, NY XX (tel, 212-305-4565; email, manish.s.noticewala@gmail.com).

Am J Orthop. 2017;46(4):E2280-E286. Copyright Frontline Medical Communications Inc. 2017. All rights reserved.

References

1. Neer CS 2nd. Replacement arthroplasty for glenohumeral osteoarthritis. *J Bone Joint Surg Am.* 1974;56(1):1-13.
2. Neer CS 2nd, Watson KC, Stanton FJ. Recent experience in total shoulder replacement. *J Bone Joint Surg Am.* 1982;64(3):319-337.
3. Day JS, Lau E, Ong KL, Williams GR, Ramsey ML, Kurtz SM. Prevalence and projections of total shoulder and elbow arthroplasty in the United States to 2015. *J Shoulder Elbow Surg.* 2010;19(8):1115-1120.
4. Torchia ME, Cofield RH, Settergren CR. Total shoulder arthroplasty with the Neer prosthesis: long-term results. *J Shoulder Elbow Surg.* 1997;6(6):495-505.
5. Barrett WP, Franklin JL, Jackins SE, Wyss CR, Matsen FA 3rd. Total shoulder arthroplasty. *J Bone Joint Surg Am.* 1987;69(6):865-872.
6. Bohsali KI, Wirth MA, Rockwood CA Jr. Complications of total shoulder arthroplasty. *J Bone Joint Surg Am.* 2006;88(10):2279-2292.
7. Matsen FA 3rd, Bicknell RT, Lippitt SB. Shoulder arthroplasty: the socket perspective. *J Shoulder Elbow Surg.* 2007;16(5 suppl):S241-S247.
8. Matsen FA 3rd, Clinton J, Lynch J, Bertelsen A, Richardson ML. Glenoid component failure in total shoulder arthroplasty. *J Bone Joint Surg Am.* 2008;90(4):885-896.
9. Pearl ML, Romeo AA, Wirth MA, Yamaguchi K, Nicholson GP, Creighton RA. Decision making in contemporary shoulder arthroplasty. *Instr Course Lect.* 2005;54:69-85.
10. Wirth MA, Rockwood CA Jr. Complications of total shoulder-replacement arthroplasty. *J Bone Joint Surg Am.* 1996;78(4):603-616.
11. Sanchez-Sotelo J, Sperling JW, Rowland CM, Cofield RH. Instability after shoulder arthroplasty: results of surgical treatment. *J Bone Joint Surg Am.* 2003;85(4):622-631.
12. Tammachote N, Sperling JW, Berglund LJ, Steinmann SP, Cofield RH, An KN. The effect of glenoid component size on the stability of total shoulder arthroplasty. *J Shoulder Elbow Surg.* 2007;16(3 suppl):S102-S106.
13. Iannotti JP, Greeson C, Downing D, Sabesan V, Bryan JA. Effect of glenoid deformity on glenoid component placement in primary shoulder arthroplasty. *J Shoulder Elbow Surg.* 2012;21(1):48-55.
14. Briem D, Ruecker AH, Neumann J, et al. 3D fluoroscopic navigated reaming of the glenoid for total shoulder arthroplasty (TSA). *Comput Aided Surg.* 2011;16(2):93-99.
15. Budge MD, Lewis GS, Schaefer E, Coquia S, Flemming DJ, Armstrong AD. Comparison of standard two-dimensional and three-dimensional corrected glenoid version measurements. *J Shoulder Elbow Surg.* 2011;20(4):577-583.
16. Chuang TY, Adams CR, Burkhart SS. Use of preoperative three-dimensional computed tomography to quantify glenoid bone loss in shoulder instability. *Arthroscopy.* 2008;24(4):376-382.
17. Nowak DD, Bahu MJ, Gardner TR, et al. Simulation of surgical glenoid resurfacing using three-dimensional computed tomography of the arthritic glenohumeral joint: the amount of glenoid retroversion that can be corrected. *J Shoulder Elbow Surg.* 2009;18(5):680-688.
18. Scalise JJ, Bryan J, Polster J, Brems JJ, Iannotti JP. Quantitative analysis of glenoid bone loss in osteoarthritis using three-dimensional computed tomography scans. *J Shoulder Elbow Surg.* 2008;17(2):328-335.
19. Scalise JJ, Codsí MJ, Bryan J, Iannotti JP. The three-dimensional glenoid vault model can estimate normal glenoid version in osteoarthritis. *J Shoulder Elbow Surg.* 2008;17(3):487-491.
20. Bryce CD, Pennypacker JL, Kulkarni N, et al. Validation of three-dimensional models of in situ scapulae. *J Shoulder Elbow Surg.* 2008;17(5):825-832.
21. Landis JR, Koch GG. The measurement of observer agreement for categorical data. *Biometrics.* 1977;33(1):159-174.
22. Cummings RJ, Loveless EA, Campbell J, Samelson S, Mazur JM. Interobserver reliability and intraobserver reproducibility of the system of King et al. for the classification of adolescent idiopathic scoliosis. *J Bone Joint Surg Am.* 1998;80(8):1107-1111.

23. Humphrey CA, Dirschl DR, Ellis TJ. Interobserver reliability of a CT-based fracture classification system. *J Orthop Trauma*. 2005;19(9):616-622.
24. Illarramendi A, González Della Valle A, Segal E, De Carli P, Maignon G, Gallucci G. Evaluation of simplified Frykman and AO classifications of fractures of the distal radius. Assessment of interobserver and intraobserver agreement. *Int Orthop*. 1998;22(2):111-115.
25. Lenke LG, Betz RR, Bridwell KH, et al. Intraobserver and interobserver reliability of the classification of thoracic adolescent idiopathic scoliosis. *J Bone Joint Surg Am*. 1998;80(8):1097-1106.
26. Ploegmakers JJ, Mader K, Pennig D, Verheyen CC. Four distal radial fracture classification systems tested amongst a large panel of Dutch trauma surgeons. *Injury*. 2007;38(11):1268-1272.
27. Sidor ML, Zuckerman JD, Lyon T, Koval K, Cuomo F, Schoenberg N. The Neer classification system for proximal humeral fractures. An assessment of interobserver reliability and intraobserver reproducibility. *J Bone Joint Surg Am*. 1993;75(12):1745-1750.
28. Siebenrock KA, Gerber C. The reproducibility of classification of fractures of the proximal end of the humerus. *J Bone Joint Surg Am*. 1993;75(12):1751-1755.
29. Thomsen NO, Overgaard S, Olsen LH, Hansen H, Nielsen ST. Observer variation in the radiographic classification of ankle fractures. *J Bone Joint Surg Br*. 1991;73(4):676-678.
30. Ward WT, Vogt M, Grudziak JS, Tümer Y, Cook PC, Fitch RD. Severin classification system for evaluation of the results of operative treatment of congenital dislocation of the hip. A study of intraobserver and interobserver reliability. *J Bone Joint Surg Am*. 1997;79(5):656-663.
31. Scalise JJ, Codsì MJ, Bryan J, Brems JJ, Iannotti JP. The influence of three-dimensional computed tomography images of the shoulder in preoperative planning for total shoulder arthroplasty. *J Bone Joint Surg Am*. 2008;90(11):2438-2445.

This paper will be judged for the Resident Writer's Award.