

Thyroid Cartilage Fracture in Context of Noncompetitive “Horseplay” Wrestling

Alan Lucerna, DO; James Espinosa, MD; Risha Hertz, APNC

A 38-year-old man presented with a complaint of throat pain after wrestling at home, in horseplay, with his son.

An isolated thyroid cartilage fracture is very rare.¹⁻⁵ More interestingly, an isolated thyroid cartilage fracture from a wrestling injury, especially in a non-sports competition context, such as horseplay, has not been previously reported in the literature. Sports-related injuries to the larynx and related structures are uncommon.^{6,7}

Case

A 38-year-old man presented with a complaint of throat pain after wrestling at home, in horseplay, with his 15-year-old son. He reported that when his son placed a choke hold on him, he felt a “crack” in the area of his neck, and soon afterwards felt throat pain with swallowing, along with discomfort with breathing. He also felt a sensation of “fluid building up in his throat.” There were no changes noted with his voice and the patient was speaking in full sentences. There was no wheezing or stridor. He de-

nied shortness of breath or any other complaints. He denied pain over the posterior elements of his cervical spine. At the time of the incident, there was no loss of consciousness. Palpation of the neck and chest did not elicit any crepitation to suggest subcutaneous emphysema. The trachea was midline. There was no pain overlying the carotids bilaterally, and the patient had no bruits. The neck examination did not show any surface abnormalities to suggest trauma, such as ecchymosis or swelling. He did have slight tenderness to palpation over the thyroid cartilage.

The patient was sent for a computed tomography (CT) scan of the soft-tissue neck with intravenous (IV) contrast, and a CT scan of the cervical spine. The results showed no cervical spine fracture. However, there was a minimally displaced fracture of the left thyroid cartilage, with soft-tissue swelling that was noted, along with minimal narrowing of the subglottic

Dr Lucerna is the program director, department of combined emergency medicine/internal medicine, Rowan University SOM/Kennedy University Hospital, Stratford, New Jersey. **Dr Espinosa** is a clinical assistant professor, department of emergency medicine, Rowan University SOM/Kennedy University Hospital, Stratford, New Jersey. **Ms Hertz** is an advance nurse practitioner, department of family medicine, University of Pennsylvania/Penn Medicine, Gibbsboro, New Jersey.

Authors' Disclosure Statement: The authors report no actual or potential conflict of interest in relation to this article.

DOI: 10.12788/emed.2017.0056

trachea. There were no abnormal enhancements or fluid collections. No evidence of vocal cord abnormality or asymmetry was seen, and there was no evidence of airway compromise (**Figure**). A consult with an otolaryngologist was obtained, and transfer to the tertiary care center was recommended. The patient was successfully transferred and observed for 24 hours; he was discharged home in good condition the next day.

Discussion

Our patient sustained an isolated thyroid cartilage fracture. A thyroid cartilage fracture is a type of laryngeal fracture. Using an anatomic system in which such injuries are classified by location (supraglottic, glottis, or infraglottic), a thyroid cartilage fracture is classified as a supraglottic laryngeal injury.^{1,2} In our case, the fracture was due to a blunt force mechanism. Most blunt force laryngeal fractures are associated with multiple trauma.⁸ An isolated thyroid cartilage fracture is very rare.¹⁻⁵ More interestingly, an isolated thyroid cartilage fracture from a wrestling injury, especially in a non-sports competition context, such as horseplay, has not been previously reported in the literature.

Sports-related injuries to the larynx and related structures are uncommon.^{6,7} When reported, significant force is usually involved. For example, Tasca et al⁶ reported a thyroid cartilage fracture from direct blunt trauma (rugby, opponent stamped on patient's throat) in which the patient presented with pain with swallowing and a lowering of the pitch of his voice. Rejali et al⁹ reported the case of a midair collision in a soccer match, resulting in an obvious mandibular fracture, but with an arytenoid cartilage fracture that was not initially identified. A football struck a 17-year-old boy with a resulting fracture of the superior cornu of the larynx and a puncture of the laryngeal mucosal wall in a case reported by Saab and Birkinshaw.¹⁰ The patient presented with neck pain and dysphagia, as

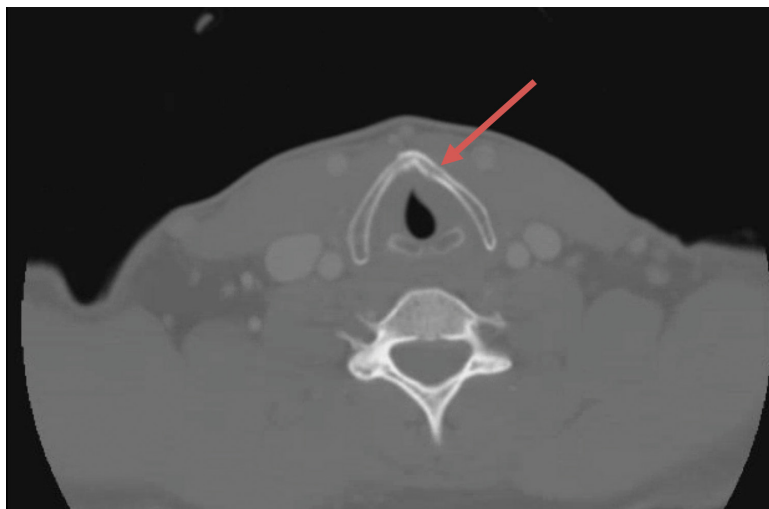


Figure. Computed tomography image of the soft-tissue neck with contrast showing a minimally displaced fracture of the left thyroid cartilage with soft-tissue swelling with minimal narrowing of the subglottic trachea. No abnormal enhancement or abnormal fluid collection, and no evidence of vocal cord abnormality or asymmetry.

well as subcutaneous air.¹⁰ A 21-year-old collegiate basketball player was struck in the neck by a teammate's head while jumping for a rebound. He sustained a fracture of the thyroid cartilage and a fracture of the anterior cricoid ring.³ Patients with such injuries “may appear deceptively normal when seeking medical attention.”⁸ Kragha² refers to such injuries as “rare but potentially deadly.”

Symptoms can include neck pain, voice changes, pain with swallowing, and shortness of breath. Signs can include tenderness, ecchymosis, and even subcutaneous emphysema. There may be loss of prominence of the thyroid cartilage.³ Tracheal deviation and stridor can occur.^{10,11} Computed tomography scan and laryngoscopy can be helpful in the diagnostic process; 3-dimensional (3-D) reconstructions may be needed.

Various classification systems have been proposed with related treatment strategies. Percevik et al¹¹ summarized a five-part clinical classification. Group 1 (hematoma, no fracture) and Group 2 (non-displaced fracture) may be treated conservatively. Group 3 (stable, displaced fracture), Group 4 (unstable, displaced fracture), and Group

5 (laryngotracheal disinsertion) are more likely to be treated with surgery.¹¹ Surgical techniques vary and have been refined over time.¹²

In this case, the patient sustained a thyroid cartilage fracture without the energy and force involved in a motor vehicle collision and without significant sports-related force. It is possible that this injury may have involved neck hyperflexion, rather than direct compressive force. Lin et al,¹ described a case of neck hyperflexion in an unrestrained driver, with a resulting isolated thyroid cartilage fracture without direct impact to the neck. Walsh and Trotter⁵ presented a case of a motorcyclist with a blow to the back of the head, with resulting neck hyperflexion, which resulted in a fracture of the thyroid cartilage. Beato-Martínez et al,¹³ reported a case of thyroid cartilage fracture following a sneezing episode. The patient presented with odynophagia, dysphonia and neck pain.¹³ In our review of the literature, we found that only one other similar case has been reported. In that case, a patient experienced a feeling of a neck click, followed by neck pain and hoarseness. He sustained a fracture of the thyroid cartilage.¹⁴

In reviewing the hyperflexion mechanism, Lin et al¹ noted that isolated thyroid cartilage fractures are rare and that “most of these are caused by direct injury to the neck, except for two patients reported in the literature who sustained isolated thyroid cartilage fractures after sneezing.” Lin et al¹ proposed an interesting hypothesis—that “the mechanism causing thyroid cartilage fracture during impaction may be the same with sneezing.” Sneezing can be associated with sudden and forceful flexion of the neck.

It is certainly possible that this hyperflexion mechanism was involved in our case, given there was no history of significant blunt force to the neck, as in the sports-related injuries discussed. Wrestling holds can produce hyperflexion. The patient described a feeling of a “crack”, which is

similar to the clicking sound described in one of the sneezing-related cases. An isolated thyroid cartilage fracture is rare in the absence of major trauma. However, as noted by Rejali et al,⁹ this can create a potential management pitfall. “In the context of non-contact sports, the attendant doctor may not realize the significance of apparently minor head and neck trauma.”⁹

There are no series data to provide us with an exact incidence of airway compromise. However, seemingly minor insults to the anterior neck can cause posterior compression of the larynx and can result in airway compromise.⁹⁻¹¹

The CT scan is described as an important imaging modality to rule out cervical spine fracture. Although there was no significant blunt force, the cervical spine was exposed to hyperflexion forces. Another important potential consequence is long-term injury to the vocal cords, with subsequent speech difficulties.¹¹ Computed tomography can visualize the thyroid fracture, but many authors point out that visualization of the vocal cords, with nasopharyngeal laryngoscopy or other modality, is an important adjunct to the CT scan.⁹⁻¹¹

Otolaryngologist consultation should be strongly considered. This patient was transferred to a tertiary care center with expertise in thyroid fractures, and planned nasopharyngeal laryngoscopy to be performed at the receiving institution.

Conclusion

Our patient sustained an isolated thyroid cartilage fracture. Most blunt force laryngeal fractures are associated with multiple trauma. An isolated thyroid cartilage fracture is very rare. An isolated thyroid cartilage fracture from a wrestling injury, especially in a non-sports competition context, such as horseplay, has not been previously reported in the literature. Symptoms can include neck pain, voice changes, pain with swallowing, and shortness of breath. Signs can include tenderness, ecchymosis, or even subcutaneous emphysema.

There may be loss of the prominence of the thyroid cartilage, tracheal deviation, and stridor. Computed tomography scan imaging with 3-D reconstructions and laryngoscopy can be helpful in the diagnostic process. In our case, the patient sustained a thyroid cartilage fracture without the energy and force involved in a motor vehicle

collision and without significant sports-related force. It is possible this injury may have involved neck hyperflexion, rather than direct compressive forces, similar to that described by Lin et al.¹ Certainly, there was no history of significant blunt force to the neck on the level of the sports-related injuries discussed.

References

1. Lin HL, Kuo LC, Chen CW, Cheng YC, Lee WC. Neck hyperflexion causing isolated thyroid cartilage fracture--a case report. *Am J Emerg Med*. 2008;26(9):1064.e1-e3. doi:10.1016/j.ajem.2008.02.030
2. Kragha KO. Acute traumatic injury of the larynx. *Case Reports in Otolaryngology*. Volume 2015. Article ID393978. <http://dx.doi.org/10.1155/2015/393978>.
3. Kim JD, Shuler FD, Mo B, Gibbs SR, Belmaggio T, Giangarra CE. Traumatic laryngeal fracture in a collegiate basketball player. *Sports Health*. 2013;5(3):273-275.
4. Knopke S, Todt I, Ernst A, Seidl RO. Pseudarthroses of the cornu of the thyroid cartilage. *Otolaryngol Head Neck Surg*. 2010;143(2):186-189. doi:10.1016/j.otohns.2010.04.011.
5. Walsh PV, Trotter GA. Fracture of the thyroid cartilage associated with full face integral crash helmet. *Injury*. 1979;11(1):47-48.
6. Tasca RA, Sherman IW, Wood GD. Thyroid cartilage fracture: treatment with biodegradable plates. *Br J Oral Maxillofac Surg*. 2008;46(2):159-160.
7. Mitrović SM. Blunt external laryngeal trauma. Two case reports. *Med Pregl*. 2007;60(9-10):489-492.
8. O'Keeffe LJ, Maw AR. The dangers of minor blunt laryngeal trauma. *J Laryngol Otol*. 1992;106(4):372-373.
9. Rejali SD, Bennett JD, Üpile T, Rothera MP. Diagnostic pitfalls in sports related laryngeal injury. *Br J Sports Med*. 1998;32(2):180-181.
10. Saab M, Birkinshaw R. Blunt laryngeal trauma: an unusual case. *Int J Clin Pract*. 1997;51(8):527.
11. Pekcevik Y, Ibrahim C, Ülker C. Cricoid and thyroid cartilage fracture, cricothyroid joint dislocation, pseudofracture appearance of the hyoid bone: CT, MRI and laryngoscopic findings. *JAEM*. 2013;12:170-173.
12. Bent JP 3rd, Porubsky ES. The management of blunt fractures of the thyroid cartilage. *Otolaryngol Head Neck Surg*. 1994;110(2):195-202. doi:10.1177/019459989411000209.
13. Beato Martínez A, Moreno Juara A, López Moya JJ. Fracture of thyroid cartilage after a sneezing episode. *Acta Otorrinolaringol Esp*. 2007;58(2):73-74.
14. Quinlan PT. Fracture of thyroid cartilage during a sneezing attack. *Br Med J*. 1950;1(4661):1052.