

Flexible Bronchoscopic Removal of 3 Foreign Objects

Javier Ramos-Rossy, MD; Onix Cantres, MD; Alfonso Torres, MD; Jesús Casal, MD; Yomayra Otero, MD; Ginger Arzon-Nieves; and William Rodríguez-Cintrón, MD

Consider flexible bronchoscopy as an option to retrieve aspirated foreign bodies in the airway.

Author affiliations are listed at the end of this article.

Correspondence:
Dr. Rodríguez-Cintrón
(william@prmail.net)

Airway foreign-body aspiration may cause no symptoms, although it can produce acute and life-threatening central airway obstruction.¹ In the US, at least 2,700 people, including more than 300 children, die of foreign-body aspiration each year.² Most foreign-body aspirations occur in children and elderly patients.³ In adults, dementia, drug intoxication, strokes, seizures, and neurologic disorders may predispose patients to aspiration.³ Some of the consequences of an aspirated object are complete or partial airway obstruction, respiratory distress and failure, pneumothorax, and hemorrhage.² In addition, inadvertent aspiration of foreign objects in asymptomatic patients may not be evident for months, resulting in late complications as postobstructive pneumonia, bronchiectasis, or lung abscess.²

We present a case of a patient with documented schizophrenia with nonadherence to his antipsychotic medications who aspirated

different objects. Flexible bronchoscopy was performed since rigid bronchoscopy is not available at our institution. Several bronchoscopy tools were required to successfully remove the objects and avoid further invasive interventions, such as cardiothoracic surgery.

CASE PRESENTATION

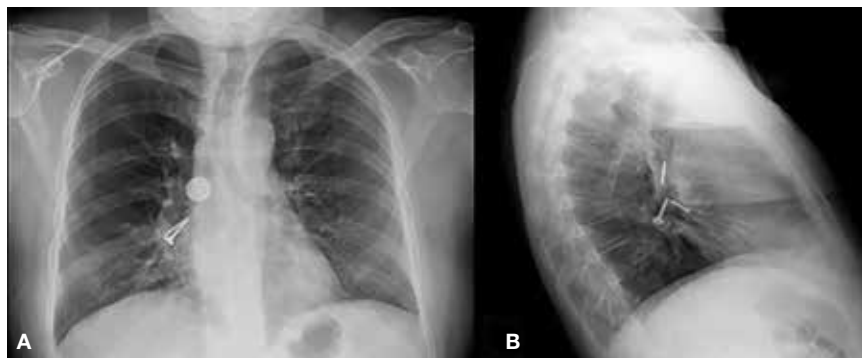
A 55-year-old man with schizophrenia on antipsychotics developed cough, shortness of breath, and dysphagia of 1-month of evolution. Because his symptoms worsened, his mother brought him to the emergency department. Peripheral oxygen saturation was 97% at room air. Lung auscultation was remarkable for bilateral scattered rhonchi and wheezes.

Laboratory results showed leukocytosis with neutrophilia and hypotonic hypovolemic hyponatremia. In view of shortness of breath, cough, wheezes, and leukocytosis, a chest radiograph was performed, showing a rounded metallic density and 2 metallic objects

(appearing to be a screw and a nail) at the right main stem bronchus for which the pneumology service was consulted (Figures 1A and 1B).

The patient stated that he did not remember swallowing any objects, although his mother confirmed that he was not adherent with his antipsychotic medications, which could have predisposed him to aspiration secondary to possible psychotic episodes. A chest computer tomography (CT) scan without contrast confirmed the presence of the materials (Figures 2A and 2B) and a

FIGURES 1A and 1B Chest Imaging, Posteroanterior and Lateral Views



(A) Rounded coinlike metallic density at proximal right main stem bronchus; (B) 2 additional metallic objects distally at the right main stem bronchus.

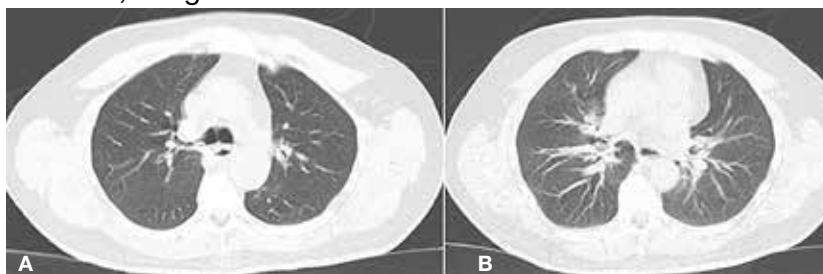
possible prevertebral abscess, which could explain the patient's dysphagia.

Piperacillin/tazobactam 4.5 g every 8 hours was started to cover anaerobic bacterial organisms causing abscess, and IV fluids were given for hypovolemia. Flexible bronchoscopy (rigid bronchoscopy is superior although not available at our institution) was planned to be performed in the operating room (OR) because we predicted a difficult and prolonged retrieval in view of multiple and different-sized objects.

A bronchoscopy was performed, showing a disk-shaped metallic foreign body at the right main stem bronchus. After multiple attempts using the tripod retrieval tool, a coin was removed (Figures 3A and 3B). Using a snare retrieving tool, the surgeons removed a screw from the right main stem bronchus as well (Figures 4A and 4B). A third foreign object with the appearance of a nail (Figure 5) was visualized distal in the right main stem bronchus. Because of the difficult position where the object was lodged, initial attempts to retrieve the object were unsuccessful. The airway was secured with endotracheal intubation, and the patient was sedated. Then multiple attempts at retrieval of this foreign object were performed with the tripod and snare tools. The object was finally advanced toward the endotracheal tube (ETT), yet it was larger than the caliber of the ETT. Therefore, the cuff was deflated, and the ETT was removed at the same time the bronchoscope was retrieved while holding the last foreign body.

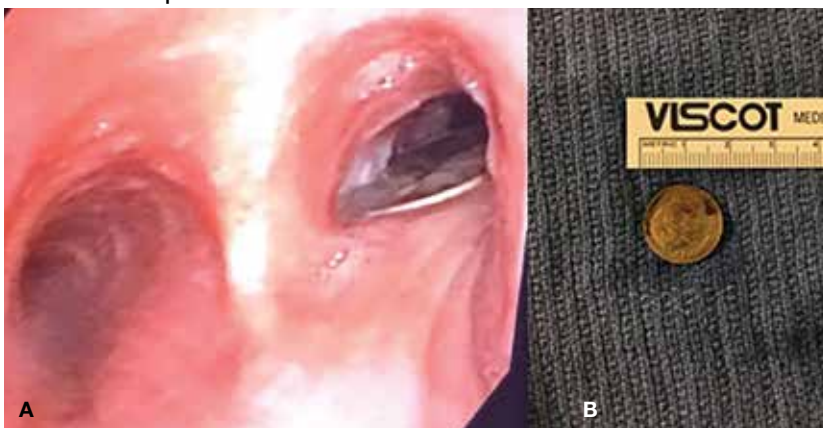The patient was reintubated without any complications. A postprocedure chest radiograph showed the absence of foreign bodies and no pneumothorax. The patient completed IV antibiotic with piperacillin/tazobactam and supportive therapy with clinical improvement and successful extubation within 2 days. Cardiothoracic surgery was not required. Psychiatry service recommended to continue the same antipsychotic medications, administered only by his mother to assure adherence and to avoid similar future events. The patient was discharged home without any immediate complications

FIGURES 2A and 2B Chest Computed Tomography Without Contrast, Lung Window View



(A) Rounded coinlike metallic density at proximal right main stem bronchus (B) with associated atelectasis.

FIGURES 3A and 3B Disc-Shaped Foreign Body, Bronchoscopic View and After Removal View



Disk-shaped metallic foreign body at the right main stem bronchus (A) that was remarkable for a coin after removal with tripod retrieval tool (B).

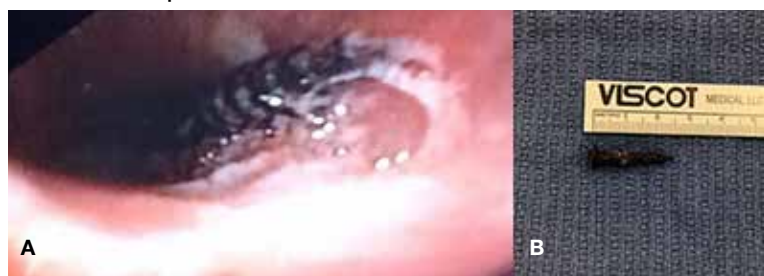despite having had a coin, nail, and screw aspiration (Figure 6).

DISCUSSION

More than 50% of foreign bodies lodge at the right main stem bronchus due to the trachea's anatomical position.^{2,4} In adults, foreign-body aspiration may present with nonspecific symptoms, such as cough and dyspnea.⁴ Other symptoms might include wheezes, chest discomfort, and sputum production. A chest radiograph is helpful as part of the initial diagnostic workup. A chest CT scan without contrast should be performed to confirm the diagnosis and to plan possible foreign-body retrieval.

Bronchoscopy is the gold standard for diagnosis and management of foreign-body aspiration.¹ Rigid bronchoscopy is superior to flexible bronchoscopy in removal of large

FIGURES 4A and 4B Screw-like Foreign Body, Bronchoscopic View and After Removal View



Screw was lodged (A) and removed (B) from the right main stem bronchus.

airway foreign bodies.¹ The rigid bronchoscopy provides the ability to function as an endotracheal tube, thus allowing control of the airway and a conduit through which foreign bodies can be removed.¹ Nonetheless, sometimes retrieval of foreign bodies deeper into the subsegmental bronchi cannot be achieved.¹ Moreover, the required equipment or knowledgeable staff is not always available.¹ Therefore, flexible bronchoscopy is an option to retrieve airway foreign bodies especially those located distal in the airway and for those medical centers without rigid bronchoscopy as is the case in our institution.

In our case, flexible bronchoscopy was performed in the OR because we predicted a difficult and prolonged retrieval in view of multiple and different-sized objects. Anesthesia Service assistance was requested anticipating need for patient sedation and intubation. We used the tripod and snare retrieval tools to remove 3 foreign objects located at the right main stem bronchus. Even though multiple attempts were made and endotracheal intubation was required, a successful retrieval with flexible bronchoscopy was performed. Moreover, cardiothoracic surgery was not required avoiding more invasive interventions with subsequent morbidity and mortality.

CONCLUSION

Flexible bronchoscopy is an important tool within the arsenal of the Pulmonology Service. The management of the underlying etiology also should be performed. In our case, the Psychiatry Service recommended that the patient's medications should be administered by his mother to avoid similar events in the future. Flexible bronchoscopy

FIGURE 5 Foreign Bodies Removed



A coin, nail, and screw were successfully removed from the right main stem bronchus.

can be a valuable option for foreign objects removal, especially those distally located in the lung segments as well as in those medical centers where rigid bronchoscopy is not available.

Author affiliations

Dr. Ramos-Rossy and **Dr. Otero** are Fellows; **Dr. Cantres** and **Dr. Torres** are Attending Physicians; **Ms. Arzon-Nieves** is a Research Coordinator; and **Dr. Rodríguez-Cintrón** is Attending Physician, Section Chief, and Program Director, all in the Pulmonary and Critical Care Medicine Program at the VA Caribbean Healthcare System in San Juan, Puerto Rico.

Author disclosures

The authors report no actual or potential conflicts of interest with regard to this article.

Disclaimer

The opinions expressed herein are those of the authors and do not necessarily reflect those of *Federal Practitioner*, Frontline Medical Communications Inc., the US Government, or any of its agencies. This article may discuss unlabeled or investigational use of certain drugs. Please review the complete prescribing information for specific drugs or drug combinations—including indications, contraindications, warnings, and adverse effects—before administering pharmacologic therapy to patients.

References

1. Mehta D, Mehta C, Bansal S, Singla S, Tangri N. Flexible bronchoscopic removal of a three piece foreign body from a child's bronchus. *Australas Med J*. 2012;5(4):227-230.
2. Mercado JA, Rodríguez W. Occult aspiration of a chicken wishbone as a cause of hemoptysis. *P R Health Sci J*. 1999;18(1):71-73.
3. Robles-Arias CM, Campos-Santiago Z, Vega MT, Rosa-Cruz F, Rodríguez-Cintrón W. Aspiration of a dental tool during a crown placement procedure. *Fed Pract*. 2014;31(6):12-14.
4. Blanco-Ramos M, Botana-Rial M, García-Fontán E, Fernández-Villar A, Gallas-Torreira M. Update in the extraction of airway foreign bodies in adults. *J Thorac Dis*. 2016;8(11):3452-3456.