

> **THE PATIENT**  
32-year-old Chinese woman

> **SIGNS & SYMPTOMS**

- Severe headache
- Neck pain
- Intermittent cough

Claudia Lyon, DO,  
MBA, FAAFM; Swapna  
Sayeneni, MD; Jeanne  
Carey, MD  
NYU Lutheran Medical  
Center, Brooklyn, NY

✉ [claudia.lyon@nyumc.org](mailto:claudia.lyon@nyumc.org)

*The authors reported no  
potential conflict of interest  
relevant to this article.*

## > THE CASE

A 32-year-old Chinese woman sought care from our family medicine clinic because she had a headache, neck pain, and an intermittent cough that had produced white sputum for 7 days. She described the headache as severe and pressure-like, and said that it had progressively worsened over the previous 3 weeks, coinciding with her first trip outside of China to the United States. The patient indicated that she also had occasional vomiting, dizziness, a low-grade fever, chills, night sweats, and increasing fatigue.

Prior to this visit, the patient had gone to the emergency department (ED) twice in one week, but was told that she had a migraine headache and a viral syndrome and was sent home. She was also told to make a follow-up appointment at our family medicine outpatient clinic.

Besides the symptoms that brought her to our clinic, the only other notable element of the patient's history was a "neck mass" resection in China 8 years earlier. (The diagnosis of the neck mass was unknown.)

Concerned about her presenting signs and symptoms, we sent the patient to the ED, where she was admitted for further evaluation and treatment of possible meningitis. In the ED, she had a temperature of 101.5° F; her other vital signs were normal. A physical exam revealed mild neck stiffness.

## THE DIAGNOSIS

A chest computed tomography (CT) scan demonstrated extensive confluent nodular infiltrates in the lung apices bilaterally with the largest confluent nodule measuring 6 cm (FIGURE 1). A chest x-ray demonstrated extensive bilateral pulmonary interstitial infiltrates that were most pronounced in the upper lung fields (FIGURE 2).

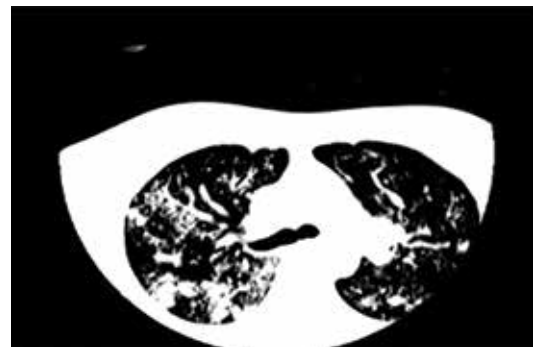
Lumbar puncture results revealed lymphocytic pleocytosis with elevated protein and low glucose levels (TABLE). Based on these results, the family medicine team suspected that our patient had tuberculous meningitis (TBM).

The team consulted with Infectious Diseases for management of TBM, and they placed our patient in a negative pressure room on airborne isolation. In addition, she was started on rifampin 450 mg/d, pyrazinamide 1000 mg/d, ethambutol 800 mg/d, and isoniazid (INH) 800 mg/d, as well as pyridoxine and intravenous dexamethasone.

Sputum samples were obtained on

FIGURE 1

Chest CT showed nodular infiltrates in the lung apices



IMAGES COURTESY OF: NYU LUTHERAN

3 consecutive days for acid-fast bacilli (AFB) smears and cultures. Although the smears were negative for *Mycobacterium tuberculosis*, nucleic acid amplification by polymerase chain reaction (PCR) testing detected *M tuberculosis* in the sputum. And the cultures grew *M tuberculosis* complex, which was pan-susceptible to all 4 first-line anti-tuberculosis (TB) medications.

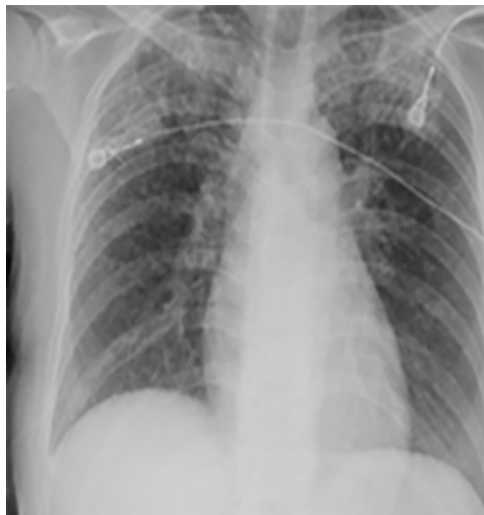## DISCUSSION

TBM accounts for approximately 1% of all cases of TB and 5% of extrapulmonary diseases in immunocompetent individuals.<sup>1</sup> In 2015, there were approximately 10.4 million cases of TB worldwide, and 6 countries accounted for 60% of the global total: India, Indonesia, China, Nigeria, Pakistan, and South Africa.<sup>2</sup> TBM is typically a subacute disease with symptoms that can persist for weeks before diagnosis.<sup>3</sup> An early diagnosis is critical, as the mortality rate remains relatively high (as high as nearly 70% in underdeveloped and developed countries) despite effective treatment regimens.<sup>3</sup> (For updated recommendations on TB screening, see this month's Practice Alert on page 310.)

Most health care facilities use AFB smears to determine when patients with suspected TB should be isolated. However, AFB smears are positive in only 60% of TB cases.<sup>4</sup> One study indicated that nucleic acid amplification by PCR can improve sensitivity

FIGURE 2

## Chest x-ray revealed bilateral pulmonary interstitial infiltrates



from 60% to 87% and specificity from 98% to 100%.<sup>5</sup>

The presentation of TBM varies by phase of disease:

- **The prodromal phase** typically lasts for 2 to 3 weeks. It is characterized by an insidious onset of malaise, headache, low-grade fever, irritability, and personality changes.
- **The meningitis phase** is characterized by pronounced neurologic features such as meningismus, protracted



Once you suspect tuberculous meningitis, isolate the patient, obtain appropriate cultures and smears, and start anti-tuberculosis drugs and adjunctive corticosteroids immediately.

TABLE

## A look at our patient's lumbar puncture results

Our patient's elevated white blood cell count and total protein level, as well as her low glucose level, were consistent with a diagnosis of tuberculous meningitis.

	Result	Reference range
Appearance	Clear	—
Color	Colorless	—
Red blood cells	8	0
White blood cells	147	0-5
Lymphocytes	86%	40%-80%
Monocytes	9%	15%-45%
Glucose	21 mg/dL	40-70 mg/dL
Total protein	137 mg/dL	15-40 mg/dL

headache, confusion, myelopathy, and sensory deficits, as well as vomiting, lethargy, and urinary retention.

- **During the paralytic phase**, patients experience profound confusion, followed by stupor, coma, seizures, progressive paraplegia, and often, hemiparesis.<sup>1,3,6</sup>

## Treatment should be given for a total of 9 to 12 months

Initiate treatment for TB based on a strong clinical suspicion for the disease. Treatment of TBM consists of an intensive phase with 4 anti-TB drugs for 2 months (typically INH 800 mg/d, rifampin 450 mg/d, pyrazinamide 1000 mg/d, and ethambutol 800 mg/d) and a continuation phase with 2 drugs (INH and rifampin) for 7 to 10 additional months, resulting in a total treatment duration of 9 to 12 months.

■ **Our patient** was discharged from the hospital after 2 weeks on an anti-TB medication regimen of INH, rifampin, and pyrazinamide, along with pyridoxine and a tapering dose of dexamethasone. After the initial 2 months of intensive phase therapy,

she was switched to INH 300 mg/d and rifampin 450 mg/d for the continuation phase. The patient followed up at our family medicine outpatient clinic with slow improvement of her muscle weakness before returning to China once she was placed on the continuation phase drugs.

## THE TAKEAWAY

Suspect TB in high-risk patients traveling from endemic areas. Our patient, a Chinese woman visiting Brooklyn, New York, should've been considered high risk for TB even without her travel history from China because Brooklyn has a high rate of TB, as well. (In 2015, Sunset Park, Brooklyn had 18.2 cases of TB per 100,000 people, which was more than double the citywide rate.<sup>7</sup>)

TBM is a subacute disease with an often subtle presentation. Once you suspect TBM, isolate the patient, obtain appropriate cultures and smears, and start anti-TB drugs and adjunctive corticosteroids immediately, while the results of studies for AFB are still pending. Prompt diagnosis and treatment can save a patient's life. **JFP**

## References

1. Garcia-Monco JC. Central nervous system tuberculosis. *Neurol Clin.* 1999;17:737-759.
2. World Health Organization. Global tuberculosis report, 2016. Available at: <http://apps.who.int/iris/bitstream/10665/250441/1/9789241565394-eng.pdf?ua=1>. Accessed March 29, 2017.
3. Marx GE, Chan ED. Tuberculous meningitis: diagnosis and treatment overview. *Tuberc Res Treat.* 2011;2011:798764.
4. Siddiqui AH, Perl TM, Conlon M, et al. Preventing nosocomial transmission of pulmonary tuberculosis: when may isolation be discontinued for patients with suspected tuberculosis? *Infect Control Hosp Epidemiol.* 2002;23:141-144.
5. Tang YW, Meng S, Li H, et al. PCR enhances acid-fast bacillus stain-based rapid detection of *Mycobacterium tuberculosis*. *J Clin Microbiol.* 2004;42:1849-1850.
6. Long R, Gardam M. Tumour necrosis factor-alpha inhibitors and the reactivation of latent tuberculosis infection. *CMAJ.* 2003;168:1153-1156.
7. New York City Department of Health and Mental Hygiene. Tuberculosis in New York City, 2015. New York City Bureau of Tuberculosis Control Annual Summary. Available at: <http://www1.nyc.gov/assets/doh/downloads/pdf/tb/tb2015.pdf>. Accessed April 7, 2017.



## PHOTO ROUNDS FRIDAY

Each Friday, *The Journal of Family Practice* posts a new photo with a brief description and challenges you to make the diagnosis.

**Test your skills today!**

[jfponline.com](http://jfponline.com)