



## Persistent facial hyperpigmentation

The patient presented with persistent hyperpigmentation that was unaffected by regular face washing. A simple test both diagnosed and treated the condition.

A 59-YEAR-OLD WOMAN presented to a dermatology clinic with an asymptomatic brown facial hyperpigmentation that had developed several years earlier, and had persisted, despite regular face washing. Physicians who previously treated this patient interpreted this as melasma and advised her to wear sunscreen. The condition was not aggravated by sun exposure. The patient reported that she was otherwise healthy.

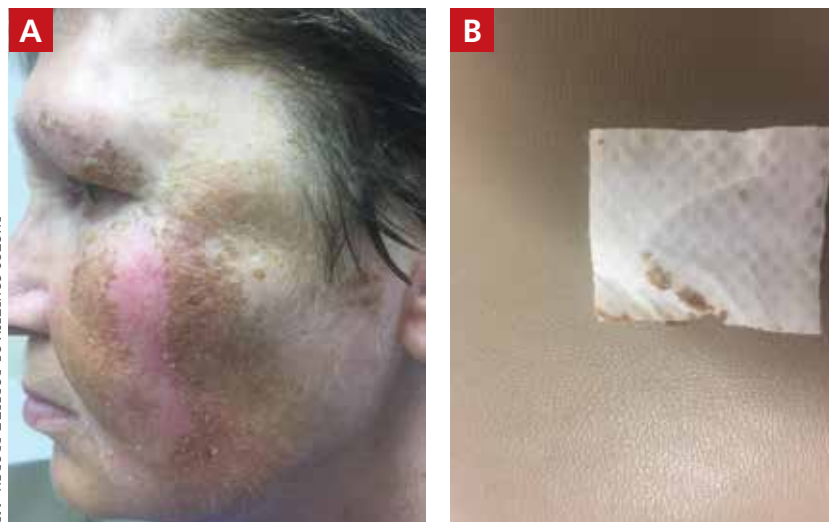
Physical examination revealed a brown

discoloration with a slightly rough texture. Upon rubbing the affected area with a 70% isopropyl alcohol pad, normal skin was revealed (FIGURE 1A) and brown flakes were apparent on the gauze (FIGURE 1B).

- WHAT IS YOUR DIAGNOSIS?
- HOW WOULD YOU TREAT THIS PATIENT?

FIGURE 1

“Alcohol wipe test” clinched the diagnosis



Rubbing the area with a 70% isopropyl alcohol pad revealed normal skin (A) and left brown flakes (B) on the gauze.

**Kandice C. Bailey, MS-2;**  
**Louis “Skip” Wise, MD;**  
**Tracy Breeden, RN;**  
**Robert T. Brodell, MD**  
University of Mississippi  
Medical School (Ms. Bailey),  
University of Mississippi  
Medical Center (Ms. Breeden),  
Departments of Dermatology  
and Pathology, University of  
Mississippi Medical Center  
(Dr. Brodell), Jackson, Miss;  
private practice, Fondren, Miss  
(Dr. Wise)

[rbrodell@umc.edu](mailto:rbrodell@umc.edu)

**DEPARTMENT EDITOR**

**Richard P. Usatine, MD**  
University of Texas Health  
at San Antonio

*Dr. Brodell discloses that he is a principal investigator for multicenter clinical trials for Galderma Laboratories, L.P., Novartis, and GlaxoSmithKline. He also serves on an advisory board for IntraDerm Pharmaceuticals. Ms. Bailey, Ms. Breeden, and Dr. Wise reported no potential conflict of interest relevant to this article.*

**Dx: Terra firma-forme dermatosis**

The physician diagnosed terra firma-forme dermatosis (TFFD) in this patient, noting the “dirty brown coloration” and distribution that did not suggest post-inflammatory hyperpigmentation or melasma. TFFD is a rare and benign form of acquired hyperpigmentation characterized by “velvety, pigmented patches or plaques.”<sup>1</sup> A simple bedside test, known as an “alcohol wipe test,” both confirms and treats TFFD; it involves rubbing the affected area with a 70% isopropyl alcohol pad.<sup>1</sup>

TFFD typically affects the face, neck, trunk, or ankles, but the scalp, axilla, back, and pubis also can be affected.<sup>1</sup> Histopathology will show negligible amounts of dermal inflammation, hyperkeratosis with mild acanthosis, and hyperkeratosis and papillomatosis.<sup>1</sup> Most patients diagnosed with TFFD report that the hyperpigmentation does not improve despite washing with soap and water.<sup>2</sup>

**Hygiene is not a factor**

In 2015, Greywal and Cohen followed the case presentations of 10 Caucasian patients with TFFD who presented with “brown and/or black plaques or papules or both.”<sup>2</sup> Many of the individuals followed in this case series reported “[practicing] good hygiene and showered a minimum of every other day or daily.”<sup>2</sup> The same was reported by the patient in this case. This suggests that TFFD is not a consequence of poor hygiene but perhaps a result of “sticky” sebum that produces a buildup of keratin debris, sebum, and bacteria on the skin.<sup>3</sup> This produces the hyperpigmentation seen clinically.

**Differential includes post-inflammatory hyperpigmentation**

Several other hyperpigmentation disorders were considered on the initial differential di-

agnosis for this case, including melasma and post-inflammatory hyperpigmentation. However, these 2 conditions are macular, whereas this hyperpigmented condition had a rough, mildly papular texture. Additionally, melasma flares up in the summer with UV exposure, and post-inflammatory hyperpigmentation presents with pruritus and/or a pre-existing rash.<sup>4</sup> This patient reported that the condition did not itch nor change with increased sunlight, thus making melasma and post-inflammatory hyperpigmentation unlikely diagnoses.

Acanthosis nigricans also was considered because it presents with a velvety brown pigmentation similar to what was seen with this patient. Acanthosis nigricans, however, primarily affects flexural areas, not the face, making it improbable.

■ **Our patient.** A “wipe test” was performed on the patient. This removed the brown flaky scaling and revealed the underlying normal skin. We instructed the patient to wash daily with a soapy wash cloth and scrub with 70% isopropyl alcohol should the hyperpigmentation recur. The patient did not return.

**JFP**

**CORRESPONDENCE**

Robert T. Brodell, MD, Department of Dermatology, University of Mississippi Medical Center, 2500 North State Street, Jackson, MS 39216; rbrodell@umc.edu

**References**

1. Lunge S, Supraja C. Terra firma-forme dermatosis—a dirty dermatosis: report of two cases. *Our Dermatol Online*. 2016;7:338-340.
2. Greywal T, Cohen PR. Terra firma-forme dermatosis: A report of ten individuals with Duncan’s dirty dermatosis and literature review. *Dermatol Pract Concept*. 2015;5:29-33.
3. Alonso-Usero V, Gavrilova M, et al. Dermatitis neglecta or terra firma-forme dermatosis. *Actas Dermosifiliogr*. 2012;103:932-934.
4. Lucas J, Brodell RT, Feldman SR. Dermatitis neglecta: a series of case reports and review of other dirty-appearing dermatoses. *Dermatol Online J*. 2006;12:5.

➤ TFFD is not a consequence of poor hygiene, but may be a result of “sticky” sebum that produces a buildup of keratin debris, sebum, and bacteria.

**WE WANT TO HEAR FROM YOU!**

Have a comment on an article, editorial, or department? You can send it by:

1. **E-MAIL:** [jfp.eic@gmail.com](mailto:jfp.eic@gmail.com)
2. **FAX:** 973-206-9251 or
3. **MAIL:** The Journal of Family Practice, 7 Century Drive, Suite 302, Parsippany, NJ 07054

LETTERS SHOULD BE 200 WORDS OR LESS. THEY WILL BE EDITED PRIOR TO PUBLICATION.

THE JOURNAL OF  
**FAMILY  
PRACTICE**